

*Full Length Research Paper*

# Severely inflamed Meckel's diverticulum in infancy mimicking acute appendicitis: A diagnostic conundrum

Uledi Sefu Juma<sup>1\*</sup> and Masumai Fauzia Ayubu<sup>2</sup>

<sup>1</sup>Surgery Department, Mzuzu Central Hospital, Mzuzu, Malawi.

<sup>2</sup>Department of Obstetrics and Gynaecology, Mzuzu Central Hospital, Mzuzu, Malawi.

Received 19 April, 2014; Accepted 16 June, 2014

**Meckel's diverticulum occurs around the fifth to seventh week of the embryological development. It originates when the vitelline or omphalomesenteric duct which normally connects the primitive gut to the yolk sac fails to obliterate. Meckel's diverticulum may be symptomatic or remain silent throughout life time and incidentally discovered at autopsy. Symptoms primarily emanates from an array of complications which may include diverticulitis, haemorrhage, obstruction and intussusceptions. Diverticulitis predominately affects adults and remains exceedingly rare in infancy. However, Meckel's diverticulitis clinical symptoms are non-specific and frequently resemble other common acute surgical and inflammatory conditions of the abdomen. The infrequency and varied symptomatology make clear-cut pre-operative diagnosis of diverticulitis extremely challenging. We hereby, report a case of a six month old infant with acute diverticulitis who present with brief history of vomiting, abdominal distension and fever. Basically, our report is aimed at forewarning clinicians to consider meckel's diverticulitis as a differential diagnosis when assessing children who present with acute abdominal pathologies.**

**Key words:** Meckel's diverticulum, diverticulitis, acute appendicitis, infants, children, asymptomatic diverticulum, symptomatic diverticulum, diagnosis, surgical resection.

## INTRODUCTION

Meckel's diverticulum essentially refers to an embryological remnant that is attributable to the failure of the omphalomesenteric duct to obliterate during the fifth to seventh week of fetal development (Seth and Seth, 2011).

Its embryological origin was initially described in fair details by the German anatomist Johann Friedrich Meckel about two hundred years ago, bolstering the earlier account of this congenital anatomic variant by Fabricius Hildanus, Levator and Ruysch between the 16 and 17th centuries (Seth and Seth, 2011; Malik et al.,

2010; Mohiuddin et al., 2011; Sagar et al., 2006). Meckel's diverticulum is a true intestinal diverticulum possessing all three coats of the intestinal wall with its separate blood supply from the vitelline artery. Having its own blood supply renders it susceptible to obstruction and infection (Seth and Seth, 2011; Malik et al., 2010; Mohiuddin et al., 2011; Sagar et al., 2006).

Meckel's diverticulum is invariably situated at the antimesenteric border of the distal ileum about 50 to 100 cm proximal to ileocecal valve (Seth and Seth, 2011; Malik et al., 2010; Mohiuddin et al., 2011; Sagar et al.,

\*Corresponding author. E-mail: uledi68@hotmail.com. Tel: (+265)999654403. Fax: +265 131 2123.

Author(s) agree that this article remain permanently open access under the terms of the [Creative Commons Attribution License 4.0 International License](http://creativecommons.org/licenses/by/4.0/)

2006; Coulier et al., 2003). Presence of the diverticulum up to 180 cm from the ileocaecal valve has been reported (Madhyastha et al., 2007). Meckel's diverticulum is estimated to occur in two percent of the general population and this makes it the most common congenital anomaly of the gastrointestinal tract (Seth and Seth, 2011; Malik et al., 2010; Mohiuddin et al., 2011; Sagar et al., 2006; Coulier et al., 2003; Madhyastha et al., 2007).

Typically Meckel's diverticulum remains asymptomatic and incidentally encountered during surgery, laparoscopic examination, small bowel contrast examination or at autopsy (Malik et al., 2010; Sagar et al., 2006). About fifty percent of Meckel's diverticulum contains ectopic or heterotopic tissues, commonest being gastric mucosa or pancreatic tissue which makes it more predisposed to complications (Seth and Seth, 2011; Malik et al., 2010; Mohiuddin et al., 2011; Sagar et al., 2006; Coulier et al., 2003; Madhyastha et al., 2007; Robijn et al., 2007). A variety of Meckel's diverticulum adverse outcomes have been reported in pediatric population, these include gastrointestinal haemorrhage, intestinal obstruction, intussusceptions and diverticulitis (Sagar et al., 2006; Dumper et al., 2006; Zahraa et al., 2003).

However, occurrence of diverticulitis in infancy remains a very rare clinical presentation and indeed poses a diagnostic dilemma (Seth and Seth, 2011; Malik et al., 2010; Mohiuddin et al., 2011; Sagar et al., 2006; Coulier et al., 2003; Madhyastha et al., 2007; Robijn et al., 2007; Dumper et al., 2006; Zahraa et al., 2003). Manifestation of Meckel's diverticulitis in infancy is highly likely to mimic other common acute surgical and inflammatory conditions of the abdomen (Sagar et al., 2006; Dumper et al., 2006; Zahraa et al., 2003).

This may lead to diagnostic and management delays. We herein, report a case of a six month old infant with acute diverticulitis. Our report is primarily intended to serve as a cautionary supplication to clinicians in our setting to consider Meckel's diverticulitis as a differential diagnosis when evaluating children who present with undifferentiated acute abdominal pain.

## CASE REPORT

Previously healthy six month old male infant weighing 7.6 kg was brought to our emergency department by his mother with short history of persistent vomiting, abdominal distension and fever for about seven hours duration. Mother reports that the baby was relatively well until about seven hours prior to admission when he started vomiting. It was non-projectile bilious vomiting, vomitus mainly consisted of watery yellowish fluid moderately bile stained and odorless.

The baby is reported to have vomited seven times prior to admission. There was no concomitant history of haematemesis, passing mucus or melena stools. During the same span of time the baby developed abdominal

distension and high grade fever punctuated with spells of rigors.

Associated with the aforementioned symptoms mother reports that the baby became irritable, cried excessively and was refusing to be breast fed. However, there was no history of twitching or convulsions and mother gave no history of trauma preceding the onset of symptoms.

Furthermore, mother reports to have attended antenatal clinic on regular basis during her pregnancy; her entire antenatal course was uneventful and the baby was born at the hospital setting; and mode of delivery was spontaneous vaginal delivery. Since birth, the baby has had excellent developmental milestones and by then he had received all the required vaccinations.

On examination, major findings were on the abdominal examination; however, on general examination we saw a baby boy, in good nutritional status, but ill looking, lethargic, irritable, crying excessively, febrile (38.7°C), moderately dehydrated, not pale and not jaundiced. He had a pulse rate of 132 beats per minute, regular with good volume; his blood pressure was 90/60 mmHg.

Per abdomen examination revealed moderately and uniformly distended abdomen which was not moving with respiration. The abdomen was rather rigid with marked tenderness on the right iliac fossa. There was noticeably rebound tenderness on the same site.

However, there was no obvious palpable mass or organomegaly. Tympanic note was elicited on percussion. Bowel sounds were significantly diminished. Digital rectal examination revealed normal findings with normal coloured stool on the glove.

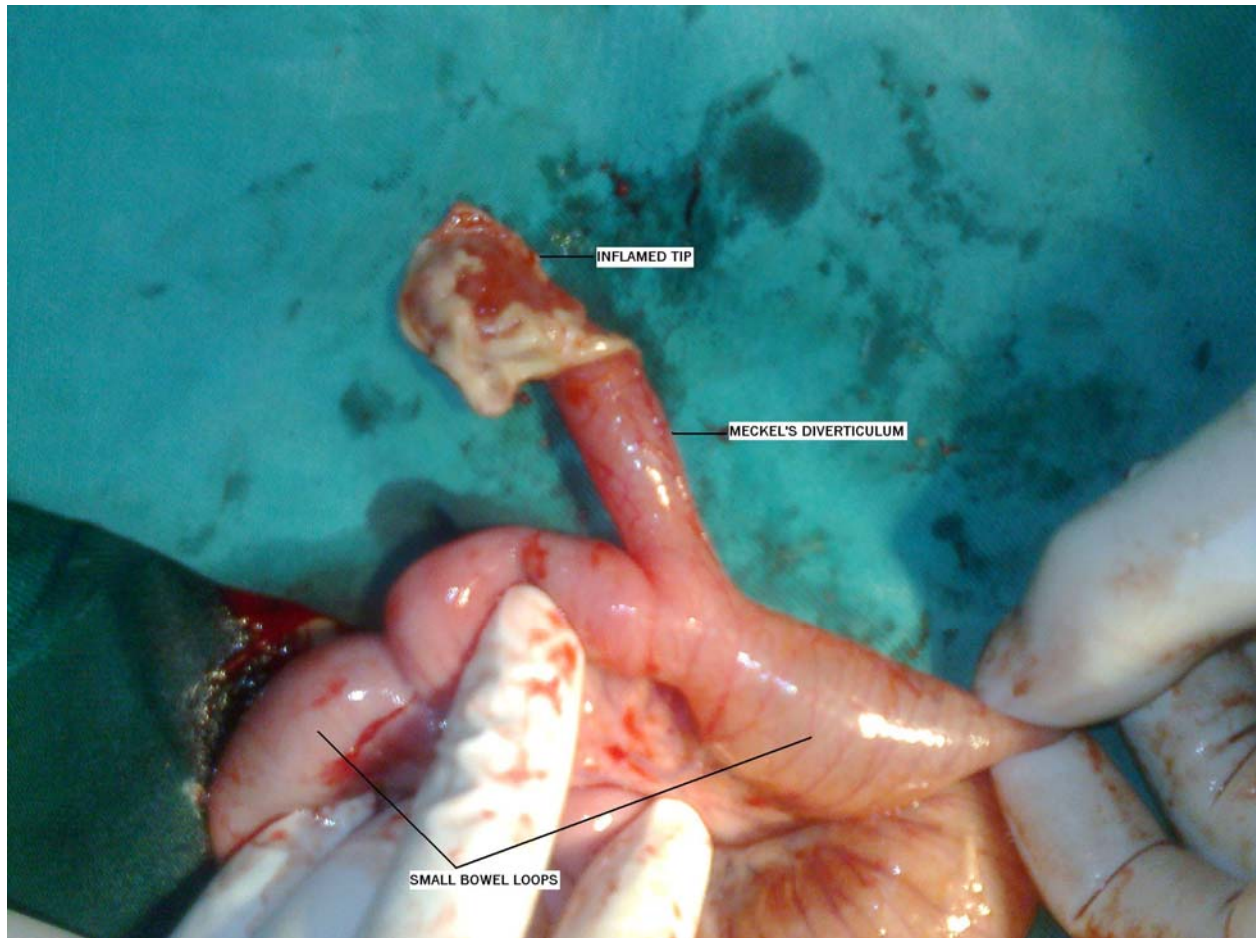
On respiratory system, the baby had mildly grunting respirations; however, he had no inter-costal or sub-costal recessions, and was not cyanotic. He had respiratory rate of 27 breaths/min. Chest was symmetrical, moving with respiration. He had normal breath sounds bilaterally with minimal transmitted sounds. The rest of systemic examination had nil of note.

Work-up of the patient comprised of radiological, biochemical and hematological profiles. The baby had complete blood count (CBC), serum electrolytes, malaria rapid diagnostic test (MRDT), blood grouping and cross matching, abdominal ultrasonography, as well as plain abdominal X-rays done. CBC revealed significant leukocytosis, whereas serum electrolytes showed mild hypokalemia. MRDT was negative.

Plain abdominal radiograph showed paucity of gas within the bowels, but there was no clear evidence of intestinal obstruction, pneumoperitoneum or pneumatosis intestinalis. Abdominal ultrasonography showed moderate amount of fluid in the right lower abdominal quadrant with dilated loops of small intestine.

Therefore in view of the history, physical examination and investigations, a diagnosis of peritonitis secondary to acute appendicitis was made.

Cognizant of rapidly deteriorating clinical signs and peritoneal irritation, the baby was urgently resuscitated



**Figure 1.** Intra-operative view shows very long Meckel's diverticulum on the antimesenteric border of the ileum with severely inflamed oedematous tip.

and informed written consent obtained from the mother. There after the baby was taken to the operating room for emergency surgery. Laparotomy was performed, through an infra-umbilical transverse incision which revealed moderately distended small bowel loops matted together and soiled with pus debris, there was significant presence of pus-stained peritoneal fluid collections in the pelvic cavity. After brief meticulous search, a long severely inflamed out-pouching structure arising from the antimesenteric border of the lower ileum was noted as a locus of infection. This was unquestionably an acutely inflamed Meckel's diverticulum situated about 47 cm proximal to ileocaecal valve.

It had a swollen oedematous tip with clear signs of severe inflammation. There was no discernible mass at the base of the diverticulum. The diverticulum was about 11 cm long, and had a caliber of about 2.3 cm (Figure 1). Of note was a very normal looking para-caecal appendix.

Macroscopically, other contiguous peritoneal viscera appeared normal. Thus, a short segment of ileum containing the diverticulum was resected in a wedge fashion and double layered end-to-end anastomosis was

successfully done. Patient had smooth postoperative recovery and was discharged home five days later.

Our intra operative findings were avowed by histopathology examination results which revealed features consistent with inflamed Meckel's diverticulum. However, there was no evidence of abnormal mucosa or underlying malignancy. Follow-up visit one year after surgery the baby was found to be in excellent condition.

## DISCUSSION

Meckel's diverticulum may remain asymptomatic throughout life time and incidentally discovered at autopsy. Meckel's diverticulum symptomatology principally arises from complications (Malik et al., 2010; Sagar et al., 2006; Robijn et al., 2007; Dumper et al., 2006). An inventory of potential complications that could arise from Meckel's diverticulum is long and heterogeneous.

These include perforation, haemorrhage, obstruction; intussusceptions, diverticulitis, axial torsion; foreign bodies' impactions and occurrence of neoplasm in the

diverticulum just to mention a few (Malik et al., 2010; Sagar et al., 2006; Robijn et al., 2007; Dumper et al., 2006; Zahraa et al., 2003).

Lifetime risk of complications from Meckel's diverticulum is projected to be at four percent by most series (Malik et al., 2010; Sagar et al., 2006; Robijn et al., 2007; Dumper et al., 2006; Zahraa et al., 2003). The most commonly encountered complication of Meckel's diverticulum in pediatric population is gastrointestinal haemorrhage which is highly ascribable to the presence of ectopic gastric or pancreatic mucosa. Occurrence of diverticulitis in infancy such as in our report remains rather a rare clinical manifestation (Malik et al., 2010; Sagar et al., 2006; Robijn et al., 2007; Dumper et al., 2006; Zahraa et al., 2003).

Contrary to many other acute abdominal conditions whereby detailed history, physical examination coupled with appropriate investigations often lead to correct diagnosis. Meckel's diverticulitis clinical symptoms are non-specific, wide-ranging and largely mirror a number of common acute surgical and inflammatory conditions of the abdomen such as acute appendicitis, peptic ulcer disease or biliary colic (Malik et al., 2010; Sagar et al., 2006; Robijn et al., 2007; Karatepe et al., 2009).

The rarity and varied symptomatology very often poses a diagnostic quandary. Accurate preoperative diagnosis of symptomatic Meckel's diverticulum is quite rare. In clinical practice the final diagnosis is mostly made at surgery (Malik et al., 2010; Sagar et al., 2006; Robijn et al., 2007; Karatepe et al., 2009).

Choice of investigations for Meckel's diverticulum largely depends upon patient's presentation and clinician adequate knowledge of its anatomical and pathophysiological dynamics. Frequently, a panel of investigations may be employed. Apart from biochemical and hematological work-up, various imaging techniques come into play. These ranges from plain abdominal X-rays, barium studies, arteriography, computed tomography (CT) scan, radionuclide scintigraphy and ultrasonography (Malik et al., 2010; Sagar et al., 2006; Coulier et al., 2003; Mittal et al., 2008; Lee et al., 2009).

Generally, plain abdominal X-rays have limited role in the diagnosis of Meckel's diverticulum; however, plain radiograph can demonstrate features of small bowel obstruction or pneumoperitoneum in case of perforation. Presence of gas-filled viscus in the right iliac fossa or central abdomen may grant inkling to diagnosis (Malik et al., 2010; Mohiuddin et al., 2011; Sagar et al., 2006; Coulier et al., 2003).

To some extent good quality barium studies may be useful in detection of Meckel's diverticulum; usually a diverticulum is visualized as a tubular structure arising from the anti-mesenteric border of the distal ileum. However, enteroclysis has a relatively low yield and beset by limitations in emergency setting (Malik et al., 2010; Mohiuddin et al., 2011; Sagar et al., 2006; Coulier et al., 2003). Under experienced and skilled operator, ultraso-

nography is extremely handy non-invasive diagnostic tool for patients with suspected diverticulum (Malik et al., 2010; Sagar et al., 2006; Coulier et al., 2003).

Sonographic findings of an inflamed Meckel's diverticulum may grossly mimic features of acute appendicitis or gastrointestinal duplication. Presence of a tubular hyper echoic structure on sonography may be indicative of Meckel's diverticulum (Malik et al., 2010; Mohiuddin et al., 2011; Sagar et al., 2006; Coulier et al., 2003).

CT scan depicts an inflamed Meckel's diverticulum as a blind-ending pouch of variable size with mural thickening and surrounding mesenteric inflammation which is attached to the distal ileum rather than the caecum. Where applicable, use of contrast-enhanced CT may be employed (Malik et al., 2010; Sagar et al., 2006; Coulier et al., 2003). Akin to ultrasonography, CT scan is also able to rule out other potentially pathological conditions.

In pediatric age group, Technetium-99m ( $^{99m}\text{Tc}$ ) pertechnetate scintigraphy also referred to as Meckel's diverticulum scan is one of the most useful non-invasive diagnostic methods for the diagnosis of Meckel's diverticulum with heterotopic gastric mucosa.

The isotope has a very high predilection to concentrate in ectopic gastric mucosa. Meckel's diverticulum scan has a diagnostic sensitivity of about 85%, specificity of 95% and accuracy of about 90%. However, Meckel's scan is less accurate in adult population due to diminution of ectopic gastric mucosa within the diverticulum. Occasionally, Technetium-99m ( $^{99m}\text{Tc}$ ) pertechnetate scan may be enhanced or augmented by the use of pharmacological agents such as pentagastrin, somatostatin or  $\text{H}_2$  receptor blockers which tend to intensify isotope uptake by the gastric mucosa (Malik et al., 2010; Sagar et al., 2006; Mittal et al., 2008; Karatepe et al., 2009).

Angiography is another valuable investigation that may be employed in the assessment of an adult patient with suspected bleeding from Meckel's diverticulum. The technique is effective in pinpointing the exact site of bleeding and occasionally used for therapeutic preoperative embolization (Malik et al., 2010; Sagar et al., 2006; Lee et al., 2009).

In the advent of minimally invasive surgery, use of laparoscopy in patients with enigmatic presentations is preferred. Laparoscopy could be suitably utilized for both diagnostic and therapeutic purposes (Malik et al., 2010; Sagar et al., 2006; Robijn et al., 2007; Dumper et al., 2006; Zahraa et al., 2003; Lee et al., 2009).

Treatment of complicated or symptomatic Meckel's diverticulum has always been exclusively surgical resection either by conventional approach, that is, open surgery or through contemporary minimally invasive techniques. Usually resection span from simple diverticulectomy to segmental ileal resection.

Principally, resection is aimed at removal of Meckel's diverticulum, all ectopic gastric mucosa, or any ulcerated

adjacent ileal mucosa (Seth and Seth, 2011; Malik et al., 2010; Sagar et al., 2006; Robijn et al., 2006).

For instance, when the diverticulum base is fairly narrow then simple transverse diverticulectomy may suffice, whereas in short broad based diverticulum with ectopic gastric mucosa, inflammation, edema formation, ischaemic process, perforation, ulceration or haemorrhage, segmental ileal resection bearing the diverticulum followed by end to end anastomosis is warranted. Wide intestinal resection together with the affected mesentery lymphatics is recommended in case of suspected tumor involvement (Malik et al., 2010; Sagar et al., 2006; Robijn et al., 2006; Karatepe et al., 2009). Where feasible, certainly is a good practice to carry out histopathology examination for all resected diverticulum specimens.

Management of asymptomatic or incidentally found Meckel's diverticulum at laparotomy presents a distinctive and an outstanding challenge. Hitherto, asymptomatic or incidentally found Meckel's diverticulum treatment is shrouded in protracted controversy. The central theme being varied opinions from literature on management approaches towards the incidentally found Meckel's diverticulum; some authors recommend diverticulectomy in all encountered cases, others advise prophylactic resection only in the presence of risk factors, whereas the rest suggest that incidentally found Meckel's diverticulum should not be operated at all (Malik et al., 2010; Sagar et al., 2006; Robijn et al., 2006).

By far there is no universally agreeable treatment protocol with regard to asymptomatic or incidentally found Meckel's diverticulum. Indubitably, there is great need for a prospective large-scale multi-center randomized control clinical trial which might cast more light on this long standing contentious subject.

## Conclusion

Diverticulitis is one of the most common complications of Meckel's diverticulum, but remains rather rare in pediatric age group. The infrequency and diversity of its symptoms makes a precise pre-operative diagnosis of diverticulitis extremely challenging. Diagnostic stalemate may lead to interventional delays and subsequently life-threatening complications. Thus, sufficient knowledge of its pathophysiological dynamics, high index of suspicion and swift surgical intervention are of paramount importance in preventing morbidity and mortality associated with complications of this disease entity.

## Conflict of Interest

Authors declare no conflict of interest.

## REFERENCES

- Coulier B, Sergeant L, Maldague P, Ramboux A, Broze B, Hamels J (2003). Complicated meckel's diverticulum diagnosed preoperatively in three cases by complementing CT with detailed US studies. *JBR-BTR*.86: 65-71.
- Dumper J, Mackenzie S, Mitchell P, Sutherland F, Quan ML, Mew D (2006). Complications of Meckel's diverticula in adults. *Can. J Surg.* 49(5):353-357.
- Karatepe O, Adas G, Altok M, Ozcan D, Kamali S, Karahan S (2009). Meckel's diverticulum manifested by a subcutaneous abscess. *World J. Gastroenterol.* 15(48):6123-6125.
- Lee JS, Moon W, Park SJ, Park MI, Kim KJ, Lee SH, Chang HK, Jung GS (2009). Hemorrhagic Meckel's diverticulum in an older woman diagnosed by repeated angiographies. *Turk. J. Gastroenterol.* 20(4):282-286.
- Madhyastha S, Prabhu LV, Prakash SV (2007). Meckel's Diverticulum. A Case Report. *Int. J. Morphol.* 25(3):519-522.
- Malik AA, Shams-ul-Bari, Wani KA, Khaja AR (2010). Meckel's diverticulum-Revisited. *The Saudi J. Gastroenterol.* 16(1):3-7.
- Mittal BR, Kashyap R, Bhattacharya A, Singh B, Radotra BD, Narasimha Rao KL (2008). Meckel's diverticulum in infants and children; technetium-99m pertechnetatescintigraphy and clinical findings. *Hell J. Nucl. Med.* 11(1):26-29
- Mohiuddin SS, Gonzalez A, Corpron C (2011). Meckel's Diverticulum with Small Bowel Obstruction Presenting as Appendicitis in a Pediatric Patient. *JSLs*.15:558-561.
- Robijn J, Sebrecchts E, Miserez M (2006). Management of Incidentally Found Meckel's Diverticulum A New Approach: Resection Based on a Risk Score. *Act. Chir Belg.* 106(4):467-70.
- Sagar J, Kumar V, Shah DK (2006). Meckel's diverticulum: a systematic review. *J. R. Soc. Med.* 99:501-505.
- Seth A, Seth J (2011). Axial torsion as a rare and unusual complication of a Meckel's diverticulum: a case report and review of the literature. *J. Med. Case Rep.* 5:118.
- Zahraa J, Abu-Ekteish F, Al Bassam AR, Nosir AA (2003). Perforated Meckel's Diverticulum in a Neonate Mimicking Necrotizing Enterocolitis. *Pediatr. Emerg. Care* 19(6):418-9.