

# An Unusual External Genital Lesion and its Treatment- A Case Report

ADITHYA V NARAGUND<sup>1</sup>, ND DEEVISH<sup>2</sup>, ROHITH MUDDASETTY<sup>3</sup>, SHARATH S KUMAR<sup>4</sup>

CC BY-NC-ND

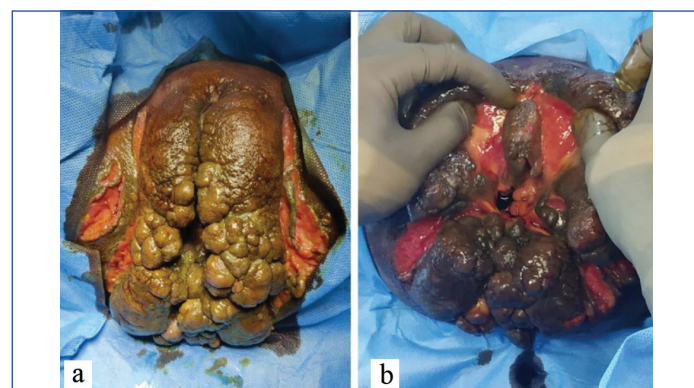
## ABSTRACT

Lesions around the external genitalia are embarrassing, physically, socially, and emotionally depressing. Patients generally present late for treatment. Here, the authors describe a case of 32 years old female patient, who presented with multiple giant warts-like lesions involving the external genitalia since past 6 months. Any presence of pain, bleeding from the lesion, or alteration in bowel, bladder, or menstrual habits were denied. Lesion posed diagnostic and therapeutic challenges. She underwent resection of the lesion with reconstruction using a bilateral gluteal fasciocutaneous flap and split skin graft with diversion sigmoid colostomy. She further developed anal stricture and subcutaneous fistula, requiring anal dilatation and seton placement. After a brief period of Keigels's exercises and anal dilatation, she underwent a reversal of sigmoid colostomy. The patient had to undergo staged surgeries to restore near normal external genitalia. This case is an unusual presentation of a genital lesion which was treated with a multidisciplinary team approach to restore her anatomy.

## CASE REPORT

A 32-year-old female presented with cauliflower-like growth in the perineum since past six months which gradually increased in the size. She had no history of pain, fever, burning micturition, alteration in stool habits, or menstrual cycles. No history of bleeding on touch, and no swelling was noted in the groin region. She had oral cavity features like angular stomatitis and geographic tongue suggestive of vitamin deficiencies. She had no other co-morbidities, addictive habits, or high-risk behaviour.

She had consulted multiple hospitals where she had undergone investigations in form of biopsy with the suspicion of *Mycobacterium tuberculosis* infection. On presentation, basic blood investigations were performed in the form of complete blood counts, and renal and liver function tests which showed only microcytic hypochromic anaemia. Her Erythrocyte Sedimentation Rate (ESR) was within normal limits. She was treated with iron and vitamin supplements to correct the nutritional deficiency. She was negative for retro-viral serology. Differential diagnoses of tuberculosis, giant perineal warts, and genital filariasis were considered. An examination under anaesthesia was performed, that showed the lesion was involving only the stratified keratinous squamous epithelium and sparing the mucosa of the anal canal and vagina [Table/Fig-1]. A good amount of tissue was taken for histopathological examination which showed non caseating granulomas.

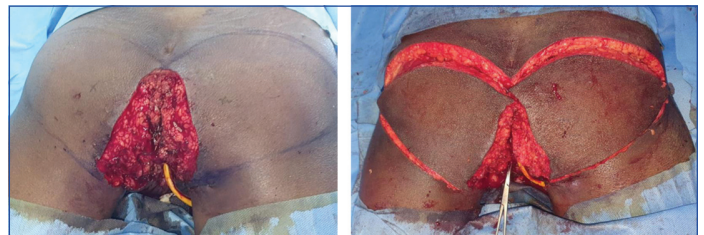


[Table/Fig-1]: a,b) Showing the lesion in external genitalia.

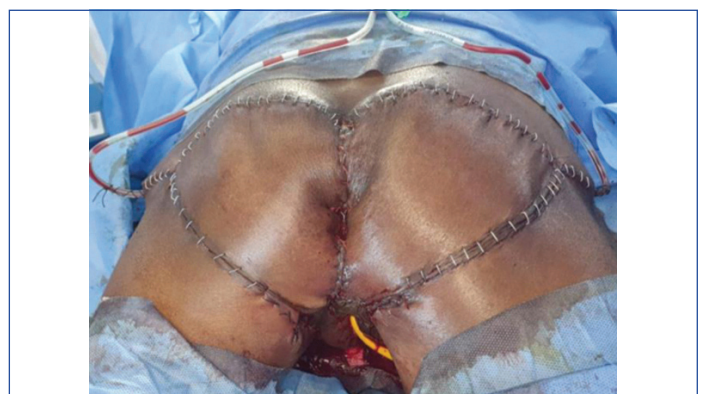Resection of the lesion and reconstruction with gluteal flap was done. The lesion was resected in total from the anal verge

**Keywords:** Anal stricture, Giant wart, Seton, Sigmoid colostomy

including part of labia majora [Table/Fig-2]. Reconstruction was done by mobilising bilateral gluteal fasciocutaneous flap in form of V-Y plasty and split skin graft for a raw area in the region of perineal body [Table/Fig-3,4]. Covering loop sigmoid colostomy was done to safeguard the flap from contamination. A part of the split skin graft was not taken, which later healed by secondary intention.



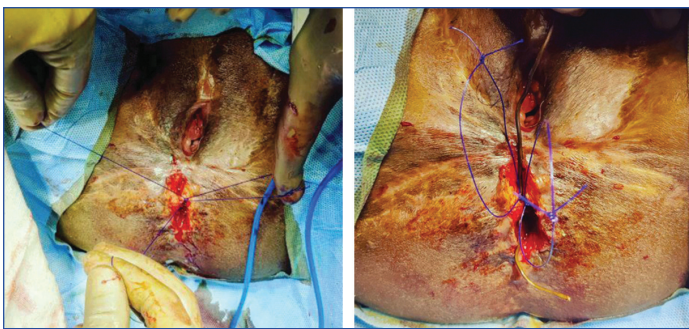
[Table/Fig-2]: Resection of the lesion with Foley's catheter placed in the urethra.  
[Table/Fig-3]: Bilateral gluteal fasciocutaneous flaps prepared.  
(Images from left to right).



[Table/Fig-4]: Reconstruction with flaps and split skin graft.

After three months, flaps had healed well except for anal stricture and a small subcutaneous sinus in the perianal area. Under anaesthesia, she had anal dilatation, and a cutting seton was placed for the sinus tract [Table/Fig-5,6]. The dilatation was continued using plastic anal dilators for another six weeks.

Once adequate anal canal opening was confirmed, she was evaluated for sphincter integrity in the form of clinical anal canal examination and saline holding test. She underwent colostomy



**[Table/Fig-5]:** Perianal sinus tract and anal stricture.  
**[Table/Fig-6]:** Seton placed for the sinus. (Images from left to right).

reversal. At present she is passing stools via naturalis with good continence to flatus, liquid, and solid stools.

## DISCUSSION

Skin lesions over the external genitalia are not uncommon. They can be confined to genital skin or as a manifestation of systemic disease. These lesions can be classified as infectious, inflammatory, or neoplastic [1]. These disorders may be accompanied by severe bodily symptoms and emotional discomfort. Most of these patients show up at the hospital late for treatment because of embarrassment. Lesions around the genitalia need work-up for sexually transmitted diseases. Human Papillomavirus (HPV) is one of the most common aetiologies in lesion around the genitalia. An immunocompromised state is another risk factor involved in these individuals [2]. Filariasis of external genitalia is an entity seen in tropical countries [3]. Most of these lesions can be treated with drugs as they tend to be related to infectious aetiology.

HPV can cause giant warts resembling our patient presentation, however, the absence of microscopic features like enlarged nuclei, higher nuclear/cytoplasmic ratio, and acanthosis rules out HPV infection [2,4]. Genital filariasis is an uncommon lesion that can present with the thickening of the skin, diagnosis of which depends on the demonstration of microfilaria in the peripheral blood samples [5]. Smear examination may demonstrate worms of *Wucheria bancrofti* [3]. Cutaneous tuberculosis involving genital area is also a common entity especially in a tropical country. The lesions described classically is different from what was seen in the present case [6]. Presence of non caseating granulomas rules out tuberculosis in the index case.

Apart from the diagnosis, the challenge was to correct the deformity cosmetically by restoring the external genitalia. Fortunately, the lesion was limited to the skin without involving the mucosal or muscular layers. The authors could preserve a part of labia majora on both the sides anteriorly. Bilateral gluteal fasciocutaneous flaps covered the raw area around the anal canal. A part of raw area in the region of

perineal body and around vagina required split skin graft. The area covered by skin graft required regular dressings for 30 days.

Algeri P et al., have reported an unusual painful lesion in the left labia minora which was excised, diagnosed to be a syringoma of sweat glands [7]. Sinha A et al., have described multiple wart like lesions involving vulva of 60-year-old female which was excised, found to be lymphangioma circumscriptum on pathological examination [8]. Sadati MS et al., have described multiple punched out ulcers in the vulva in a 28-year-old female, turned out to be Langerhans cell histiocytosis which was treated with Thalidomide [9]. Gutierrez P et al., have described a hypopigmented area around the vulva which was post-inflammatory hypopigmentation treated successfully with topical steroids [10]. The present case differs from these reports in many ways like- absence of pain, absence of ulcers, proliferative wart like lesions, no changes in the pigmentation. Finally, presence of non caseating granulomas distinguishes the present patient from above mention reports.

After series of dressings, procedures, and anal dilatations she is passing stools via naturalis with good continence. The cosmetic outcome achieved can be considered excellent. The patient is under regular follow-up since a year with no features of recurrence. This case was presented as a diagnostic and therapeutic challenge.

## CONCLUSION(S)

Large benign genital lesions are mutilating to the patients. Thorough evaluation is needed to diagnose the cause. Surgeries to restore cosmesis is challenging owing to complex anatomical architecture.

## REFERENCES

- [1] Yura E, Flury S. Cutaneous lesions of the external genitalia. *Med Clin North Am.* 2018;102(2):279-300.
- [2] Lilungulu A, Mpondo BCT, Mlwati A, Matovelo D, Kihunrwa A, Gumodoka B. Giant Condyloma acuminatum of vulva in an HIV-infected woman. *Case Rep Infect Dis.* 2017;2017:5161783.
- [3] Ghimire P, Ghimire PG. Genital filariasis presenting as a vaginal wall cystic lesion. *IDCases.* 2019;19:e00670.
- [4] Venter F, Heidari A, Viehweg M, Rivera M, Natarajan P, Cobos E. Giant condylomata acuminata of buschke-lowenstein associated with paraneoplastic hypercalcemia. *J Investig Med High Impact Case Rep.* 2018;6:2324709618758348.
- [5] Richens J. Genital manifestations of tropical diseases. *Sex Transm Infect.* 2004;80(1):12-17.
- [6] dos Santos JB, Figueiredo AR, Ferraz CE, de Oliveira MH, da Silva PG, de Medeiros VLS. Cutaneous tuberculosis: epidemiologic, etiopathogenic and clinical aspects-Part I. *An Bras Dermatol.* 2014;89(2):219-29.
- [7] Algeri P, Rodella R, Manfredini C, Algeri M. An unusual case of genital lesion: a vulvar syringoma. *J Fam Reprod Health.* 2021;15(1):70-73.
- [8] Sinha A, Phukan JP, Jalan S, Pal S. Lymphangioma circumscriptum of the vulva: Report of a rare case. *J-Life Health.* 2015;6(2):91-93.
- [9] Sadati MS, Todorbar N, Sari Aslani F, Hadibarhaghtalab M. Isolated langerhans cell histiocytosis of the vulva in a 28-year-old lady: a report of a case and brief review of the literature. *Case Rep Dermatol Med.* 2022;2022:8483008.
- [10] Gutierrez P, Gandhi K, Amakiri N, Garza J, Ventolini G. Vulvar lesion mimicking vitiligo: A case report. *Case Rep Womens Health.* 2020;27:e00234.

### PARTICULARS OF CONTRIBUTORS:

1. Consultant, Department of Surgical Gastroenterology and Hepatopancreatobiliary Surgery, Prakriya Hospitals, Bengaluru, Karnataka, India.
2. Consultant, Department of Plastic and Reconstructive Surgery, Prakriya Hospitals, Bengaluru, Karnataka, India.
3. Consultant, Department of Surgical Gastroenterology and Hepatopancreatobiliary Surgery, Prakriya Hospitals, Bengaluru, Karnataka, India.
4. Registrar, Department of Surgical Gastroenterology and Hepatopancreatobiliary Surgery, Prakriya Hospitals, Bengaluru, Karnataka, India.

### NAME, ADDRESS, E-MAIL ID OF THE CORRESPONDING AUTHOR:

Rohith Muddasetty,  
 S-811, 7<sup>th</sup> Main Road, 2<sup>nd</sup> Stage Bharath Nagar Opp.  
 Karnataka Bank, Bengaluru, Karnataka, India.  
 E-mail: rohith.m.setty@gmail.com

### PLAGIARISM CHECKING METHODS: [Jain H et al.]

- Plagiarism X-checker: Oct 26, 2022
- Manual Googling: Mar 15, 2023
- iThenticate Software: Apr 12, 2023 (7%)

### ETYMOLOGY: Author Origin

### AUTHOR DECLARATION:

- Financial or Other Competing Interests: None
- Was informed consent obtained from the subjects involved in the study? Yes
- For any images presented appropriate consent has been obtained from the subjects. Yes

Date of Submission: **Oct 21, 2022**  
 Date of Peer Review: **Feb 24, 2023**  
 Date of Acceptance: **Mar 16, 2023**  
 Date of Publishing: **May 01, 2023**