

Association of Oral Squamous Cell Carcinoma and Human Papilloma Virus Status in Chronic Periodontitis Patients: A Cross-sectional Study

SHIKHA SHARMA¹, SHOBHA PRAKASH²

ABSTRACT

Introduction: Apart from the alcohol and tobacco which are considered as an important cause for carcinogenesis, periodontal infections have also been considered equally important cause for it. Infections are increasingly considered as potential trigger for carcinogenesis apart from alcohol and tobacco. The role of the Human Papilloma Virus (HPV) in causing Oral Squamous Cell Carcinoma (OSCC), highlights the significance of the oral infections in the development of the OSCC.

Aim: To detect the relationship between Chronic Periodontitis, HPV, and OSCC.

Materials and Methods: This was a cross-sectional study conducted on 15 chronic generalised periodontitis patients with OSCC affecting alveoli and gingiva, selected from the Department of Oral and Maxillofacial Surgery, College of Dental Sciences, Davangere, Karnataka, India, conducted from September 2015 to October 2017. DNA was extracted from the biopsy of the tissue sample for the detection of HPV by Polymerase chain reaction (PCR). The parameters assessed were the Clinical

Attachment Loss (CAL), Tumour Node Metastasis (TNM) staging of OSCC, HPV status and the presence of the periodontal marker bacteria. Chi-square test and Spearman's correlation were used to find association and correlation between the parameters.

Results: A total of 15 cases of chronic generalised periodontitis patients with oral squamous cell carcinoma were included in the study (seven males and eight female patients, with a mean age of 50.8 years). Of these, HPV was found in four patients only. On comparison between Chronic Generalised Periodontitis (CGP) and OSCC, a non significant association and a negative correlation was found. Similar analysis was observed between CGP and HPV. When comparison was done between HPV and OSCC, non significant association (p -value=0.774) and a negative correlation (r -value=-0.169) was found.

Conclusion: The present study did not yield a significant association and correlation between these three parameters. Further prospective studies should be conducted, which may help in the prevention of periodontitis and subsequently, decreasing the incidences of OSCC.

Keywords: Chronic inflammation, Infections, Oropharyngeal carcinomas, Periodontal pockets, Polymerase chain reaction

INTRODUCTION

The most widely diagnosed oral malignancy is OSCC, accounting for about 90% of the number, results in a significant damage and cancer related death each year. The most commonly found risk factors for the development of the OSCC includes, tobacco chewing, alcohol, betel quid ingestion, malnutrition as well as viral infection [1]. A relationship between the HPV and oropharyngeal carcinoma has been established [2]. Through the activation of the mitogen activated pathway and cyclin D1, there occurs cell proliferations and Deoxyribonucleic Acid (DNA) replication, which leads to an increased incidences in the cell transformation and genetic mutations leading to the tumour development [3]. These patients are typically caucasians, non smokers non drinkers, and a group of younger patients than those diagnosed as, HPV negative carcinoma group [4].

Periodontitis, which is a chronic oral infection involving an inflammatory reactions of the gram negative anaerobic bacteria in the dental plaque. The main effect of the periodontitis includes an irreversible alveolar bone loss around the teeth clinically detected as the Alveolar Bone Loss (ABL) [4]. In chronic inflammation, the affected epithelium is assumed to show an increased risk for malignant transformation as certain studies have shown that the involved bacterial toxins, cytokines and inflammatory mediators of chronic inflammation have a potential for malignant transformation in-vitro [5-7] Bacterial and viral infections may also induce a chronic inflammation with the potential for malignant transformation [1].

A number of the benign conditions like condylomata acuminata, focal epithelial dysplasia, respiratory papillomatosis, gingival warts,

and cervical cancers have been found to associated with the papilloma virus. These viruses have also found to be associated with head and neck cancers specifically oropharynx and the base of the tongue [8].

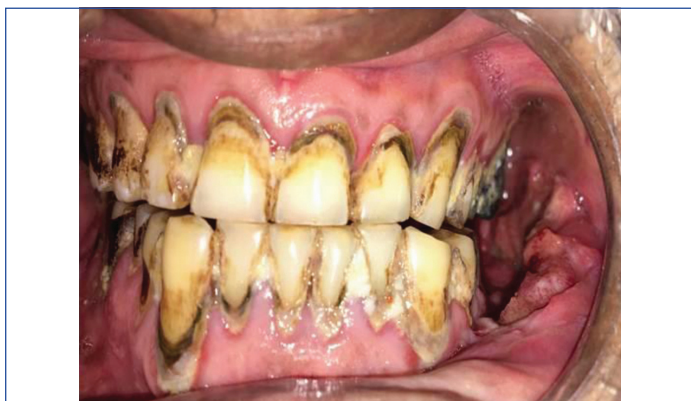The basal cells of the epithelium are usually and exclusively infected by the human papillomavirus. The abrasion or the exposure of the parabasal cells like in transformation zone of the uterine cervix provides the access to the HPV. Periodontal pockets serve as the nice for the latent HPV. Infected cells serve as source for the latent virus to proliferate and differentiate. Thereby, the HPV may be considered as an additional independent risk factor for a subset of Head and Neck Cancers (HNCs). However, most HPV infections are not responsible for causing malignancy, as they are cleared rapidly [2]. The most important risk factor for the carcinogenesis is the persistence of the HPV, in the periodontal pockets in the latent state [2,9].

Thus, the present study was taken up to detect the relationship between OSCC, HPV and periodontitis.

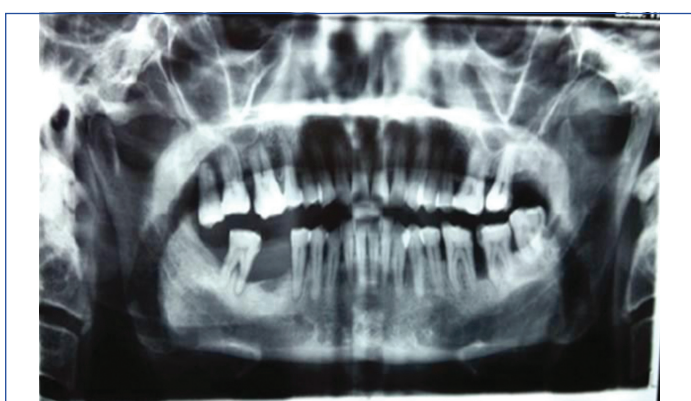MATERIALS AND METHODS

This cross-sectional study was designed to detect the occurrence of OSCC and HPV status in chronic generalised periodontitis patients. Patients were selected from the Department of Oral and Maxillofacial Surgery, College of Dental Sciences, Davangere, Karnataka, India. The study was stretched from September 2015-October 2017 after ethical approval was taken from the university board with the reference number CODS/977. Informed consents were obtained from all the participating subjects.

Inclusion criteria: Patients with age greater than 21 years, diagnosed with squamous cell carcinoma affecting alveoli and gingiva. [Table/Fig-1,2] along with radiographic appearance of chronic periodontitis i.e. bone loss [Table/Fig-2] and no history of periodontal therapy done in last three months, were included in the study.



[Table/Fig-1]: Carcinoma of the mandibular left alveolar region.



[Table/Fig-2]: Orthopantomogram of a patient with periodontitis and carcinoma of the mandibular left alveolar region.

Exclusion criteria: Patients with immunodeficiency congenital anomalies, trauma, and any accident that involves the periodontium, edentulous patients, patients with a history of organ transplant, amyloidosis, HIV infection, autoimmune disorders, those with any other systemic conditions like diabetes, hypertension etc., pregnant and lactating mothers and those patients with a history of antibiotics and steroids medication within last one month, were excluded in the study.

Study Procedure

The parameters selected for the study were age, sex, marital status, smoking, alcohol, mobility (Millers classification 1950) [10], missing teeth, TNM staging (Tumour, Node, Metastasis) Stage 0-IV [11], tumour site, Community Periodontal Index (CPI) [12]. The presence of OSCC was confirmed and explained using the TNM staging, the presence/absence of HPV was confirmed by the PCR of the biopsy tissue and the chronic periodontitis was confirmed by the CPI index which elaborated the Clinical Attachment Loss (CAL) in the patients. Subgingival plaque sample was collected from the affected site with the help of the curette for the detection of the *Porphyromonas gingivalis* and *Tanerella forsythia* to confirm the diagnosis of chronic periodontitis. Radiological parameters included Orthopantomogram (OPG). Biopsy tissue sample was taken for the detection of HPV by PCR [13].

STATISTICAL ANALYSIS

Descriptive data that included Mean, Standard Deviations (SD) were determined for each clinical parameter in each group and were used for analysis. Chi-square test and Spearman's correlation were used to find association and correlation between the chronic generalised periodontitis, oral squamous cell carcinoma and human

papilloma virus status. The p-value of 0.05 or less was considered for statistical significance.


RESULTS

A total of 15 cases of chronic generalised periodontitis with squamous cell carcinoma were included in the study. [Table/Fig-3] shows seven were male and eight female patients, with a mean age of 50.8±10.65 years. Out of this, six patients were smokers and three consumed alcohol. The value of CPI ranged between 3-4, loss of attachment score ranged from 1-3. On microbiological examinations, *Tanerella forsythia* was found in two patients and four patients were positive for *Porphyromonas gingivalis*. In 11 patients, localisation of the tumour was found in relation to mandibular posterior and in four patients in maxillary posterior. In four patients out of total 15 patients, HPV was positive [Table/Fig-4].

Parameters		Frequency (n)
Gender	Male	7
	Female	8
Age		Average-35-70 years
Smoking (present)		6
Alcohol (present)		3
Oral hygiene (CPI)	CPI score 3	10
	CPI score 4	5
CAL	CAL=1	9
	CAL=2	5
	CAL=3	1
Tumour localisation	Mandibular posterior	11
	Maxillary posterior	4
	In vestibule	4
	On alveolus and alveolar ridge	6
	In gingivo-buccal sulcus	3
	In Retromolar Trigone (RMT) region	2
Radiologic signs of periodontal disease		Present
Tumour, Node, Metastasis (TNM) staging	Stage I	3
	Stage II	6
	Stage III	6
Bleeding on probing		Present
Periodontal marker bacteria	<i>Tanerella forsythia</i>	2
	<i>Porphyromonas gingivalis</i>	4
Human Papilloma Virus (HPV) status	Positive	4
	Negative	11

[Table/Fig-3]: Demographic details.

CPI: Community periodontal index; CAL: Clinical attachment loss



[Table/Fig-4]: Electrophoretic band showing Human Papilloma Virus (HPV) detection. DNA: Deoxyribonucleic acid

On examination of the mobility of the teeth of the patients, nine patients had grade I mobility, three had Grade II mobility and in one patient, the mobility was Grade III. Two patients presented with no mobility of the teeth. A total of 13 patients were found to be partially edentulous, on the other hand, two patients were found to be completely dentulous.

On comparison between chronic generalised periodontitis and oral squamous cell carcinoma, a non significant association and a negative correlation was found [Table/Fig-5] and HPV status [Table/Fig-6] and also on comparing OSCC and HPV status [Table/Fig-7] non significant association and a negative correlation was found.

OSCC	CPI scores		Loss of attachment score		
	CPI score 3	CPI score 4	LOA=1	LOA=2	LOA=3
STAGE I	2 (66.7%)	1 (33.3%)	1 (33.3%)	2 (66.7%)	0 (0%)
STAGE II	4 (66.7%)	2 (33.3%)	5 (50%)	1 (25%)	1 (25%)
STAGE III	4 (66.7%)	2 (33.3%)	3 (60%)	2 (40%)	0 (0%)
p-value	1.000		0.487		
(Chi-square)	0		3.483		
r-value (Spearman's)	0		-0.068		
p-value	1		0.810		

[Table/Fig-5]: Correlation between the chronic periodontitis and OSCC status.
OSCC: Oral squamous cell carcinoma, CPI: Community periodontal index, LOA: Loss of attachment, p-value- Chi-square, r-value-Spearman correlation

HPV status	CPI scores		Loss of attachment		
	CPI score 3	CPI score 4	LOA=1	LOA=2	LOA=3
Present	3 (75%)	1 (25%)	2 (66.7%)	1 (33.3%)	0 (0%)
Absent	7 (63.6%)	4 (36.4%)	7 (58.3%)	4 (33.3%)	1 (8.3%)
p-value	0.68		0.774		
(chi-square)	0.170		0.511		
r-value (Spearman's)	-0.107		0		
p-value	0.705		1		

[Table/Fig-6]: Correlation between the chronic periodontitis and HPV status.
HPV: Human papilloma virus, CPI: Community periodontal index, LOA: Loss of attachment, p-value- Chi-square, r-value-Spearman correlation

HPV status	Oral squamous cell carcinoma		
N=15	Stage I	Stage II	Stage III
Present	1 (25%)	2 (50%)	1 (25%)
Absent	2 (18.2%)	4 (36.4%)	5 (45.5%)
Chi-square	0.511		
p-value	0.774		
r-value (Spearman's)	-0.169		
p-value	0.548		

[Table/Fig-7]: Correlation between HPV status and OSCC.
OSCC: Oral squamous cell carcinoma, HPV: Human papilloma virus, CPI: Community periodontal index, LOA: Loss of attachment, p-value-chi-square, r value-spearman correlation

DISCUSSION

In the present study, 15 chronic generalised periodontitis patients affected with squamous cell carcinoma of alveoli and gingiva were selected based on the history, clinical findings and the radiographic findings. The plaque sample for the detection of microbes was collected with the curette from the affected site (subgingival plaque) rather than the paper points. As with the curette, the amount of sample collected was more than the paper points as the curette collects the plaque sample from the entire pocket, whereas the paper point collects plaque sample from the most coronal and outer portion of the pocket [14].

Microbiological culture was used to assess the presence of red complex bacteria especially *Porphyromonas gingivalis* and

Tannerella forsythia. As these bacteria are associated with the bleeding on probing, an important clinical measurement of destructive periodontal diseases and also, pocket depth [15]. *Treponema denticola* was not included in the study, as this microbe cannot be cultured.

From the chronic periodontitis, patients histopathologically confirmed with OSCC gingival tissue samples sections embedded in paraffin wax blocks were sent for the detection of HPV by Polymerase chain reaction (PCR). In the present study, conventional PCR was chosen. The gingival tissue samples were selected for the detection of viral DNA, as it has been found out that HPV cell cycle have been to be in a close association with the differentiation of the epithelial cells, it infects. HPV has the property of infecting the deeper layers of the epithelium and reach the basal layer, without causing any significant lesion as the junctional epithelium connects the gingival sulcus with the connective tissue through a gap in the epithelial barrier. Thus, the gingival tissue serve as the reservoir for the virus and release the proinflammatory cytokines. This causes an instability of the cell defense mechanisms and leads to the development of the periodontitis [16]. Also, in a study by Madinier I et al., have shown various genotypes of HPV i.e. 6, 11, and or 16 have been detected by southern blot in 30% of the gingival specimens involved in the acute gingivitis or periodontal diseases without recognised clinical manifestations of viral infections [17].

A number of studies have been done off late, to illustrate if any correlation and association of these entities. studies by Ali A et al., [18], Salah El-Dein G et al., [19] have found and thus, proved a feeble association between chronic periodontitis and HR-HPV (high-risk HPV) infection. The association of chronic periodontitis with OSCC indicate poor oral hygiene as an important risk factor in its aetiology. Chronic infection, therefore, has both direct and indirect effects in causing carcinogenesis i.e. through toxic effect of microorganisms and through inflammation respectively [20].

In the present study, no significant association and correlation could be established between Chronic Generalised Periodontitis (CGP) and different stages of OSCC. The result of the present study is similar to a study by Virtanen E et al., [21] in which out of 286 patients with chronic periodontitis when followed over a period of 24 years, only 18 developed cancer.

In the present study, the authors have found that out of 15 CGP patients HPV was present in the tissue sample of only four patients. The results of the present study confirm the previous study by Jacob A et al., [22] wherein they could not establish any association of HPV and chronic periodontitis. The reason for such non significant association could be attributed to the small sample size. In a systematic review by Ortiz AP et al., the rate of the occurrence of HPV in periodontitis patients was more likely to present in patients with severe periodontitis in contrast to patients with mild form of periodontitis the percentage of association was significantly lower [23].

Neither a significant association nor correlation could be established between the HPV status and OSCC staging. Out of 15 patients, four patients with HPV positive status were distributed in different stages of OSCC i.e. stage I,II,III. The present study results confirm the results of some previous studies [24-26] describing the association of HR-HPV (high-risk human papilloma virus) status. In another study, by Lingen MW et al., on oral squamous cell carcinoma patients, 24 cases reported to be HPV positive out of 409 studied cases [27] which was found to be non significant. Also, study by Reuschenbach M et al., in 2013 a lack of evidence of HPV attributable fraction by ISH (in-situ hybridisation) in OSCC patients indicated a poor association and correlation between HPV induced OSCC. The study found that, out of 275 OSCC patients, 69 patients tested positive by PCR-EIA (Enzyme Immunoassay) whereas, ISH was found to be negative in all of them, which is in accordance with the present study [28].

Limitation(s)

Small sample size, and a short duration of the study were the main limitations.

CONCLUSION(S)

In the present study, a significant association and correlation between patients with chronic periodontitis, oral squamous cell carcinoma and HPV, was not established. A link between OSCC and poor oral hygiene has been suggested, over two decades, but a clear mechanism between the two is not understood. HPV which is one of the most important aetiological factor in the causing OSCC, and the same time chronic inflammation of the periodontium, also increases the probability of causing OSCC. A proper connection between the oral HPV and periodontitis is not yet established, whether it is through the direct effects of bacteria or through stimulation of inflammation, is yet to be determined. Hence, studies with larger sample size needs to be conducted.

REFERENCES

- [1] Moergel M, Kämmerer P, Kasaj A, Armouti E, Alshihri A, Weyer V, et al. Chronic periodontitis and its possible association with oral squamous cell carcinoma-a retrospective case control study. *Head Face Med.* 2013;9:39. Doi: 10.1186/1746-160X-9-39.
- [2] Tezal M, Sullivan Nasca M, Stoler DL, Melendy T, Hyland A, Smaldino PJ, et al. Chronic periodontitis-human papillomavirus synergy in base of tongue cancers. *Arch Otolaryngol Head Neck Surg.* 2009;135(4):391-96.
- [3] Khajuria N, Metgud R. Role of bacteria in oral carcinogenesis. *Indian J Dent.* 2015;6(1):37-43.
- [4] Krüger M, Hansen T, Kasaj A, Moergel M. The correlation between chronic periodontitis and oral cancer: A case report. *Case Reports in Dentistry* 2013;2013:01-08. <https://doi.org/10.1155/2013/262410>.
- [5] Coussens LM, Werb Z. Inflammation and cancer. *Nature.* 2002;9:860-67. Doi: 10.1038/nature01322.
- [6] Sharma M, Bairy I, Pai K, Satyamoorthy K, Prasad S, Berkovitz B, et al. Salivary IL-6 levels in oral leukoplakia with dysplasia and its clinical relevance to tobacco habits and periodontitis. *Clin Oral Investig.* 2011;15(5):705-14.
- [7] Guerra L, Guidi R, Frisan T. Do bacterial genotoxins contribute to chronic inflammation, genomic instability and tumour progression? *Febs J.* 2011;278(23):4577-88.
- [8] Dayakar MM, Shipilova A, Gupta D. Periodontal pocket as a potential reservoir of high-risk human papilloma virus: A pilot study. *J Indian Soc Periodontol.* 2016;20(2):136-40.
- [9] Pierce Campbell CM, Kreimer AR, Lin HY, Fulp W, O'Keefe MT, Ingles DJ, et al. Long-term persistence of oral human papillomavirus type 16: The HPV Infection in Men (HIM) study. *Cancer Prev Res.* 2015;8(3):190-96.
- [10] Miller SC. *Textbook of Periodontia.* 3rd edition. Philadelphia the Blakeston Co; 1950.
- [11] Hermanek P, Sobin LH, 1992 *Text book of Oral Pathology.* Shafers.
- [12] WHO. *Oral Helath Surveys Basic Methodology,* Geneva: WHO; 1997.
- [13] Neena D, Shah S, Patel K, Munira J. Histological grading of oral cancer: A comparison of different systems and their relation to lymph node metastasis. *Nat J Commun Med.* 2011;2:136-42.
- [14] Al Ahdab HMN. Comparison of curette and paper point sampling of subgingival plaque bacteria as analysed by real-time PCR. Saudi Arabia: University of Bonn. 2006. Doi: 10.1902/jop.2007.060218.
- [15] Socransky SS, Haffajee AD, Cugini MA, Smith C, Kent RL Jr. Microbial complexes in subgingival plaque. *J Clin Periodontol.* 1998;25(2):134-44.
- [16] Cavalcanti EFF, Silva CR, Ferreira DC, Ferreira MVM, Vanderborgh PR, Torres MCMB, et al. Detection of human papillomavirus in dental biofilm and the uterine cervix of a pregnant adolescent. *Sao Paulo Med J.* 2014;134:88-91. Doi: 10.1590/1516-3180.2014.8812810.
- [17] Madinier I, Doglio A, Cagnon L, Lefebvre JC, Monteil RA. Southern blot detection of human papillomaviruses (HPVs) DNA sequences in gingival tissues. *J Periodontol.* 1992;63(8):667-73.
- [18] Ali A, Rumbold AR, Kapellas K, Lassi ZS, Hedges J, Jamieson L, et al. Association between self-reported periodontitis and high-risk oral human papillomavirus infection among Indigenous South Australians: A cross-sectional study. *PLoS One.* 2022;17:01-12. <https://doi.org/10.1371/journal.pone.0265840>.
- [19] Shaltouta SEG, El-Dein HMS, Elasers DA, Shahine MS, Abbas HS, Osman MH. Study the association among human papilloma virus subtypes 16 and 18, codon 72 P53 gene polymorphism, and oral squamous cell carcinoma in Upper Egypt: A case-control study. *Egypt J Oral Maxillofac Surg.* 2020;39:364-70. Doi: 10.4103/ejs.ejs_215_19.
- [20] Vu H, Shin YJ, Kong MS, Kim HD. Smoking and drinking adjusted association between head and neck cancers and oral health status related to periodontitis: A meta-analysis. *J Korean Med Sci.* 2021;36(15):01-16.
- [21] Virtanen E, Söder PO, Meurman J, Andersson LC, Söder B. Chronic periodontal disease: A proxy of increased cancer risk. *Int J Cancer Res.* 2013;47:1127-33. https://www.researchgate.net/publication/258170654_Chronic_Periodontal_Disease_A_Proxy_of_Increased_Cancer_Risk.
- [22] Jacob A, Janam P, Babu Vijayamma JM. Prevalence of human papilloma virus in marginal periodontium and its association with periodontitis: A cross sectional study. *J Indian Soc Periodontol.* 2014;18(4):447-50.
- [23] Ortiz AP, González D, Vivaldi-Oliver J, Castañeda M, Rivera V, Díaz E, et al. Periodontitis and oral human papillomavirus infection among hispanic adults. *Papillomavirus Res.* 2018;5:128-33. Doi: 10.1016/j.pvr.2018.03.003. Epub 2018 Mar 16.
- [24] Isayeva T, Li Y, Maswahu D, Brandwein-Gensler M. Human papillomavirus in non-oropharyngeal head and neck cancers: A systematic literature review. *Head Neck Pathol.* 2012;6:104-20. Doi: 10.1007/s12105-012-0368-1. Epub 2012 Jul 3.
- [25] Dalakoti P, Ramaswamy B, Bhandarkar AM, Nayak DR, Sabeena S, Arunkumar G, et al. Prevalence of HPV in oral squamous cell carcinoma in South West India. *Indian J Otolaryngol Head Neck Surg.* 2019;71:657-64. Doi: 10.1007/s12070-018-1470-9. Epub 2018 Aug 21.
- [26] Chowdary SD, Sekhar PC, Kattapagari KK, Deepthi CHM, Neelima D, Reddy BVR. A study to assess expression of human papillomavirus types 16 and 18 in oral squamous cell carcinoma using polymerase chain reaction. *J Oral Maxillofac Pathol.* 2018;22(3):347-52.
- [27] Lingen MW, Xiao W, Schmitt A, Jiang B, Pickard R, Kreinbrink P, et al. Low aetiologic fraction for high-risk human papillomavirus in oral cavity squamous cell carcinomas. *Oral Oncol.* 2013;49(1):01-08.
- [28] Reuschenbach M, Kansy K, Garbe K, Vinokurova S, Flechtenmacher C, Toth C, et al. Lack of evidence of human papillomavirus-induced squamous cell carcinomas of the oral cavity in southern Germany. *Oral Oncol.* 2013;49(9):937-42.

PARTICULARS OF CONTRIBUTORS:

1. Assistant Professor, Department of Periodontology, SGT Dental College, Gurugram, Haryana, India.
2. Professor and Head, Department of Periodontology, College of Dental Sciences, Davangere, Karnataka, India.

NAME, ADDRESS, E-MAIL ID OF THE CORRESPONDING AUTHOR:

Shikha Sharma,
H-95, Chander Nagar, Gurugram, Haryana, India.
E-mail: shikha1390@gmail.com

PLAGIARISM CHECKING METHODS: [Jan H et al.]

- Plagiarism X-checker: Jun 27, 2022
- Manual Googling: Oct 21, 2022
- iThenticate Software: Nov 01, 2022 (11%)

ETYMOLOGY: Author Origin

AUTHOR DECLARATION:

- Financial or Other Competing Interests: None
- Was Ethics Committee Approval obtained for this study? Yes
- Was informed consent obtained from the subjects involved in the study? Yes
- For any images presented appropriate consent has been obtained from the subjects. Yes

Date of Submission: **Jun 02, 2022**
Date of Peer Review: **Aug 19, 2022**
Date of Acceptance: **Nov 02, 2022**
Date of Publishing: **Jan 01, 2023**