



Ophthalmology Research: An International Journal

7(4): 1-6, 2017; Article no.OR.37637
ISSN: 2321-7227

Infectious Keratitis: An Immediate Cause of Concern

**Deepankar Srigyan¹, Mandakini Gupta², Saima Ahsan³
and Himanshu Sekhar Behera^{4*}**

¹Department of Microbiology, All India Institute of Medical Sciences, New Delhi, India.

²Centralized Accident and Trauma Centre, Laxmi Nagar, New Delhi, India.

³Department of Optometry and Ophthalmic Techniques, All India Institute of Medical Sciences,
New Delhi, India.

⁴Department of Ocular Microbiology, Dr. R.P. Centre for Ophthalmic Sciences, All India Institute of
Medical Sciences, New Delhi, India.

Authors' contributions

This work was carried out in collaboration between all authors. Author HSB designed the study and gave the final touch to the article after some corrections. Author DS wrote the first draft of the manuscript. Authors MG and SA helped in collecting the literatures. All authors read and approved the final manuscript.

Article Information

DOI: 10.9734/OR/2017/37637

Editor(s):

(1) Tatsuya Mimura, Department of Ophthalmology, Tokyo Women's Medical University Medical Center East, Japan.

Reviewers:

(1) Asaad Ahmed Ghanem, Mansoura University, Egypt.

(2) Gabor Nemeth, University Teaching Hospital, Hungary.

(3) J. Malathi, Sankara Nethralaya, India.

Complete Peer review History: <http://www.sciencedomain.org/review-history/21903>

Review Article

Received 23rd October 2017
Accepted 11th November 2017
Published 14th November 2017

ABSTRACT

Cornea is a transparent structure present at the center of eye, which acts as a protective barrier against harmful objects and plays an important role in vision. Corneal disorders are major cause of concern as they have fatal ocular consequences. These disorders may be due to any degenerative disorders like keratoconus or have infectious origin or dystrophies due to hereditary causes. They can lead to visual impairment or sometimes vision loss, if not treated ontime. Visual disability of cornea due to infectious etiology is preventable if identified and treated earlier. Infective corneal ulcers or microbial keratitis is more common among all corneal diseases. Other corneal diseases due to infectious origin are herpes zoster ophthalmicus, peripheral ulcerative keratitis and phlyctenular keratoconjunctivitis. There is availability of advance diagnostic techniques to identify

*Corresponding author: E-mail: himansubt@gmail.com;

these diseases in earlier stage, which can guide appropriate therapeutic options. There is a need of knowledge and awareness about these diseases for identification, proper management and prevention of ocular morbidity.

Keywords: Corneal disorders; corneal ulcer; microbial keratitis; herpes zoster ophthalmicus; peripheral ulcerative keratitis; phlyctenular keratoconjunctivitis.

ABBREVIATIONS

HSV : Herpes simplex virus;
HZO : Herpes zoster ophthalmicus;
PUK : Peripheral ulcerative keratitis;
VZV : Varicella- zoster virus;
LPCB : Lacto phenol cotton blue.

1. INTRODUCTION

The cornea is an important barrier against dirt, microbes, and other particles that can harm the eye. It also plays a key role in vision. It is the transparent tissue at the front and center of the eye, which permits and refracts light to pass inside, through the pupil, lens, and at the back of the eye onto the retina. The curvature of the cornea plays an important role in focusing the light [1]. The term "corneal disorder" refers to a variety of conditions that mainly affect the cornea. These include infections, dystrophies, and many other conditions that may arise as a result of heredity. Corneal diseases due to infectious causes need immediate attention because visual disability due to them can be preventable, if treatment started ontime. These diseases include corneal ulcer, microbial keratitis, herpes zoster ophthalmicus, peripheral ulcerative keratitis and phlyctenular keratoconjunctivitis.

This article focuses on the important corneal diseases which have an infectious etiology and their diagnostic modalities and management. We describe the salient clinical features and diagnostics of different corneal diseases which can help to begin an appropriate management.

2. CORNEAL DISORDERS WITH INFECTIOUS ETIOLOGY

2.1 Corneal Ulcer

It is a defect in the corneal epithelial cell layer, which may have traumatic, mechanical, infective or neurotrophic etiology. Direct trauma to the cornea leads to corneal abrasions, leaving a clear epithelial defect. Such epithelial defects can

also be caused by burns, which may be thermal, chemical or radiation, known as corneal burns. Mechanical causes of corneal ulcers are drying out and sloughing of the corneal epithelium due to exposure from lagophthalmos, lid defects or ectropion. Patients present with pain and mildly decreased visual acuity. Chronic allergic ocular conditions such as vernal keratoconjunctivitis can also cause corneal ulcers. Neurotrophic corneal ulcers develop in case of sensory deficit of the cornea, like trigeminal nerve palsy. It is a painless ulcer with depressed corneal sensation [2-5].

A staining defect with a clear underlying cornea reveals on examination. Management involves promoting epithelial healing, prevention of infection and pain relief. Patching of affected eye helps in epithelial healing and pain relief. Topical antibiotics are prescribed for preventing possible superimposed infections. Adequate tear supplementation is warranted in case of mechanical causes of corneal ulcer. Infective corneal ulcers are known as microbial keratitis [6,7].

2.2 Microbial Keratitis

Microbial keratitis is an ophthalmic emergency, that involves a loss of integrity of the corneal epithelium and a significant cause of ocular morbidity and vision loss. It may be caused by bacteria, fungi, viruses, or parasites. Predisposing risk factors for microbial keratitis are ocular trauma, contact lens use, topical steroid use, chronic ocular surface disease, eyelid abnormalities, previous ocular surgery and diabetes [2,7,8]. It is a potentially vision threatening condition that requires early diagnosis and management to prevent serious outcomes. In developed countries like United States, the incidence of microbial keratitis is approximately 11.0 per 100,000 person years and 799 per 100,000 person years in the developing countries [6]. Predisposing risk factors may vary tremendously on global level. In developing countries like India and Nepal, non-surgical eye trauma accounted for 48.6–65.4% of all corneal ulcers and in the United States, non-

surgical trauma to the eye accounted for only 27% of all cases [6].

Staphylococcus aureus, Coagulase-negative *Staphylococcus*, *Pseudomonas aeruginosa*, *Streptococcus pneumoniae*, and *Serratia* sp. are the most common causative agents of bacterial keratitis. Fungal keratitis is reported mainly from developing countries of the world, predominantly occurs after ocular trauma. It is mainly caused by filamentous fungi such as *Fusarium* and *Aspergillus* sp., and some yeasts, mainly *Candida* (Fig. 1). Among viruses, Herpes simplex virus (HSV) and among parasites *Acanthamoeba* sp. are the most common cause of microbial keratitis [9-11].

The common sign and symptoms are pain, redness, photophobia, blurring of vision, watering or discharge from the eye [6]. Presumed microbial keratitis is mainly investigated with microscopy and culture of corneal scrapings from infiltrated area. Smears, culture and antimicrobial drug susceptibility are the most common and fundamental tools for the laboratory diagnosis of microbial keratitis [12,13,14]. Antibiotic eye drops based on sensitivity pattern of causative bacteria is the main stay of treatment of bacterial keratitis. In case of fungal keratitis, commonly used antifungal drugs are voriconazole (1%), amphotericin B (0.15%), miconazole and fluconazole eye drops [9]. Current antivirals for

HSV keratitis includes acyclovir, ganciclovir, penciclovir, triflurothymidine and valacyclovir [10,15]. In case of *Acanthamoeba* keratitis, chlorhexidine 0.02% is often used in combination with aromatic diamidines such as 0.1% propamidine isothionate, hexamidine 0.1% and neomycin [16,17,18].

2.3 Herpes Zoster Ophthalmicus (HZO)

It is caused by the reactivation of the varicella-zoster virus (VZV) infection i.e. Zoster, which is present as a painful dermatomal rash on skin and mucosa. It also affects the ophthalmic division of the trigeminal nerve and subsequent eye. HZO often includes severe chronic pain and vision loss that's why it is considered as an ophthalmologic emergency. Primarily, diagnosis is based on history and skin findings [19]. Varicella is caused by human herpesvirus type 3 in childhood. After primary infection, the virus remains dormant in neurosensory ganglia. After years it may be reactivated, which results in the cutaneous disease commonly known as herpes zoster or shingles [20].

According to the Center for Disease Control and Prevention (CDC), annually there are an estimated 1 million cases of herpes zoster in the US, and approximately 1 in 3 people have develop shingles during their lifetime [21-23]. Up to 4% of patients presenting with HZO require

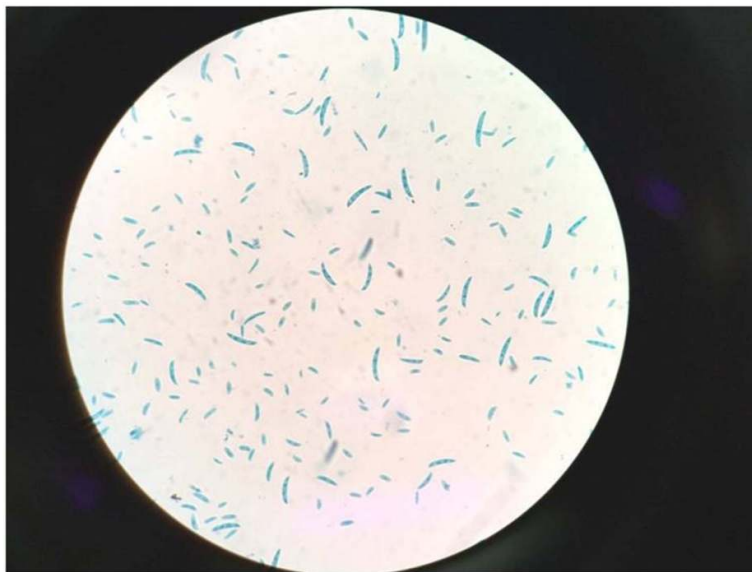


Fig. 1. Microconidia of *Fusarium* sp. (a common causative agent of fungal keratitis) in LPCB mount (x400)

hospitalization for management of complications and to decrease longterm morbidity [23]. HZO represents 10% to 20% of all herpes zoster cases [21,23]. First-line interventions include treatment with systemic antiviral drugs, such as acyclovir. The Zostavax vaccine is recommended for persons older than 50 years of age. For postexposure prophylaxis varicella zoster immune globulin is also available [20].

2.4 Peripheral Ulcerative Keratitis (PUK)

PUK includes infectious and inflammatory conditions that usually result in peripheral corneal thinning. It is associated with an epithelial defect and progressive loss of the corneal stroma. Inflammatory causes are associated with autoimmune collagen vascular diseases. In a study, it was reported that in 50% cases of collagen vascular disease PUK was the initial manifestation [24-26]. Rheumatoid arthritis, sarcoidosis, polyarteritis nodosa and Wegener's granulomatosis are some of the possible causes, of which rheumatoid arthritis is the most common accounting for 34% [25-27]. Local autoimmune syndromes, for e.g. Mooren's ulcers are also a possibility. Blepharitis can be a common cause of such condition (marginal keratitis). Intensive immunosuppression and adequate management of the blepharitis is important in these cases [24,28,29].

In addition to autoimmune disorders, microbial organisms such as bacteria, fungi, viruses, and *Chlamydia* can cause PUK. The exact pathophysiologic mechanism of PUK is yet unclear. The main symptoms are pain, redness, tearing, photophobia, and decreased vision secondary to corneal opacity in advanced cases [24,30]. Treatment of underlying systemic autoimmune disease has beneficial effects on ocular manifestations, which is mainly a systemic corticosteroids plus a cytotoxic agent (according to the underlying systemic disease) during the acute phase of the disease. Collagenase inhibitors, such as topical 20% acetylcysteine and topical 1% medroxyprogesterone, may be useful in reducing stromal ulceration. Infliximab is currently indicated for treatment of connective tissue, accompanying PUK, doses vary from 3 mg/kg IV for rheumatoid arthritis to 5 mg/kg IV for Crohn's disease, given at weeks 0, 2, and 6, and then every 8 weeks for up to 18 months. Use of a tissue adhesive, tectonic corneal grafting, lamellar graft and amniotic membrane transplantation are the options in surgical management [24,31,32].

2.5 Phlyctenular Keratoconjunctivitis

It is a nodular inflammation of conjunctiva or cornea that results from a allergic reaction to a foreign antigen, which represents a cell-mediated hypersensitivity response. Due to the high prevalence of tuberculosis in last century, as a consequence of a hypersensitivity reaction to tuberculin protein this disease occurred predominantly in children with positive tuberculin skin tests. It occurs primarily in paediatrics from 6 months to 16 years of age group [33]. Microbial proteins of *Staphylococcus aureus* are the most common causative antigens of phlyctenular keratoconjunctivitis in developed countries like United States [34]. In a study, 80.4% of patients had the mean age of 10.2 years with female preponderance [34]. Antigens of *Mycobacterium tuberculosis* and *Staphylococcus aureus* are most commonly associated; however, *Streptococcus viridians*, chlamydia and intestinal parasites including *Hymenolepis nana* have also been reported as causative agents. Conjunctival lesions may cause mild to moderate irritation in the eye, while corneal lesions presented with severe pain and photophobia [35].

The diagnosis is based on history and clinical examination findings, further investigation is required when the possibility of chlamydia or tuberculosis is suspected. Chest radiographs, tuberculin skin tests should be done for patients with a history or symptoms of tuberculosis infection. For patients suspected with chlamydia infection, immunofluorescent antibody test and PCR of conjunctival swabs provide accurate and quick screening [33,36]. The first line of treatment is to decrease the inflammatory response, which generally responds to topical steroids. In one study, topical cyclosporine A (2%) eye drop was effective in severe paediatric cases, steroid dependent and cases with multiple recurrences [37]. Azithromycin or doxycycline should be prescribed in *Chlamydia* induced phlyctenular keratoconjunctivitis. Complete course of tuberculosis treatment is warranted in patients with positive tuberculin tests [37,38].

3. CONCLUSIONS

Corneal disorders have been described since a long time, but even today, despite the availability of advance diagnostic techniques and a wide range of antimicrobials they still pose a diagnostic and therapeutic challenge. These disorders are the public health problem not only in developing countries but also in developed

nations. Corneal diseases are the major contributing factor in the vision loss in all age group of patients. So, there is a need of knowledge and awareness about these diseases for early detection and prompt administration of correct treatment to prevent fatal ocular consequences.

CONSENT

Consent was obtained from all individual participants included in the presentation of review article.

ETHICAL APPROVAL

It is not applicable.

ACKNOWLEDGEMENT

I sincerely thanks to both of my co-authors for preparation of this review article.

COMPETING INTERESTS

Authors have declared that no competing interests exist.

REFERENCES

1. Derek W DeMonte, Terry Kim. Anatomy and physiology of the cornea. J Cataract Refract Surg. 2011;37:588–598.
2. Julia DC, Patricia G, Fabio PS. Corneal ulcer: A retrospective study. Rev Bras Oftalmol. 2015;74(2):76-80.
3. Ballim S. Corneal ulcers: For the general practitioner. South African Medical Journal (SAMJ). 2013;31(11):399-401.
4. Garg, Prashant, Gullapalli N Rao. Corneal ulcer: Diagnosis and management. Community Eye Health. 1999;12(30):21–23.
5. Srinivasan M, Gonzales CA, George C, Cevallos V, Mascarenhas JM, Asokan B, et al. Epidemiology and aetiological diagnosis of corneal ulceration in Madurai, South India. British Journal of Ophthalmology. 1997;81:965-971.
6. Upadhyay MP, Karmacharya PC, Koirala S, Shah DN, Shakya S, Shrestha JK, et al. The Bhaktapur eye study: Ocular trauma and antibiotic prophylaxis for the prevention of corneal ulceration in Nepal. Br J Ophthalmol. 2001;85:388–92.
7. Thomas PA, Geraldine P. Infectious keratitis. Curr Opin Infect Dis 2007;20(2): 129-141.
8. Day S, Lalitha P, Haug S, Fothergill AW, Cevallos V, Vijayakumar R, et al. Activity of antibiotics against *Fusarium* and *Aspergillus*. Br J Ophthalmol. 2009;93(1): 116-119.
9. Thomas PA, Kaliamurthy J. Mycotic keratitis: Epidemiology, diagnosis and management. Clin Microbiol Infect. 2013;19:210–220.
10. Suresh PS, Tullo AB. Herpes simplex keratitis. Current Ophthalmology. 1999;47: 155-165.
11. Green M, Apel A, Stapleton F, Edwards K, Keay L, Naduvilath T, et al. Risk factors and causative organisms in microbial keratitis. Cornea. 2008;27:22–27.
12. Jeng BH, McLeod SD. Microbial keratitis. British Journal of Ophthalmology. 2003;87:805-806.
13. Gopinathan U, Sharma S, Garg P, Rao GN. Review of epidemiological features, microbiological diagnosis and treatment outcome of microbial keratitis: Experience of over a decade. Indian J Ophthalmol. 2009;57:273–279.
14. Maharana PK, Sharma N, Nagpal R, Jhanji V, Das S, Vajpayee RB. Recent advances in diagnosis and management of mycotic keratitis. Indian J Ophthalmol. 2016;64: 346-57.
15. Michelle Lee White, James Chodosh. Herpes simplex virus keratitis: A treatment guideline. Corneal Disease. 2014;1-68.
16. Lim N, Goh D, Bunce C, Xing W, Fraenkel G, Poole T. Comparison of polyhexamethylene biguanide and chlorhexidine as monotherapy agents in the treatment of *Acanthamoeba* keratitis. American Journal of Ophthalmology. 2008;145:130–135.
17. Solanki S, Rathi M, Khanduja S, Dhull CS, Sachdeva S, Phogat J. Recent trends: Medical management of infectious keratitis. Oman Journal of Ophthalmology. 2015;8(2):83-85.
18. Deepankar Srigyan, Mandakini Gupta, Himanshu Sekhar Behera. Keratitis: An inflammation of cornea. EC Ophthalmology. 2017;6(6):171-177.
19. Thomas Catron H, Gene Hern. Herpes Zoster ophthalmicus. West J Emerg Med. 2008;9(3):174–176.

20. Ivan Vrcsek, Eileen Choudhury, Vikram Durairaj. Herpes Zoster ophthalmicus: A review for the internist. 2017;130(1):21-26.
21. Liesegang TJ. Herpes Zoster ophthalmicus natural history, risk factors, clinical presentation, and morbidity. Ophthalmology. 2008;115(2):S3-S12.
22. Insinga RP, Itzler RF, Pellissier JM, Saddier P, Nikas AA. The incidence of herpes zoster in a United States administrative database. J Gen Intern Med. 2005;20(8):748-753.
23. Ragozzino MW, Melton LJ, Kurland LT, Chu CP, Perry HO. Population-based study of herpes zoster and its sequelae. Medicine (Baltimore). 1982;61(5):310-316.
24. Yagci, Ayse. Update on peripheral ulcerative keratitis. Clinical Ophthalmology (Auckland, N.Z.) 2012;6:747-754.
25. Galor A, Thorne JE. Scleritis and peripheral ulcerative keratitis. Rheum Dis Clin N Am. 2007;33:835-854.
26. Ladas JG, Mondino BJ. Systemic disorders associated with peripheral corneal ulceration. Curr Opin Ophthalmol. 2000;11:468-471.
27. Gregory JK, Foster CS. Peripheral ulcerative keratitis in the collagen vascular diseases. Int Ophthalmol Clin. 1996;36: 21-30.
28. Srinivasan M, Zegans ME, Zelefsky JR, Kundu A, Lietman T, Whitcher JP, et al. Clinical characteristics of Mooren's ulcer in South India. Br J Ophthalmol. 2007;91:570-575.
29. Keenan DJ, Mandel MR, Margolis TP. Peripheral ulcerative keratitis associated with vasculitis manifesting asymmetrically as Fuchs superficial marginal keratitis and Terrien's marginal degeneration. Cornea. 2011;30:825-827.
30. Messmer EM, Foster CS. Vasculitic peripheral ulcerative keratitis. Surv Ophthalmol. 1999;43:379-396.
31. Galor A, Jabs DA, Leder HA, Kedhar SR, Dunn JP, Peters GB, Thorne JE. Comparison of antimetabolite drugs as corticosteroid-sparing therapy for noninfectious ocular inflammation. Ophthalmology. 2008;115:1826-1832.
32. Pham M, Chow CC, Badawi D, Tu EY. Use of infliximab in the treatment of peripheral ulcerative keratitis in Crohn's disease. Am J Ophthalmol. 2011;152:183-188.
33. Rohatgi J, Dhaliwal U. Phlyctenular eye disease: A reappraisal. Japanese Journal of Ophthalmology. 2000;44(22):146-150.
34. Teo L, Mehta JS, Htoon HM, Tan DT. Severity of pediatric blepharokeratoconjunctivitis in Asian eyes. Am J Ophthalmol. 2012;153(3):564-570.
35. Neiberg MN, Sowka J. Phlyctenular keratoconjunctivitis in a patient with Staphylococcal blepharitis and ocular rosacea. Optometry. 2008;79(3):133-137.
36. Venkateswaran N, Kalsow CM, Hindman HB. Phlyctenular keratoconjunctivitis associated with *Dolosigranulum pigrum*. Ocular Immunology and Inflammation. 2014;22(3):242-245.
37. Doan S, Gabison E, Gatinel D, Duong MH, Abitbol O, Hoang-Xuan T. Topical cyclosporine A in severe steroid-dependent childhood phlyctenular keratoconjunctivitis. American Journal of Ophthalmology. 2006;141(1):62-66.
38. Culbertson WW, Huang AJ, Mandelbaum SH, Pflugfelder SC, Boozalis GT, Miller D. Effective treatment of phlyctenular keratoconjunctivitis with oral tetracycline. Ophthalmology. 1993;100(9):1358-1366.

© 2017 Srigyan et al.; This is an Open Access article distributed under the terms of the Creative Commons Attribution License (<http://creativecommons.org/licenses/by/4.0>), which permits unrestricted use, distribution, and reproduction in any medium, provided the original work is properly cited.

Peer-review history:
The peer review history for this paper can be accessed here:
<http://sciencedomain.org/review-history/21903>