

# Ocular Complications of Steroid in a Patient Presenting With Vision Loss Having Duane Retraction Syndrome

Anamika Pandey<sup>a\*</sup>, Faraaz Hussain<sup>a<sup>o</sup></sup> and Abha Shah<sup>a<sup>≡</sup></sup>

<sup>a</sup> Department of Ophthalmology, MGM Hospital, Kamothe, India.

## Authors' contributions

*This work was carried out in collaboration among all authors. All authors read and approved the final manuscript.*

## Article Information

### Open Peer Review History:

This journal follows the Advanced Open Peer Review policy. Identity of the Reviewers, Editor(s) and additional Reviewers, peer review comments, different versions of the manuscript, comments of the editors, etc are available here: <https://www.sdiarticle5.com/review-history/83529>

**Case Report**

**Received 20 November 2021**

**Accepted 29 January 2022**

**Published 30 January 2022**

## ABSTRACT

Corticosteroids are an essential treatment modality for a wide number of diseases and are effective therapeutically but are heavily polluted with severe side effects. Topical and systemic steroids have been used in the treatment of a variety of disorders leading to complications. To monitor the possible complications of steroid therapy, routine follow ups are indicated. We report a case of 35 year old male who presented to the ophthalmology out-patient department (OPD) with gradual bilateral visual loss since few years. On eliciting detailed history, patient gave history of consuming steroids unmonitored since few years. In this report, we discuss the presentation of corticosteroid-induced cataract in a patient with Duane retraction syndrome who presented initially in ophthalmology OPD and was managed by a multi-speciality team to tackle the varied side effects of steroids taken by self-medication.

*Keywords: Duane retraction syndrome; steroids; posterior subcapsular cataract.*

## 1. INTRODUCTION

Corticosteroid therapy is useful in a wide range of diseases as its effects are numerous and

widespread. In addition, corticosteroids provide the organisms with the capacity to resist such stressful circumstances [1,2,3]. The dangers of steroids are now widely recognized, cataract

<sup>≡</sup> Junior Resident,

<sup>o</sup> Assistant Professor,

\*Corresponding author: E-mail: [anamikapandey050@gmail.com](mailto:anamikapandey050@gmail.com);

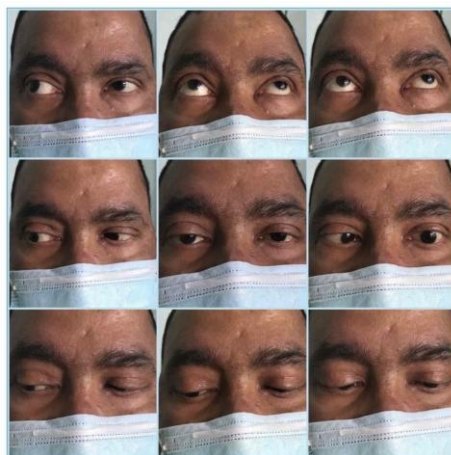being the most common ocular adverse effect closely followed by glaucoma [4]. Particular stress should be laid on the need to keep steroid dosage as low as possible as well as awareness should be created so as to avoid ocular side effects. Screening for cataracts should be performed by slit-lamp examinations conducted atleast three or four times a year for patients on long-term therapy and twice a year for patients taking intermittent topical ocular or systemic steroids. Glaucoma is more often associated with topical ocular or periocular steroids rather than with systemic steroids. We discuss the presentation of corticosteroid-induced cataract in a patient with Duane retraction syndrome who presented initially in ophthalmology OPD and was managed by a multi-specialty team to tackle the varied side effects of steroids taken by self-medication. Issues of steroid being available as over the counter medication and the lack of governing body authorization and monitoring has also been highlighted.

## 2. CASE REPORT

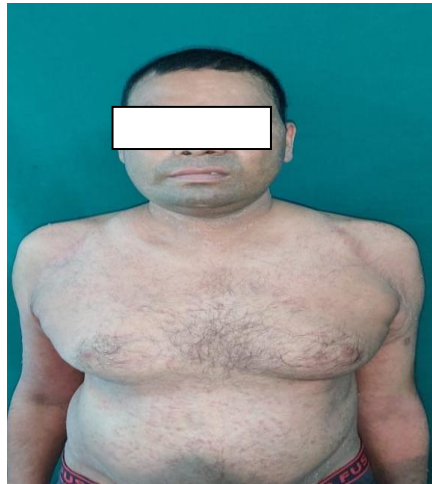A 35 year old male, presented with complain of diminution of vision in both eyes for distant and near since 1 ½ years. It was gradual, progressive and painless in nature. Patient had history of spectacle usage since 8 months, uncorrected at present. There was no history of previous ocular trauma or surgery. On detailed questioning, patient also gave history of consuming steroids (Tab Betnesol Forte) since last two years. He had started on these tablets for some skin condition and kept consuming it on his own for two years due to the “wellness” feeling he experienced and the easy availability of steroids over the counter (OTC). On complete ophthalmic evaluation, visual acuity for distance was finger

counting at 2m in both eyes and near vision was less than N36. Amsler’s grid test and colour vision was within normal limits in both the eyes. Intraocular pressure of was 16 mm/Hg in his right eye and 18 mm/Hg in his left eye. Anterior segment examination revealed posterior sub-capsular cataract in both eyes. Abduction was restricted in the left eye. Retraction of left eyeball and narrowing of the palpebral fissure on attempted abduction and widening of the palpebral fissure on adduction was noted. (Fig. 1) Patient was aware of this, but was not bothered much due to his primary gaze being minimally affected. Rest was within normal limits.

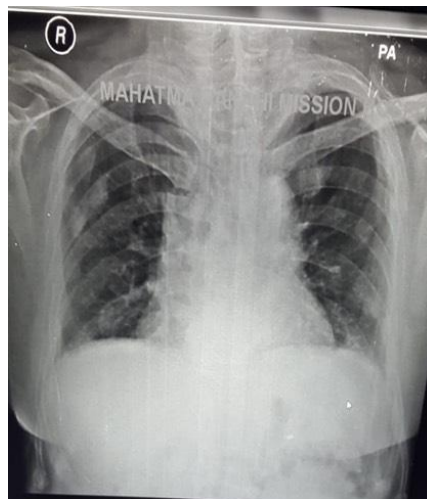
On detailed fundus examination, both eyes fundus was normal. On general examination skin lesions and back issues were also noted, hence a team of specialists was involved for his management. On physician consult, he was advised rheumatoid evaluation along with inflammatory markers. Dermatology consult revealed, hypertrichosis, striae on both shoulders, multiple discrete erythematous macules with scaling on trunk, dark discoloration of nails of bilateral fingers were found for which he was started on Tab Levocetizine at night, Tab Prednisolone 5mg once daily (tapered weekly), Fusidic acid cream for local application. On general examination, buffalo hump and swelling of face (cushinoid features) was noticed. (Fig. 2) Laboratory investigations revealed serum cortisol level as 0.8 ug/dl (suggestive of HPA axis suppression), serum creatinine as 0.54 mg/dl, ESR as 68, Chest X-ray and Mantoux PPD test was suggested to screen for tuberculosis, which showed opacities on right upper lobe.(Fig. 3) X-ray of lower limb was normal. Rest laboratory investigations were within normal limit.



**Fig. 1. 9 gaze photo showing abduction restricted in the left eye**



**Fig. 2. Showing buffalo hump and swelling of face (cushinoid features)**



**Fig. 3. Chest X-ray showing opacities on right upper lobe**

### 3. DISCUSSION AND CONCLUSION

Topical and systemic steroids have proven to be valuable agents in the treatment of a wide range of disorders, but their use is not without potential complications. The development of posterior subcapsular cataracts and glaucoma are major ocular side effects of systemic steroid therapy. Routine screening is indicated to prevent the ocular complications of long term steroid therapy. Gradual tapering is advised as rapid tapering or abrupt discontinuation of steroid use especially topical causes ocular rebound inflammation. Corticosteroid tapering usually can be accomplished by adding an immune-modulatory agent.

Black et al. found that in 17 of the 44 patients with rheumatoid arthritis who were treated with

prolonged corticosteroid therapy, developed Posterior subcapsular cataract [5].

Benjamin S Daniel and David Orchard conducted a retrospective study to determine the evidence on corticosteroids and their role in ocular diseases. The case study has highlighted the need to educate health practitioners as well as patients the importance of appropriate prescription and application of topical corticosteroids [6].

Physicians shall consider adverse effects and patient's underlying co-morbidities before prescribing steroids and use steroids judiciously. Stricter norms should be adopted on the availability and prescription of steroids by general practitioners. The legal approach should include the enforcement of the existing legislation related

to the control the over the counter availability of steroids, so that they are not sold without proper prescriptions. The primary goal underlying all ethical issues in health care is to see that knowledge gained through research should benefit and not cause harm to the society. This knowledge should be disseminated correctly and used practically to minimize harm.

### ETHICAL APPROVAL

As per international standard or university standard written ethical approval has been collected and preserved by the author(s).

### CONSENT

As per international standard or university standard, patients' written consent has been collected and preserved by the author(s).

### COMPETING INTERESTS

Authors have declared that no competing interests exist.

### REFERENCES

- 1 Bruton LL, Lazo JS, Parker KL. Goodman & Gilman'S the Pharmacological Basis of Therapeutics, 11th edition; 2006.
- 2 Jung C, Inder WJ. Management of adrenal insufficiency during the stress of medical illness and surgery," Medical Journal of Australia. 2008;188(7):409–413.
- 3 Textbook of Physiology by Guyton & Hall, 2nd edition.
- 4 Black RL, Oglesby RB, Von Sallmann L, Bunim JJ. Posterior subcapsular cataracts induced by corticosteroids in patients with rheumatoid arthritis. JAMA. 1960;174:166–71.
- 5 Black R, Hill C, Lester S, Dixon W. The Association between Systemic Glucocorticoid Use and the Risk of Cataract and Glaucoma in Patients with Rheumatoid Arthritis: A Systematic Review and Meta-Analysis. PLOS ONE. 2016; 11(11):e0166468
- 6 Daniel BS, Orchard D. Ocular side-effects of topical corticosteroids: What a dermatologist needs to know. Australas J Dermatol. 2015;56(3):164-9.

© 2022 Pandey et al.; This is an Open Access article distributed under the terms of the Creative Commons Attribution License (<http://creativecommons.org/licenses/by/4.0>), which permits unrestricted use, distribution, and reproduction in any medium, provided the original work is properly cited.

*Peer-review history:*

*The peer review history for this paper can be accessed here:*  
<https://www.sdiarticle5.com/review-history/83529>