

Labs, Signs, History-unravelling the TORCH Mystery!

Priyanka Gandhi ^{a*#}, Sayali Amberkar ^{b≡} and Reshma Ramakrishnan ^{c∞}

^a Department of Ophthalmology, MGM institute of Medical Sciences, Navi Mumbai, India.

^b Department of Ophthalmology, MS Ophthalmology, MGM institute of Medical Sciences, Navi Mumbai, India.

^c Department of Ophthalmology, DNB Ophthalmology, MGM institute of Medical Sciences, Navi Mumbai, India.

Authors' contributions

This work was carried out in collaboration among all authors. All authors read and approved the final manuscript.

Article Information

Open Peer Review History:

This journal follows the Advanced Open Peer Review policy. Identity of the Reviewers, Editor(s) and additional Reviewers, peer review comments, different versions of the manuscript, comments of the editors, etc are available here: <https://www.sdiarticle5.com/review-history/83891>

Received 12 November 2021

Accepted 07 January 2022

Published 10 January 2022

Case Report

ABSTRACT

TORCH infections have variable clinical presentation and are caused by various organisms. A 29 y/F came with chief complaint of sudden and painless diminution of vision in right eye(RE) since 2 months when she was pregnant. She gave history of intrauterine fetal death one month back. Distant visual acuity was 6/36 in RE and 6/36 in the left eye (LE). Posterior segment examination revealed vitritis, resolving subhyaloid bleed anterior to macula, patch of retinochoroiditis along inferior arcade with exudates at macula and early macular star in RE. The labs showed reactive Toxoplasma IgG and IgM, CMV IgG reactive and HSV 1 and 2 IgG positive. At follow up, posterior segment of RE revealed significant resolution of retinal pathology. Therefore, TCH infections should be ruled out in a reproductive aged female presenting with unilateral blurring of vision.

Keywords: TORCH; IUFD; blurring of vision.

[#] Junior Resident;

[≡] Senior Resident;

[∞] Associate Professor;

*Corresponding author: E-mail: phgandhi28@gmail.com;

1. INTRODUCTION

Causative organisms of TORCH infections comprise toxoplasma gondii, treponema pallidum, hepatitis B virus, rubella virus, cytomegalovirus, and herpes simplex virus (HSV). These include Toxoplasmosis, Others: Hepatitis B, Syphilis, Rubella, Cytomegalovirus(CMV) and herpes simplex respectively. Maternal predisposing factors include incomplete or lack of immunizations, sexually transmitted infections and animal exposures during pregnancy [1]. Ocular manifestations of these infections include diminution of vision, metamorphopsia, floaters caused as a result of retinal lesions. These cases may escape detection and to emphasize its early diagnosis and role of preventive measures, we report a case of 29y/Female with history of intrauterine fetal death and unilateral blurred vision who underwent incomplete antenatal checkups and was not diagnosed until she developed visual complaints.

Key points/Highlights: 1. Never miss history especially in female patients of child bearing age group presenting with blurring of vision.

2. Routine TORCH screening tests in antenatal checkup centres are necessary to prevent its complications.

2. CASE HISTORY

A 29 years old female presented to Ophthalmology outpatient department with chief

complaint of sudden and painless diminution of vision in right eye since 2 months. On detailed history taking, she gave history of experiencing the above complaints when she was in third trimester of pregnancy (2 months back). She had a full term normal vaginal delivery with intrauterine fetal death(IUFD). There was no history of retroviral disease, TORCH infections and heavy weight lifting. She had two previous live births, uneventful. On complete ophthalmic evaluation, visual acuity was 6/36 improving to 6/18 in the right eye (RE) and 6/36 improving to 6/9p in the left eye (LE). Anterior segment of both eyes was within normal limits. On posterior segment examination, RE showed vitritis, subhyaloid bleed inferior to fovea, patch of retinochoroiditis about 1DD along inferior arcade with exudates at macula and early macular star formation (Fig. 1) and LE was within normal limits.

Patient was advised to get TORCH workup, Venereal disease research laboratory test, Rapid plasma reagin test, Erythrocyte sedimentation rate, Complete blood count, HIV, HbsAg, HCV, Chest Xray and Mantoux test. The labs showed reactive Toxoplasma IgG and IgM, CMV IgG reactive and HSV 1 and 2 IgG positive. Patient was referred to the physician for further management of underlying etiological conditions. Patient was started on oral Valgancyclovir 500mg for 15 days. Regular follow up was advised and retinal pathology was observed with nil ophthalmologic intervention.

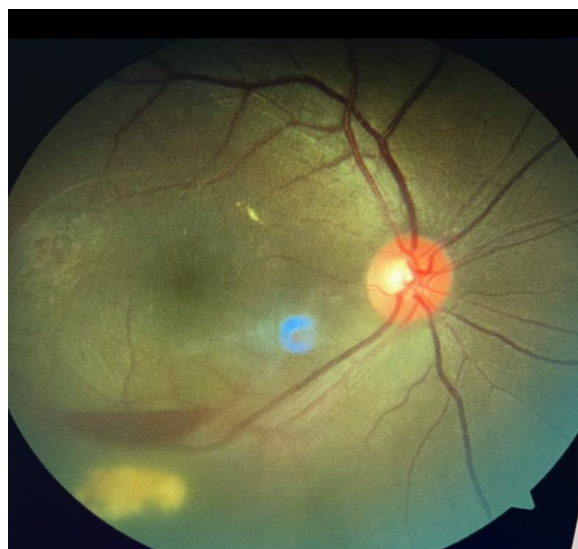

Fig. 1. Posterior segment of right eye showing vitritis, subhyaloid bleed inferior to fovea, patch of retinochoroiditis about 1DD along inferior arcade with exudates at macula and early macular star were noted in right eye

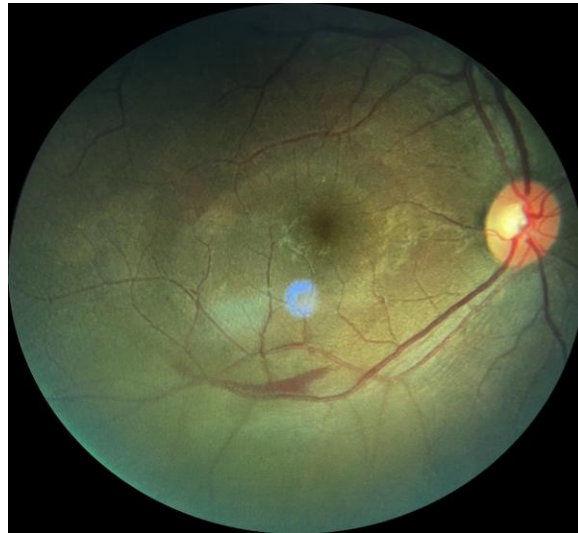


Fig. 2. At follow up after 2 months, posterior segment of right eye showed resolution of active patch of retinochoroiditis with significant decrease in subhyaloid bleed leaving a remnant small retinal haemorrhage

At follow up after 2 months, patient was symptomatically better. Visual acuity was noted as 6/12p improving to 6/12 in right eye and a drastic improvement in the retinal pathology seen as complete resolution of active patch of retinochoroiditis and vitritis with significant decrease in subhyaloid bleed leaving a remnant small retinal haemorrhage. (Fig. 2).

3. DISCUSSION

Causative organisms of TORCH infections comprise *Toxoplasma gondii*, rubella virus, cytomegalovirus, HSV 1 and 2, hepatitis B virus, HIV, and others like syphilis, etc. Routes of transmission of these pathogens may occur prenatally or perinatally by the transplacental route and by blood or vaginal secretions respectively. Proper immunization of mothers helps to prevent Rubella and varicella [2]

Toxoplasmosis is often subclinical and has variable clinical presentation. Patient may remain asymptomatic or present with symptoms like episodes of minimal inflammation, multiple recurrences of severe uveitis, visual impairment, etc. Retinochoroiditis is an apparent evidence of toxoplasmic infection which may present with severe corollary, including complete loss of vision [3]. A typical retinochoroiditis lesion is focal and necrotizing in nature associated with vitreous reaction and healed satellite lesion, in cases of recurrent attack. About 1 to 4 in 100 women (1 to 4 percent) have CMV during pregnancy. Maternal CMV infections during

pregnancy are usually not clinically recognized and universal maternal screening for CMV infection is not recommended. There are no accessible wide-ranging programs that allow both neonatal or maternal screening to detect TORCH infections. There are no vaccines or safe therapies available for prevention of infection and treatment of maternal or fetal CMV infection [4]. For proper diagnosis and evaluation of TORCH infections, a key area of investigation is a detailed maternal history. Risk factors for toxoplasmosis include exposure to cats and the ingestion of undercooked meat or unpasteurized dairy products [5]. During the first trimester, febrile illness, poor maternal weight gain, fetal abnormalities or fetal loss can occur. Low birth weight, rashes, microcephaly, findings suggestive of cardiac abnormalities cataracts, chorioretinitis, etc may be seen on physical examination. Since the maternal infection is predominantly asymptomatic (80% cases), the infection often remains unrecognized [6].

Early *in utero* diagnosis and maternal education is very important to detect TORCH infection. Preconceptional screening for TORCH infections could permit a correct interpretation of serological and virological tests and prevention of its complications. Prompt management permits treatment during pregnancy (toxoplasmosis and syphilis). Oral or intravenous acyclovir is given prophylactically at delivery (HSV) as it helps to eliminate risk to the newborn. Vision, location and size of lesion and vitreous inflammatory

reaction have been identified as indications for systemic treatment [7].

Fransziska et al conducted a systematic literature search to identify serosurveys on TORCH pathogens in Southeast Asia and concluded that comprehensive serosurveys including general population and pregnant women are required due to paucity of reliable information for several pathogens and low quality of the studies. Creating awareness of the risks posed by TORCH pathogens both in pregnant women and healthcare workers, is the foremost step towards prevention of fetal loss and congenital malformations [8].

There are no large scale programs, vaccines and effective therapies for identification and treatment of maternal or fetal CMV infection [9]. Therefore, the challenge is to incorporate knowledge of the risks and consequences of maternal CMV infection with the goal of preventing CMV infection during pregnancy in medical practice. High risk women should be identified and provide them with information on maternal and congenital CMV infection and instructions to decrease the risk of infection [10].

Our patient had gone for few antenatal checkups irregularly at a rural centre. She had got sonography done to assess the fetal status once during pregnancy but no blood investigations were done. Even after IUFD, she was not tested for any probable infective causes. The patient presented to us after 2 months with visual complaints and retinal pathology. Laboratory tests were done. Following which it was known that she was suffering from TORCH infections. This shows lack of routine TORCH screening tests in antenatal checkup centres and its impact on visual morbidity. If she had been thoroughly investigated earlier, early management could have prevented the loss of vision. Hence, it is necessary to create awareness in rural centres and patients about the importance of routine antenatal TORCH screening tests to prevent fetal and maternal complications.

4. CONCLUSION

Never miss history especially in female patients of child bearing age group presenting with blurring of vision. Also, they should be tested routinely for these infections to deliver early detection, intervention and prevention of TORCH infections.

CONSENT

As per international standard or university standard, patients' written consent has been collected and preserved by the author(s).

ETHICAL APPROVAL

As per international standard or university standard written ethical approval has been collected and preserved by the author(s).

COMPETING INTERESTS

Authors have declared that no competing interests exist.

REFERENCES

1. Jaan A, Rajnik M. TORCH Complex. In: StatPearls [Internet]. Treasure Island (FL): StatPearls Publishing; 2021. PMID: 32809363.
2. Singh L, Mishra S, Prasanna S, Cariappa MP. Seroprevalence of TORCH infections in antenatal and HIV positive patient populations. *Med J Armed Forces India*. 2015;71(2):135-8. [PMC free article] [PubMed] [Reference list]
3. Carvalho AGMA, Lima JS, Lima MSPR, Mota CAX. Diagnóstico laboratorial da toxoplasmose congênita. *Rev. Ciênc. Saúde Nova Esperança*. 2014;12:88-95.
4. Grant GB, Desai S, Dumolard L, Kretsinger K, Reef SE. Progress toward rubella and congenital rubella syndrome control and elimination – Worldwide, 2000-2018. *MMWR Morb Mortal Wkly Rep*. 2019;68(39):855-859. [PMC free article] [PubMed][Reference list]
5. Rehman F, Shah M, Ali A, Ahmad I, Sarwar MT, Rapisarda AMC, Cianci A. Unpasteurised milk consumption as a potential risk factor for toxoplasmosis in females with recurrent pregnancy loss. *J Obstet Gynaecol*. 2020;40(8):1106-1110. [PubMed]
6. Kagan KO, Hamprecht K. Cytomegalovirus infection in pregnancy. *Arch Gynecol Obstet*. 2017;296(1):15-26. DOI: 10.1007/s00404-017-4380-2. Epub 2017 May 15. PMID: 28508343.
7. Holland GN, Lewis KG. An update on current practices in the management of

- ocular toxoplasmosis. Am J Ophthalmol. 2002;134:102–114.
[PubMed] [Google Scholar]
8. Fuchs FE, Pauly M, Black AP, Hübschen JM. Seroprevalence of ToRCH pathogens in Southeast Asia. Microorganisms. 2021;9:574.
Available:<https://doi.org/10.3390/microorganisms9030574>
9. Lazzarotto T, Blázquez-Gamero D, Delforge ML, Foulon I, Luck S, Modrow S, Leruez-Ville M. Congenital cytomegalovirus infection: A narrative review of the issues in screening and management from a panel of european experts. Front Pediatr. 2020;8:13.
[PMC free article] [PubMed]
10. Pass RF, Arav-Boger R. Maternal and fetal cytomegalovirus infection: Diagnosis, management, and prevention. F1000Res. 2018;7:255.
DOI: 10.12688/f1000research.12517.1.
PMID: 29560263; PMCID: PMC5832908

© 2022 Gandhi et al.; This is an Open Access article distributed under the terms of the Creative Commons Attribution License (<http://creativecommons.org/licenses/by/4.0>), which permits unrestricted use, distribution, and reproduction in any medium, provided the original work is properly cited.

Peer-review history:
The peer review history for this paper can be accessed here:
<https://www.sdiarticle5.com/review-history/83891>