

## Is Portable Cardiopulmonary Ultrasound the Future of Heart Failure Diagnosis?

EL Mousaid Meriem <sup>a\*</sup>, Errami Amine <sup>a</sup>, Couissi Abdessamad <sup>a</sup>,  
Haboub Meryem <sup>a</sup> and Habbal Rachida <sup>a</sup>

<sup>a</sup> Cardiology Department, University Center Hospital, Casablanca, Morocco.

### Authors' contributions

*This work was carried out in collaboration among all authors. All authors read and approved the final manuscript.*

### Article Information

DOI: 10.9734/CA/2022/v11i4305

### Open Peer Review History:

This journal follows the Advanced Open Peer Review policy. Identity of the Reviewers, Editor(s) and additional Reviewers, peer review comments, different versions of the manuscript, comments of the editors, etc are available here: <https://www.sdiarticle5.com/review-history/94656>

**Original Research Article**

**Received 12 October 2022**  
**Accepted 19 December 2022**  
**Published 24 December 2022**

### ABSTRACT

**Aim of the Study:** Heart failure is a major problem of public health in Morocco, pulmonary congestion is a key sign which can be easily detected by pulmonary sonography via interlobular septal thickening.

The aim of this study was to establish a link between Kerley B lines in the lung and signs of pulmonary congestion. In addition to assess the evolution of these parameters in response to diuretic treatment.

**Materials and Methods:** We prospectively evaluate 118 patients who presented to the emergency of IBN Rochd Hospital in Casablanca with sensation of breathlessness at baseline, 7 days, one month and 3 months for Kerley B lines, NYHA Class of dyspnea and the levels of NT pro bnp. The duration of this study was 4 months.

**Results:** Kerley B lines were present in 87.4% of patients initially, 67.6% had elevated levels of NT-proBNP and 53%, 30%, 16% had dyspnea Class II, III and IV respectively. Diuretic treatment has shown a similar improvement of Kerley B lines, levels of NT pro bnp and the class of dyspnea. In deed after a follow up of 3 months: only 7% of patients had persistent Kerley B lines, NT pro bnp levels were high in only 7.6% these findings were concordant with the clinical symptomatology. Hence only 7% of our patients suffered from dyspnea at moderate efforts at the end of the study.

**Conclusion:** We demonstrated in this study a positive correlation between Kerley B lines and levels of NT pro-bnp. These findings may facilitate the orientation of patients within the emergency department and help to initiate heart failure treatment rapidly.

\*Corresponding author: E-mail: meryelmousaid@gmail.com;

**Keywords:** Pulmonary sonography; kerley B lines; NYHA class; NT pro bnp.

## ABBREVIATIONS

<i>B</i>	: Brain natriuretic peptide
<i>D</i>	: Day
<i>LA</i>	: Left atrial
<i>LVEF</i>	: Left ventricular ejection fraction
<i>NYHA</i>	: New-York Heart Association
<i>NT pro BNP</i>	: N-terminal pro b-type natriuretic peptide

## 1. INTRODUCTION

For the last twenty years, ultrasound has been the object of renewed interest for pulmonary exploration in the broad sense. The need to have access to a rapid means of exploration at the patient's bedside in critical situations has led to the development of pleuropulmonary ultrasound, making it a diagnostic tool of choice whose use now extends beyond the strict framework of intensive care units and emergency services [1]. Pulmonary ultrasound is readily available at the bedside, without risk of radiation and in real time. In addition, it has been shown to be superior to bedside chest radiography and equal to chest CT in the diagnosis of many pleural and pulmonary pathologies [2]. Its significant advantage is its simplicity, which allows reliable lung ultrasound to be performed in a short period of time (3 minutes on average), at a lower cost (especially in cardiology with the availability of ultrasound machines), with a very rapid learning curve, even for those who are new to ultrasound [3]. With a good correlation between the number of Kerley B lines and the level of NT-pro BNP in patients with heart failure.

It is within this framework that we carried out our study at the Ibn Rochd University Hospital of Casablanca in the cardiology department. The objective of this work was the identification of Kerley's B lines and their correlation to NT- pro BNP, and left atrial volum.

## 2. METHODS

This is a prospective study. We included a total of 118 patients with acute dyspnea in the cardiology department of Ibn Rochd hospital in Casablanca over a period of 4 months. A pulmonary ultrasound was performed in order to detect the cardiac origin of this dyspnea.

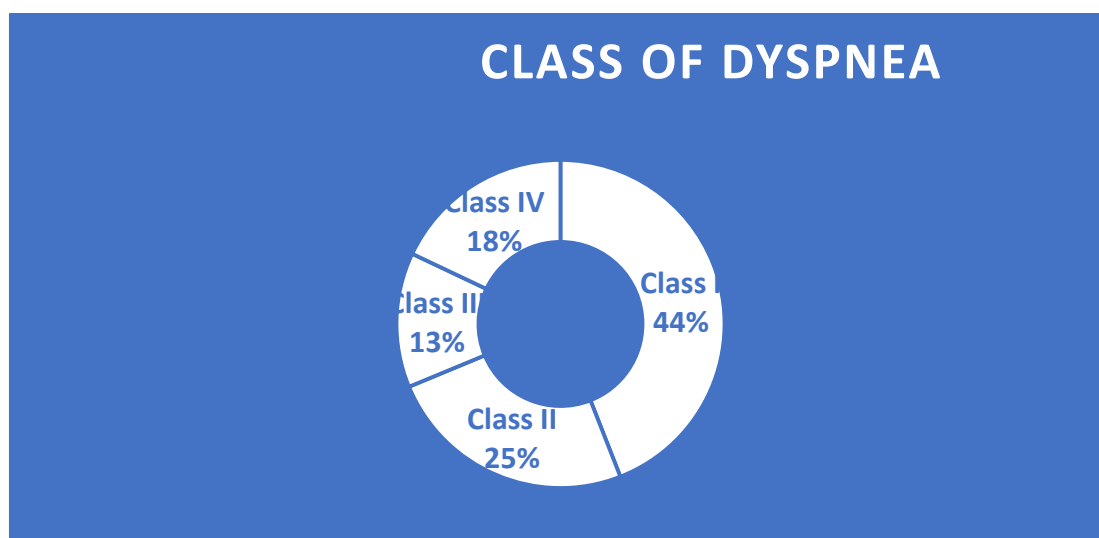
This is a prospective study. We included a total of 118 patients with acute dyspnea and a positive NT-pro BNP level in the cardiology department of Ibn Rochd Hospital in Casablanca over a period of 4 months (from June 2021 to October 2021).

All patients with a negative NT pro BNP level were excluded. A pulmonary ultrasound was performed in order to detect the cardiac origin of this dyspnoea.


## 3. RESULTS

118 patients were recruited from June 2021 to October 2021. 63% were male.

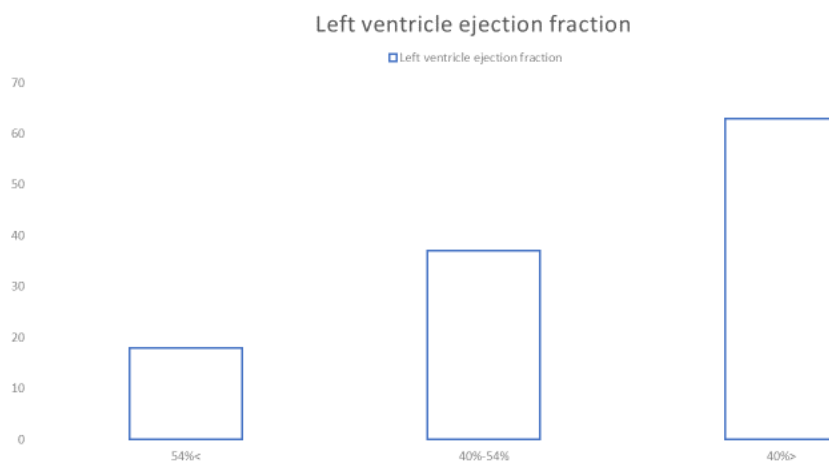
Clinically, 53.7%, 30.1% and 16.2 % of patients had Dyspnea stage II, III and IV respectively (Fig. 1).



**Fig. 1. Class of dyspnea among patients of our study**



**Fig. 2. Left atrial volum among our patients : 20% had LA enlargement (more than 35 ml/m<sup>2</sup>)**



**Fig. 3. Left ventricle ejection fraction among our patients**

On pulmonary ultrasound, B-lines were present at the time of admission in 87.2% of patients.

Biologically, the NT- pro BNP level was clearly positive in 90.6%.

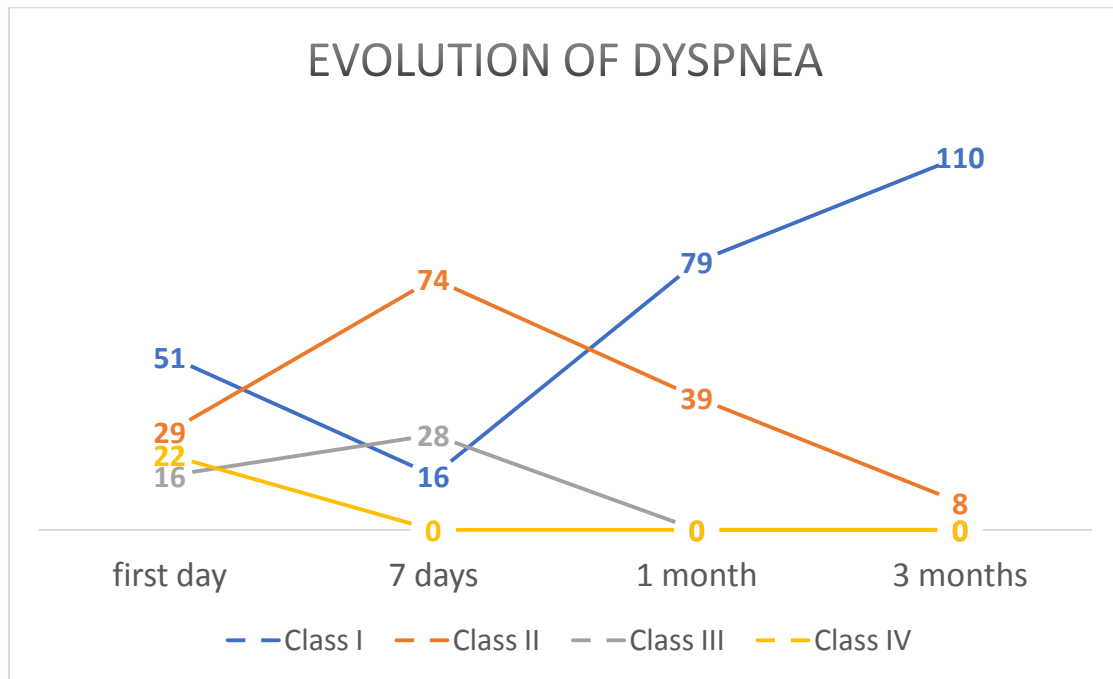
Echocardiographically, 28.6% of patients had a LA volume between 25 and 30 ml/m<sup>2</sup>. 51.9% had a LA volume between 30 and 34 ml/m<sup>2</sup>, and 19.5% of patients had a LA volume greater than or equal to 35 ml/m<sup>2</sup> (Fig. 2).

77.8% of patients had left ventricular hypertrophy on echocardiography.

15% of patients had preserved LVEF, 31% of patients had moderately reduced LVEF, and 54% of patients had impaired LVEF (Fig. 3).

After a 7-day follow-up, 14% of patients had NYHA stage I dyspnea, 63% had NYHA stage II dyspnea, and 23% of patients had NYHA stage III dyspnea, BNP was positive in 66% of patients. B-lines were present in 55% of patients. Diuretic dosage was increased in 71% of patients, maintained in 21% of patients and decreased in 8% of patients (Fig. 4).

After a 30-day follow-up, 67% of patients had NYHA stage I dyspnea and 33% of patients had



**Fig. 4. Evolution of dyspnea during the time of our study , diuretics have improved significantly the symptoms , at the end of the study most of patients presented dyspnea Class I**

NYHA stage II dyspnea. 50% of patients had a positive BNP level. B-lines were present in 32% of patients.

At a 3-month follow-up, 93% of patients had NYHA stage I dyspnea and 7% of patients had NYHA stage II dyspnea. 12.7% of patients had a positive BNP level.

The Pearson correlation between B-lines at admission and dyspnea severity, OG volume, LV mass, LVEF, NT pro-BNP level, diuretic dosage was 0.286 (p=0.016), 0.355 (p=0.003), 0.182 (p=0.137), 0.454 (p=0.001), 0.319 (p=0.024) and 0.514 (p=0.003), respectively.

The Pearson correlation between B-lines at D7 follow-up and dyspnea severity and BNP level was 0.273 (p=0.027) and 0.238 (p=0.086), respectively.

The Pearson correlation between B-lines at D30 follow-up and dyspnea severity and BNP level was 0.175 (p=0.263) and 0.452 (p=0.04), respectively.

The Pearson correlation between B-lines at D90 follow-up and dyspnea severity and BNP level was 0,09 (p =0,003) and 0,12 (p =0,001) respectively.

#### 4. DISCUSSION

In our study, there is a positive correlation between the presence of B-lines at the time of admission and the NYHA stage of dyspnea, NT-pro BNP level and diuretic dosages. Also, there was a negative correlation between LVEF value and the presence of B lines. This positive correlation between B-lines remained positive between NYHA stage and BNP level after 7 days and 30 days of progression.

B-lines have been proposed as a reliable alternative diagnostic tool for the assessment and grading of pulmonary congestion in patients with acute heart failure [4]. Prosen et al. [5] demonstrated that pulmonary ultrasound can differentiate cardiac dyspnea from pulmonary dyspnea, primarily when combined with BNP, observing an increase in diagnostic sensitivity and specificity for the combination of UP and BNP.

A systematic review with meta-analysis of 6 prospective cohort studies representing 1827 patients compared the diagnostic accuracy of portable cardiothoracic ultrasound (or PoCUS for point-of-care ultrasonography) with chest radiography in adults with symptoms of acute decompensated heart failure. Pulmonary

ultrasound was more sensitive than chest radiography in detecting cardiogenic pulmonary edema and had comparable specificity [6]. Also, according to the same review PoCUS ultrasound was clinically useful in identifying the presence and distribution of comet-tail artifacts (B-lines, indicative of pulmonary interstitial fluid) and in confirming a diagnosis of heart failure (positive RV 8.8, negative RV 0.13) A 2015 observational study [7]. directly compared the commonly used mixed diagnostic approach (ie. i.e., clinical examination, serum NTproBNP assay, and chest radiograph) to PoCUS cardiopulmonary ultrasound alone (i.e., no clinical examination) in patients who consulted for acute dyspnea. PoCUS cardiopulmonary ultrasound was more accurate than the mixed approach for the diagnosis of acute left heart failure and required only about 12 minutes at the bedside. In addition, pulmonary ultrasound adds value to neuropeptides [brain natriuretic peptide (BNP) and NTpro-BNP] for diagnosis, prognosis, and treatment of patients with decompensated CHF [5]. Miglioranza et al. [8] reported that a B-line number  $\geq 15$  correlates with NT-proBNP  $> 1000$  ( $p < 0.001$ ), E/e' ratio  $> 15$  ( $p = 0.001$ ) and clinical assessment ( $p < 0.001$ ), with a sensitivity of 85% and specificity of 83%, for the risk of decompensated CI.

Numerous other studies have shown its correlation to affirm the diagnosis of pulmonary edema with echocardiographic elements such as the E/A ratio in pulsed Doppler at the mitral annulus [9], the E/e' ratio [8], In the study of Platz et al. [10] there was a correlation with left ventricular (LV) end-diastolic diameter (EDD -  $p = 0, 036$ ) and LV telesystolic diameter ( $p = 0.026$ ), with septal wall thickening ( $p = 0.009$ ), LV mass index ( $p = 0.001$ ), left atrial volume index ( $p = 0.005$ ), tricuspid valve regurgitation velocity ( $p = 0.005$ ) and systolic pulmonary artery pressure (SPAP,  $p = 0.003$ ). In addition, according to the study by Agricola E et al. [11], there was a correlation between mean pulmonary capillary pressure measured by cardiac catheterization and type B lines.

In addition to their diagnostic value, type B lines are an important prognostic tool. Platz et al. [12] demonstrated that the one-third of patients with the most B-lines, measured with a portable ultrasound scanner, had a four-fold increased risk of hospitalization and all-cause mortality (HR = 4.08) compared with the one-third of patients with the fewest B-lines. Among the highest-risk third, 81% of patients had normal lung

auscultation, confirming the added value of this examination over clinical examination. Gustafsson et al. [13] identified that the presence of B lines or pleural effusion or both correlated with increased risk of death or hospitalization (HR: 3-4;  $p < 0.05$ ).

According to the study by Francesca Frassi et al. [9] event-free survival at 16 months was highest in patients without comet tails and lowest in patients with more than 30 comet tails at entry (70% versus 19%,  $P = 0.0007$ ). Same finding in the studies by Gargani et al. [14] and Corio et al. [15], who found a prognostic value at discharge for the number of B lines  $\geq 30$  and  $\geq 15$ , respectively, for all-cause death or event-free hospitalization at 3 and 6 months ( $p < 0.001$  for both).

Pulmonary ultrasound can also be a complement in the therapeutic follow-up. According to Volpicelli et al. [16] Type B lines usually disappear after adequate medical treatment for heart failure.

## 5. CONCLUSION

we demonstrated in this study a positive correlation between kerley b lines and levels of NT pro-bnp . These findings may facilitate the orientation of patients within the emergency department and help to initiate heart failure treatment rapidly.

## CONSENT

As per international standard or university standard, patient(s) written consent has been collected and preserved by the author(s).

## ETHICAL APPROVAL

As per international standard or university standard written ethical approval has been collected and preserved by the author(s).

## COMPETING INTERESTS

Authors have declared that no competing interests exist.

## REFERENCES

1. Black L, Nicod LP. Pleuropulmonary ultrasound for the pulmonologist. *Swiss Medical Rev.* 2017;13(583):1990-5.

2. Saraogi A. Lung ultrasound: Present and future. Lung India off Organ Indian Chest Soc. 2015;32(3):250-7.
3. Usefulness of lung ultrasound for the cardiologist [Internet]. Practical Cardiology; 2017 [cited 2022 Jul 15]. Available: <https://www.cardiologie-pratique.com/journal/article/0026579-utilite-lechographie-pulmonaire-cardiologue>
4. Ricci F, Aquilani R, Radico F, Bianco F, Dipace GG, Miniero E, et al. Role and importance of ultrasound lung comes in acute cardiac care. Eur Heart J Acute Cardiovascular Care. 2015 Apr 1;4(2): 103-12.
5. Prosen G, Klemen P, Strnad M, Grmec Š. Combination of lung ultrasound (a comet-tail sign) and N-terminal pro-brain natriuretic peptide in differentiating acute heart failure from chronic obstructive pulmonary disease and asthma as cause of acute dyspnea in prehospital emergency setting. CritCare. 2011; 15(2):R114.
6. Maw AM, Hassanin A, Ho PM, McInnes MDF, Moss A, Juarez-Colunga E, et al. Diagnostic accuracy of point-of-care lung ultrasonography and chest radiography in adults with Symptoms suggestive of acute decompensated heart failure. JAMA Netw Open. 2019 Mar 15;2(3):e190703.
7. Gallard E, Redonnet JP, Bourcier JE, Deshaies D, Largeteau N, Amalric JM, et al. Diagnostic performance of cardiopulmonary ultrasound performed by the emergency physician in the management of acute dyspnea. Am J Emerg Med. 2015 Mar;33(3): 352-8.
8. Miglioranza MH, Gargani L, Sant'Anna RT, Rover MM, Martins VM, Mantovani A, et al. Lung ultrasound for the evaluation of pulmonary congestion in outpatients: a comparison with clinical assessment, natriuretic peptides, and echocardiography. JACC Cardiovascular Imaging. 2013 Nov;6(11):1141-51.
9. Frassi F, Gargani L, Tesorio P, Raciti M, Mottola G, Picano E. Prognostic value of extravascular lung water assessed with ultrasound lung comets by chest sonography in patients with dyspnea and/or chest pain. J Card Fail. 2007 Dec;13(10):830-5.
10. Platz E, Hempel D, Pivetta E, Rivero J, Solomon SD. Echocardiographic and lung ultrasound characteristics in ambulatory patients with dyspnea or prior heart failure. Echocardiogr Mt Kisco N. 2014 Feb;31(2):133-9.
11. Agricola E, Bove T, Oppizzi M, Marino G, Zangrillo A, Margonato A, et al. "Ultrasound comet-tail images": a marker of pulmonary edema: a comparative study with wedge pressure and extravascular lung water. Chest. 2005 May;127(5):1690-5.
12. Platz E, Lewis EF, Uno H, Peck J, Pivetta E, Merz AA, et al. Detection and prognostic value of pulmonary congestion by lung ultrasound in ambulatory heart failure patients. Eur Heart J. 2016 Apr 14;37(15):1244-51.
13. Gustafsson M, Alehagen U, Johansson P. Imaging congestion with a pocket ultrasound device: Prognostic implications in patients with chronic heart failure. J Card Fail. 2015 Jul;21(7):548-54.
14. Gargani L, Pang PS, Frassi F, Miglioranza MH, Dini FL, Landi P, et al. Persistent pulmonary congestion before discharge predicts rehospitalization in heart failure: a lung ultrasound study. Cardiovascular Ultrasound. Sep 4, 2015;1:40 p.m.
15. Coiro S, Rossignol P, Ambrosio G, Carluccio E, Alunni G, Murrone A, et al. Prognostic value of residual pulmonary congestion at discharge assessed by lung ultrasound imaging in heart failure. Eur J Heart Fail. 2015 Nov;17(11):1172-81.
16. Volpicelli G, Caramello V, Cardinale L, Mussa A, Bar F, Frascisco MF. Bedside ultrasound of the lung for the monitoring of acute decompensated heart failure. Am J Emerg Med. 2008 Jun;26(5):585-91.

© 2022 Meriem et al.; This is an Open Access article distributed under the terms of the Creative Commons Attribution License (<http://creativecommons.org/licenses/by/4.0>), which permits unrestricted use, distribution, and reproduction in any medium, provided the original work is properly cited.

Peer-review history:

The peer review history for this paper can be accessed here:  
<https://www.sdiarticle5.com/review-history/94656>