



Comparison between Partial versus Complete Excision of Sublingual Gland in Plunging Ranula Management (A Clinical Study)

Agha Taj Mohammad ^a, Jamshed Bashir ^b, Mukhtar Ibrahim Singapuri ^c,
Bushra Tasneem ^d, Rasool Bux Behan ^a and Syed Ghazanfar Hassan ^{e*}

^a General Surgery Department, Liaquat University of Medical and Health Sciences, Pakistan.

^b General Surgery Department, Muhammad Medical College, Mirpurkhas, Pakistan.

^c Otolaryngology (ENT) Department, Indus Medical College, Tando Muhammad Khan, Pakistan.

^d General Surgery Department, Abbasi Shaheed Hospital, Karachi, Pakistan.

^e Department of Oral and Maxillofacial Surgery, Faculty of Dentistry, Liaquat University of Medical and Health Sciences, Pakistan.

Authors' contributions

This work was carried out in collaboration among all authors. All authors read and approved the final manuscript.

Article Information

DOI: 10.9734/JPRI/2022/v34i36A36181

Open Peer Review History:

This journal follows the Advanced Open Peer Review policy. Identity of the Reviewers, Editor(s) and additional Reviewers, peer review comments, different versions of the manuscript, comments of the editors, etc are available here: <https://www.sdiarticle5.com/review-history/86846>

Original Research Article

Received 22 February 2022

Accepted 29 April 2022

Published 03 May 2022

ABSTRACT

Objective: To compare the postoperative complications of complete versus partial excision of the sublingual gland (SLG) in the management of plunging ranula.

Subject and Methods: A total of 24 patients were equally divided into two groups; Group A was treated with partial excision, while Group B was treated with Complete excision. . CT and MRI were used to diagnose the lesions. Postoperatively, complications like pain, hematoma, and temporary numbness of tongue, dysgeusia, dysphagia and recurrence were recorded.

Results: In both groups, males were in majority as compared to females. 10 males and 2 females, 9 males and 3 females were reported in Group A and B respectively. Mean age of patients in group A was 22.34±3.61, while in group B it was 21.25±3.55. Nearby 25% recurrence rate was found in patients treated with partial excision of SLG, while none of the patient reported with recurrence in complete excision group.

*Corresponding author: E-mail: chairman_oral@hotmail.com;

Conclusion: Complete excision of sublingual gland was found superior management modality as compared with partial excision in terms of postoperative recurrence.

Keywords: Plunging Ranula; partial excision; complete excision; sublingual gland, recurrence.

1. INTRODUCTION

A plunging ranula is a herniated cyst that appears as a bulge in the upper region of the neck and is placed beneath the mylohyoid muscle [1]. Cervical ranula, diving ranula, deep ranula, and oral ranula with cervical extension are some of the other terms for this condition [2].

Although the specific incidence of plunging ranula is unknown, these lesions are thought to be infrequent. It is not hard to determine a plunging ranula since most of them are linked with a bulge in the floor of the mouth or a background of intraoral ranula treatments [3].

Plunging ranulas are most commonly seen in the presence of an oral ranula. They only seldom occur without the oral component. The clinical assessment of ranula may not be considered if there is no mouth swelling. The patient's first symptom is an oral edema in up to 45% of instances. Approximately 21% of the instances have no oral participation at all [4].

One of the preceding four methods causes plunging ranulas in the neck. To begin, the sublingual gland may protrude from the mylohyoid, or an ectopic sublingual gland may occur on the cervical side of the mylohyoid. This describes the vast majority of plunging ranulas that do not include an oral aspect. Second, there may be a dehiscence or hiatus in the mylohyoid muscle. The lateral portion of the anterior two-thirds of the muscle shows this abnormality. Mucin from the sublingual gland may enter the submandibular space through this defect. Third, about 45 % of plunging ranulas arise as a result of iatrogenically performed operation to excise oral ranulas. Surgical techniques for sialolith removal, duct transposition, and an implantation have also been linked to the creation of plunging ranulas [5]. Finally, a duct from the sublingual gland may connect to the submandibular gland or its duct, permitting ranulas to grow alongside the submandibular gland [6,7].

Various therapeutic strategies have been used relying on different aetiology beliefs. Simple ranula excision, cyst extirpation, excision of the sublingual gland, and sclerotherapy of the ranula

sac are all common ranula treatments [8,9]. Excision of the sublingual gland has been the primary therapeutic choice for plunging ranula, with sclerotherapy as a less invasive alternative. The sublingual gland has lately been thought to be a viable therapy option.

Partial or complete removal of the sublingual gland are more successful options for the treatment of plunging ranulas [10]. These surgical modalities are often associated with known complications such as infection, bleeding, hematoma formation and paresthesia of the tongue. Injury to the submandibular duct and recurrence are common complications [11].

The study's main goal was to assess the clinical results of total versus partial SLG excision for plunging ranula.

2. MATERIALS AND METHODS

This comparative cross sectional study was carried out jointly at General and Maxillofacial Surgery units of Liaquat University hospital Hyderabad/Jamshoro from January 2017 to December 2021 after permission of research ethics committee of the university. A total of 24 diagnosed patients of plunging ranula were randomly divided to into two groups as follows:

Group A: Treated with Partial Excision of Sublingual Gland (12 Patients)

Group B: Treated with Complete Excision of Sublingual Gland (12 Patients)

The research comprised patients of either genders between the ages of 18 and 50 who needed sublingual gland removal with cystic material evacuation for plunging ranula. Individuals with previous surgery for ranula or sclerotherapy, and who do not agree for surgical treatment have been excluded. Contrast-enhanced computed tomography (CT) or magnetic resonance imaging (MRI) were used to locate the lesions, and cystic fluid was aspirated for differential diagnosis.

3. PROCEDURE

Under general anaesthesia, a Bovie electrode and fine-needle tip were used to make an incision across the sulcus between the movable tongue and the floor of mouth. The SLG was separated and retracted anteriorly with the incision area. The Wharton's duct's distal section and aperture were initially found and meticulously dissected posteriorly to the hilum without causing harm. The lingual nerve was also discovered and kept with attention. In the total excision sample, all sections of the SLG on the afflicted side were removed, whereas in the partial excision group, just the part of the SLG with extension to the plunging ranula was excised while the rest of the SLG was preserved. The mylohyoid muscle defect that causes plunging ranula was expanded and the cystic substance of ranula was emptied after total or partial SLG resection. The incision was sealed with absorbable stitches, but the midsection was left open to allow wound drainage to leak into the mouth cavity. After operation, on discharge from hospital the patient was given oral antibiotics as a preventative measure for 5 days.

Postoperative findings like pain (assessed by Visual Analog Scale), hematoma, and temporary

numbness of tongue, temporary dysgeusia and dysphagia were recorded. Physical examinations and occasional CT or MRI imaging studies were used to evaluate postoperative recurrence for up to a year to evaluate postoperative recurrence.

4. RESULTS

A total of 24 patients, divided into two groups of 12 in each were assessed. Group A was treated by partial excision and Group B by complete excision of sublingual gland.

In both groups males were mainly reported as compared to females. 10 out 12 and 9 out 12 were males in group A and B respectively. Fig. 1 demonstrates male and female count in both groups.

Mean age of patients in group A was 22.34 ± 3.61 , while in group B it was 21.25 ± 3.55 , as shown in Table 1.

Minor postoperative complications were encountered but all of them resolve with time. The details about complications like pain, hematoma, temporary numbness of tongue, dysgeusia, and dysphagia are shown in Table 2.

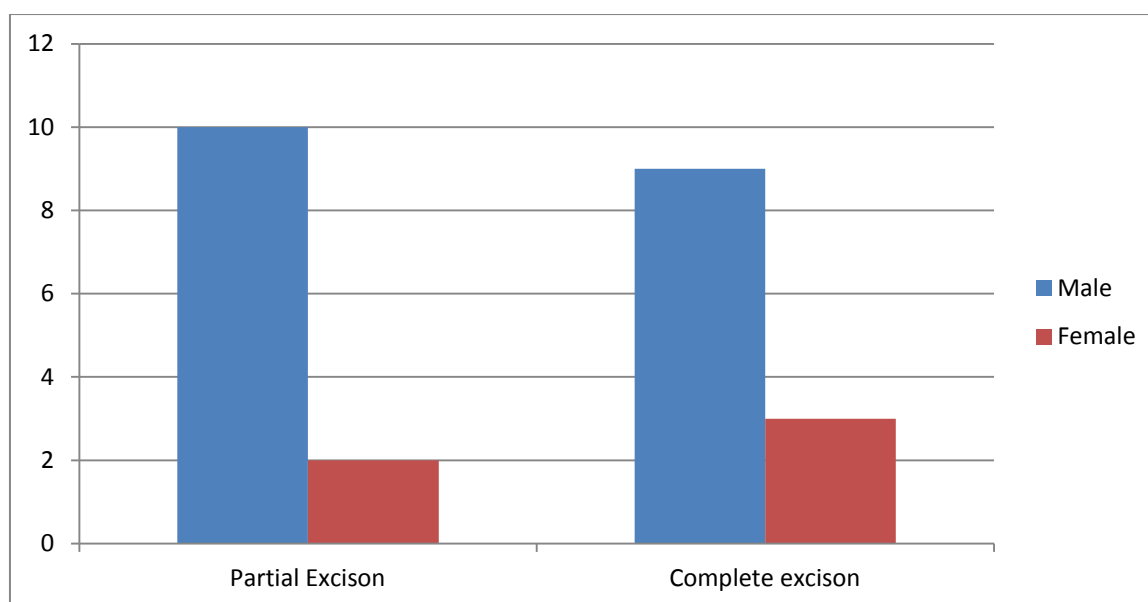


Fig. 1. Showing male to female ratio

Table 1. Descriptive statistics of age

VARIABLE	Partial Excision	Complete Excision
AGE (Mean \pm SD)	22.34 ± 3.61	21.25 ± 3.55

Table 2. Frequency of postoperative complications

Complications	Partial Excision (n=12)	Complete Excision (n=12)
Postoperative Pain	07	04
Hematoma	02	00
Temporary Numbness of Tongue	01	01
Temporary Dysgeusia	01	00
Temporary Dysphagia	01	01
Recurrence	03	00

5. DISCUSSION

For adult intraoral ranulas, marsupialization with or without gauze packing, excision of ranula with total excision of the sublingual gland, or ranula excision with partial excision of the sublingual gland are surgical treatment options [12].

Plunging ranulas can be efficiently managed by transorally eliminating the sublingual gland and emptying the extravasated mucus [13]. The worst efficacy rates were 38%, 55%, 38%, and 4%, respectively, for ranula excision alone, SLG + ranula excision, marsupialization, and incision and drainage. Sclerotherapy with OK-432 intracystic injection was successful in 59% of cases. Therefore, excision of the afflicted SLG is suggested for the efficient therapy for plunging ranula [14].

Our study reported minor postoperative complication like pain, hematoma, temporary numbness of tongue, dysgeusia and dysphagia, but all were subsequently resolved on follow up visits. There was no major disparity among both groups in regard to minor postoperative complications. These findings were statistically in similarity to various others studies like Roh JL [15], Samant S [16] and Chen JX [17]. The main common consequences, according to Zhao et al [18], who researched problems related with the surgical therapy of ranulas, are recurrence of the lesions and numbing of the tongue due to injury to the lingual nerve. Wharton duct injury, haemorrhage, hematoma, wound dehiscence, and infection have all been described. In the marsupialization and excision of the ranula, recurring was common. The removal of the sublingual gland caused the most damage to the surrounding tissue. It's worth noting, meanwhile, that the issues that arose after the ranula was removed were very transitory and disappeared within a short period of time.

In comparison to partial excision, total excision of the afflicted SLG was secure and efficient, with

no severe problems or reappearance. Although the report's follow-up time was too brief to determine the total recurrence rate following surgery, even though enough instances were found reoccurring in the partial excision group. Recurrence rates of superficial ranulas excised with excision without removal of the accompanying glands have been documented to range from 25% to 56.69% [19].

A study carried out by Roh JL [15] reported 5 cases of recurrence when treated with partial excision of gland while no recurrence was found in complete excision group, these findings were in similarity with our study. Similarly no recurrence was mentioned in any patient during the conduction of follow-up after SLG removal in the study carried out by Olejede et al. [20] and Kamlakaran et al. [21].

As a result, in the care of plunging ranula instances, total excision of the sublingual gland has been proposed to reduce recurrence as the most prevalent complication.

6. CONCLUSION

It was concluded that complete excision of sublingual gland was better management modality as compared to partial excision in terms of postoperative recurrence in the management of plunging ranula cases. No difference was found in terms of other minor postoperative complications among both groups.

CONSENT

As per international standard or university standard, patients' written consent has been collected and preserved by the author(s).

ETHICAL APPROVAL

As per international standard or university standard written ethical approval has been collected and preserved by the author(s).

COMPETING INTERESTS

Authors have declared that no competing interests exist.

REFERENCES

1. Lee JY, Lee HY, Kim HJ, et al. Plunging ranulas revisited: A CT study with emphasis on a defect of the mylohyoid muscle as the primary route of lesion propagation. *Korean J Radiol.* 2016;17(2):264-270.
2. de Visscher JG, van der Wal KG, de Vogel PL. The plunging ranula: Pathogenesis, diagnosis and management. *J. Craniomaxillofac. Surg.* 1989;17:182-185.
3. Gupta A, Karjodkar FR. Plunging ranula: A case report. *ISRN Dent.* 2011;806928.
4. Morton RP, Ahmad Z, Jain P. Plunging ranula: Congenital or acquired? *Otolaryngol Head Neck. Surg.* 2010;142(1):104-107.
5. Lida S, Kogo M, Tominaga G, Matsuya T. Plunging ranula as a complication of intraoral removal of a submandibular sialolith. *Br J Oral Maxillofac Surg.* 2001;39(3):214-216.
6. Balakrishnan A, Ford G, Bailey C. Plunging ranula following bilateral submandibular duct transposition. *The Journal of Laryngology & Otology.* 1991;105(8):667-669.
7. Loney Jr WW, Termini S, Sisto J. Plunging ranula formation as a complication of dental implant surgery: A case report. *Journal of Oral and Maxillofacial Surgery.* 2006;64(8):1204-1208.
8. Davison MJ, Morton RP, Mclvor NP. Plunging ranula: Clinical observations. *Head Neck.* 1998;20(1):63-8.
9. Zhi K, Gao L, Ren W. What is new in management of pediatric ranula? *Curr Opin Otolaryngol Head Neck Surg.* 2014;22(6):525-9.
10. Yunsu Y, Kihwan J. Surgical results of the intraoral approach for plunging ranula. *Acta Oto-Laryngologica.* 2014;134: 201-5.
11. Chidzonga MM, Mahova L. Ranula: Experience with 83 cases in Zimbabwe. *J Oral Maxillofac Surg.* 2007;65: 79-82.
12. Yadav R, Tewari V. Ranula, Its Etiopathogenesis and management; A systematic review. *ENT-Updates.* 2021;11(1): 56-61.
13. McGurk M. Management of the ranula. *J Oral Maxillofac Surg.* 2007;65(1):115-6.
14. Harrison JD. Modern management and pathophysiology of ranula: literature review. *Head Neck.* 2010;32(10):1310-1320.
15. Roh JL. Transoral complete vs partial excision of the sublingual gland for plunging ranula. *Otolaryngol Head Neck Surg.* 2021;1945998211067500.
16. Samant S, Morton RP, Ahmad Z. Surgery for plunging ranula: The lesson not yet learned? *Eur Arch Otorhinolaryngol.* 2011;268(10):1513-1518.
17. Chen JX, Zenga J, Emerick K, Deschler D. Sublingual gland excision for the surgical management of plunging ranula. *Am J Otolaryngol.* 2018;39(5):497-500.
18. Zhao YF, Jia J, Jia Y. Complications associated with surgical management of ranulas. *J Oral Maxillofac Surg.* 2005;63(1):51-54.
19. Choi M-G. Case report of the management of the ranula. *J Korean Assoc Oral Maxillofac Surg* 2019;45(6):357-63.
20. Olojede ACO, Ogundana OM, Emeka CI, et al. Plunging ranula: Surgical management of case series and literature review. *Clin Case Rep.* 2017;6:109-114.
21. Kamlakaran A, Jayaraman B, Balasubramanian S, Thirunavukkarasu R, Ramakrishnan B. Plunging ranula in 78 year old male-a rare case report. *J Clin Exp Dent.* 2018;10(1):92-95.

© 2022 Mohammad et al.; This is an Open Access article distributed under the terms of the Creative Commons Attribution License (<http://creativecommons.org/licenses/by/4.0>), which permits unrestricted use, distribution, and reproduction in any medium, provided the original work is properly cited.

Peer-review history:

The peer review history for this paper can be accessed here:
<https://www.sdiarticle5.com/review-history/86846>