



Capability of Hepatic Regeneration of Albino Mice against Hepatic Injuries Induced by Phentolep Drug

Sameena Gul Memon^{1*}, Pashmina Shaikh¹, Fahmida Gul¹ and Tahseen Ahmed²

¹*Department of Anatomy, Liaquat University of Medical and Health Sciences Jamshoro, Sindh, Pakistan.*

²*Institute of Pharmaceutical Sciences, Peoples University of Medical & Health Sciences, Shaheed Benazirabad, Sindh, Pakistan.*

Authors' contributions

This work was carried out in collaboration between all authors. All authors read and approved the final manuscript.

Article Information

DOI: 10.9734/JPRI/2021/v33i38B32118

Editor(s):

(1) Dr. S. Prabhu, Sri Venkateswara College of Engineering, India.

Reviewers:

(1) N. K. Udaya Prakash, Vels Institute of Science, Technology & Advanced Studies (VISTAS), India.

(2) Jony Mallik, Popular Pharmaceuticals Limited, Bangladesh.

Complete Peer review History: <https://www.sdiarticle4.com/review-history/68758>

Original Research Article

Received 01 May 2021

Accepted 03 July 2021

Published 28 July 2021

ABSTRACT

The major theme of our research was to evaluate the condition of the regenerative capacity of liver with proper consumption of phenytoin medicines with proper precautionary factors. DNA damage was measured through the comet assay via hepatocytes and histological examination was conducted in order to ensure the liver injuries.

Current study comprises of four different group of Balb/c albino mice, from them 1st group was facilitated with normal saline as per recommended dose of 1ml/kg. In 2nd group of mice, phentolep drug was injected with the dose of 12mg/kg for two continuous weeks. Whereas; in 3rd group same, the drug is administered into the mice with same dosing regimen for 02 weeks and then allowed to recover for 02 weeks. In the last group of mice, phentolep was given to the remaining mice with a similar regimen and managed for 04 weeks for normal physiological functions and it was concluded that induction of phentolep among various groups of mice can induce alteration the nucleus of hepatocytes and ultimately variation occurred within DNA. 3rd and 4th groups showed quite differ results than the positive group as regression was observed in these groups and restore the normal physiology of the liver and the current study indicates that hepatic injuries can be sorted out with passage of time.

*Corresponding author: E-mail: saminasikan@gmail.com;

Keywords: Phentolep; Hepatic injuries; Musculus; DNA; (Dosage) regimen.

1. INTRODUCTION

Phentolep is type of essential drug that blocks the exchange of ions through sodium gate as it initiates its mechanism, it vanishes the malicious seizures through the nerve impulses without spreading in neuronal axon [1,2]. Transport of calcium ions are also banned within synapses as along with sodium gate, calcium gates are also blocked.[3] Phentolep is metabolized through hepatic liver enzyme CYP-450 and this enzyme is also responsible for the drug efficacy of numerous types and it totally relay upon the genotype of the patients. [4] Phentolep is mostly recommended for the therapeutic effects against numerous ailments such as ocular ulcer, irregular heartbeat, palatal incision, sciatica and various series of local and generalized epilepsy. [5, 6] Regular consumption of this drug induces feverish impact likewise cerebellar degenerations,[7] visual failure, acute toxicity and fetal hydration syndrome.[8] There are strong literatures available regarding concurrently consumption of Phentolep with acetaminophen induces toxicity of liver.[9] Liver damage that occurs due to accumulation of matrix protein is said to be as liver fibrosis[10] and it occurs in most of the chronic liver diseases and fibrosis is lead to cirrhosis and portal hypertension. Sometime, this fibrosis needs liver transplantation for proper functioning. [11] For the diagnosis of fibrosis, liver biopsy is needed; beside this various analytical techniques are also used for detection of severity of fibrosis. [12] Phentolep is type of anticonvulsant drug that induces liver disease in rare cases and once hepatotoxicity is induced it can be fatal. This hepatotoxicity occurs due to immune allergic reaction and it also induces hypersensitivity. Phentolep itself not considered as hepatotoxic drug but it metabolized into arsenic oxide that may be responsible for the degradation of liver. After 6 to 8 weeks of regular consumption of Phentolep may initiate the symptoms of liver fibrosis with cluster of symptoms such as fever, jaundice, facial edema and dark urine.[13] These type of hepato toxic symptoms appeared due to hypersensitivity syndrome that enhances the WBCs count.[14] Number of other diseases may also initiate such as necrosis, pneumonitis, aplastic anemia, and neutropenia. [15] These conditions may be overcome with quick prevention of Phentolep drug. If it is not managed properly on time ultimately enhances amino-

transferase thrice time than the normal position and this is responsible for chronic injury.[16]

2. MATERIALS AND METHODS

2.1 Drugs

Phentolep drug was acquired from well known Pharmaceutical Company of Pakistan and positive control dose was assumed through the therapeutic dose applied for human studies and sample drug was dissolved in normal saline and drug was re-sampled through one ration ten of the lethal dose among the albino mice.

2.2 Animals and experimental design

The research was conducted on the 20 adult and healthy male albino mice having 8 weeks of age and weigh about 28 grams. All albino mice were purchased from the animal house of HEJ center for excellence, University of Karachi. Before any experiment, all animals were placed in standard laboratory protocols at standard room temperature with 12 hours of rotation of dark and light for seven days. Albino mice were placed in special type of cages and were facilitated with diet and water on daily basis. Prior to performance all animals were randomly distributed among 04 different groups.

GROUP-I: Considered as Negative control group, In which normal saline was injected among the animals with the dose of 1ml/kg of total body weight.

GROUP-II: It is considered as Positive control group, In which Phentolep drug is injected 12mg/kg per day for 02 weeks.

GROUP-III: In this group, drug is injected as 2mg/kg/day for 02 weeks and cared for next 02 weeks.

GROUP-IV: In this group, drug is injected as 12mg/kg/day for 02 weeks and cared with precaution for at least 04 weeks.

All injections were prepared with the required dosing quantity and injected through intra-peritoneal route of administration. Prior to 12 hours of administration of drugs, the food supply for all animals was stopped and sample was collected after 02 weeks from group I and II and after 04 weeks from group III and after 06 weeks from the last group IV.

2.3 Comet assay

This assay is used to measure the DNA damage of hepatocytes of albino mice. Once scarification of mice was carried out, the liver was separated out and homogenized in aseptic condition. 2ml of homogenized liver was mixed with 2ml of media (mention the name of the media) that was used for lysis of hepatocytes then centrifuged for half an hour with the speed of 1500rpm. This mixture was mixed with melted buffered agarose and single drop was smeared on the slide of the microscope that was already covered with agarose. Entire hepatocytes were digested except DNA material within lytic solution and the slides were electrophoresed at 0.74 volts for half an hour and DNA material was shifted to positive rod and this slide was stained in ethidium bromide in dark light. (Here the researcher should use photographs of the critical points of the experiment.)

2.4 Histology

Liver components were washed through normal saline and put into 10% formalin for entire day and dried with ethanol then again washed xylene solution and prepared slide was examined under the light microscope. [17]

2.5 Statistical Analysis

All the research data was statistically satisfied by using the statistical software 20.00 version and taking P as significant of less than 0.005.

3. RESULTS

3.1 Comet assay

Comet classes were evaluated through the filter of 515-560nm of fluorescent microscope as mentioned in Fig. 1. Three groups of comet assay were evaluated, group I had very minute tail, group-II possess slightly greater tail than group-I. Whereas; Group-III possessed the size of tail twice than the size of remaining groups of animals. Liver cells without any authentic heads were neglected from scarification.

3.2 Histological Study

Consequences of negative group represent normal hepatic tissues with authenticated vascular and nuclear structures as mentioned in Fig. 2. In group-III, Phentolep was given to

animals with the dose of 12mg/kg/day for 02 consecutive weeks that represent focal inflammation as mentioned in Fig. 3. Degrade alteration in the cytoplasm of liver cells along with necrotic area & pyknotic nuclei was observed in Fig. 4. The Group that was allowed to recover after the injection of required drugs appeared with binuclear liver cells as mentioned in Fig. 5. The last group had good recovery of hepatic cells that appears with normal positions and it represent with central vein in diluted form as mentioned in Fig. 6.

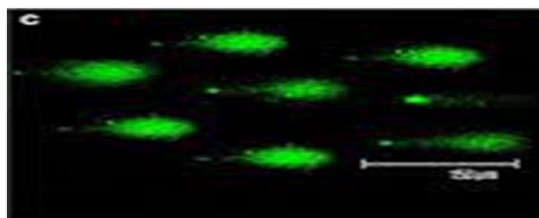


Fig. 1. Image of hepatocytes nuclei of Male albino mice treated with Phentolep drug for 02 weeks

4. DISCUSSION

Consequences of positive control group were observed that management through Phentolep drug induces DNA damage in hepatocytes among the male albino mice and they had positive results as compared to negative control group. Results were compared with the previous study that Phentolep drug can initiate DNA single breakage among the fetal cell of mice. [18] Histopathological study showed that among the positive group of animals, Phentolep drug might induce alteration within the parenchyma and the hepatic vascular system. [19] Alteration in the DNA damage resemble with previous researches that immune-allergic reaction may also be induced by the concurrent administration of Phentolep drug. [20] Current research was associated with metabolism of Phentolep that metabolites produced after the metabolism of Phentolep were responsible for hepatic injury. [21] DNA degradation can be evaluated through nuclear pyknosis of liver cells. [22] Oxidation pressure also initiates inflammatory reaction with parenchyma. Inflammatory reactions were characterized with accumulation of extracellular oxidative mediators. [23] These inflammatory damages caused by oxidative state of plasma by layer of hepatic cells. [19,20] Positive control group displayed clogging within vascular system that included portal vein, blood sinusoid and central veins and this blockage

were the consequences of oxidation of endothelial lining and clogging occur in either part of vascular system. [21] Group-III that allowed bi-nucleated liver cells was considered as marker. [22] The results were accompanied by the condition when the liver produced elimination by 60% for very short period of time.

[24] Phentolep drug produced oxidative stress among the parenchyma of liver cells ultimately induces nuclear factor erythroid (Nrf2). [25] These factors were responsible for liver regeneration to oxidize the stimulation or blockage of regeneration of liver.

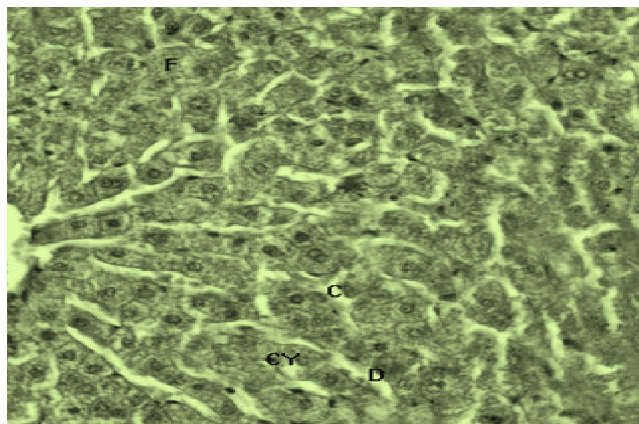


Fig. 2. Photomicrograph represented C.S in liver of control group of male albino mice; represent normal hepatic lobule CV, PV and BD along with hepatic artery

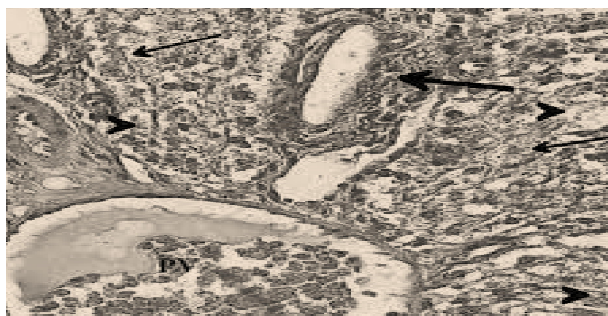


Fig. 3. Photomicrograph represented CS in Albino mice treated with Phentolep 12mg/kg/day

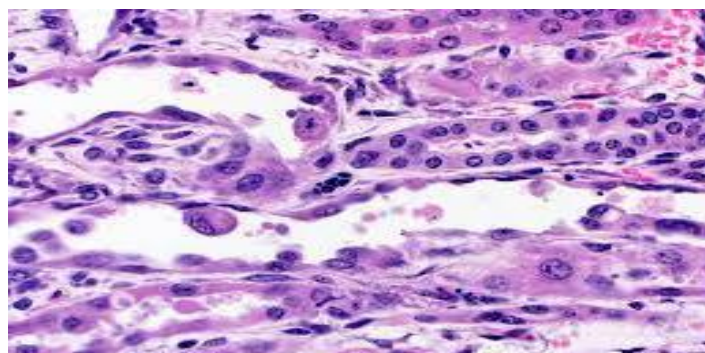


Fig. 4. Photomicrograph represented CS in Liver albino Mice treated with Phentolep 12mg/kg/body weight for two weeks representing hydropic degeneration

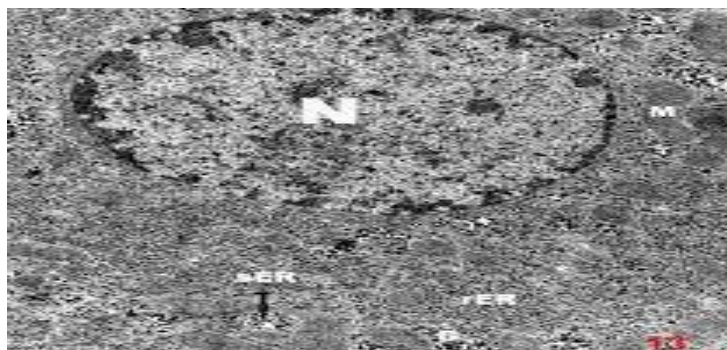


Fig. 5. Photomicrograph represented CS in Liver albino Mice treated with Phentolep 12mg/kg/ body weight for two weeks and allowed for 02 weeks to recover

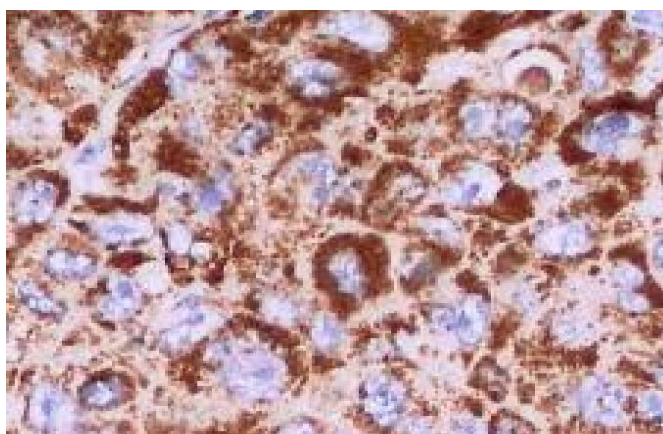


Fig. 6. Photomicrograph represented CS among albino mice with 12mg/kg/ body weight for 02 weeks and allowed for 04 weeks for recovery

5. CONCLUSION

Therapeutic dosing of Phentolep has ability to produce reversible injuries within the liver cells along with DNA content and it also initiate histopathological conditions among the albino mice and it was concluded that Phentolep can administered with restricted precautions among patients with severe hepatic disorders.

CONSENT

It is not applicable.

ETHICAL APPROVAL

The experiment were performed by using standard and recommended procedures approved by animal ethical committee.

COMPETING INTERESTS

Authors have declared that no competing interests exist.

REFERENCES

1. Tabor PA. Drug-induced fever. Drug intelligence & clinical pharmacy. 1986;20(6):413-20.
2. Sasaki E, Yokoi T. Role of cytochrome P450-mediated metabolism and involvement of reactive metabolite formations on antiepileptic drug-induced liver injuries. The Journal of toxicological sciences. 2018;43(2):75-87.
3. Russo MW, Galanko JA, Shrestha R, Fried MW, Watkins P. Liver transplantation for acute liver failure from drug induced liver injury in the United States. Liver Transplantation. 2004;10(8):1018-23.
4. Zhang P, Jiang XF, Nie X, Huang Y, Zeng F, Xia X, Wu S. A two-photon fluorescent sensor revealing drug-induced liver injury via tracking γ -glutamyltranspeptidase (GGT) level in vivo. Biomaterials. 2016;80:46-56.

5. Liu L, Wells PG. DNA oxidation as a potential molecular mechanism mediating drug-induced birth defects: phenytoin and structurally related teratogens initiate the formation of 8-hydroxy-2'-deoxyguanosine in vitro and in vivo in murine maternal hepatic and embryonic tissues. *Free Radical Biology and Medicine*. 1995;19(5):639-48.
6. Wu YM, Joseph B, Berishvili E, Kumaran V, Gupta S. Hepatocyte transplantation and drug-induced perturbations in liver cell compartments. *Hepatology*. 2008;47(1):279-87.
7. Björnsson E, Kalaitzakis E, Olsson R. The impact of eosinophilia and hepatic necrosis on prognosis in patients with drug-induced liver injury. *Alimentary pharmacology & therapeutics*. 2007;25(12):1411-21.
8. Sasaki E, Matsuo K, Iida A, Tsuneyama K, Fukami T, Nakajima M, Yokoi T. A novel mouse model for phenytoin-induced liver injury: involvement of immune-related factors and P450-mediated metabolism. *Toxicological sciences*. 2013;136(1):250-63.
9. Larrey D, Pageaux GP. Genetic predisposition to drug-induced hepatotoxicity. *Journal of Hepatology*. 1997;26:12-21.
10. Altuntas Y, Ozturk B, Erdem L, Gunes G, Karul S, Ucak S, Sengul A. Phenytoin-induced toxic cholestatic hepatitis in a patient with skin lesions: case report.(Case Report). *Southern medical journal*. 2003;96(2):201-4.
11. Jinjuvadia K, Kwan W, Fontana RJ. Searching for a needle in a haystack: use of ICD-9-CM codes in drug-induced liver injury. *American Journal of Gastroenterology*. 2007;102(11):2437-43.
12. Curry B, Mican L, Smith TL. Phenytoin-induced chronic liver enzyme elevation and hepatic fibrosis: A case report. *Mental Health Clinician*. 2018;8(4):184-7.
13. Sridharan K, Al Daylami A, Ajjawi R, Al Ajooz HA. Drug-induced liver injury in critically ill children taking antiepileptic drugs: A retrospective study. *Current Therapeutic Research*. 2020; 92:100580.
14. Rochon J, Protiva P, Seeff LB, Fontana RJ, Liangpunsakul S, Watkins PB, Davern T, McHutchison JG, Drug-Induced Liver Injury Network (DILIN). Reliability of the RousselUclaf Causality Assessment Method for assessing causality in drug-induced liver injury. *Hepatology*. 2008;48(4):1175-83.
15. Smythe MA, Umstead GS. Phenytoin hepatotoxicity: a review of the literature. *Dicp*. 1989;23(1):13-8.
16. Bleibel W, Kim S, D'Silva K, Lemmer ER. Drug-induced liver injury. *Digestive diseases and sciences*. 2007;52(10):2463-71.
17. Ramachandran R, Kakar S. Histological patterns in drug-induced liver disease. *Journal of clinical pathology*. 2009;62(6):481-92.
18. Leise MD, Poterucha JJ, Talwalkar JA. Drug-induced liver injury. In *Mayo clinic proceedings* 2014;89(1):95-106. Elsevier.
19. Um SJ, Lee SK, Kim YH, Kim KH, Son CH, Roh MS, Lee MK. 3 Clinical Features of Drug-Induced Hypersensitivity Syndrome in 38 Patients. *Journal of investigational allergology& clinical immunology*. 2010;20(7):556.
20. Devarbhavi H, Karanth D, KS P, CK A, Patil M. Drug-Induced liver injury with hypersensitivity features has a better outcome: a single-center experience of 39 children and adolescents. *Hepatology*. 2011;54(4):1344-50.
21. Au JS, Pockros PJ. Drug-induced liver injury from antiepileptic drugs. *Clinics in liver disease*. 2013;17(4):687-97.
22. Lee WM. Drug-induced hepatotoxicity. *New England journal of medicine*. 2003;349(5):474-85.
23. Kaplowitz N. Drug-induced liver disorders. *Drug safety*. 2001;24(7):483-90.
24. Avancini J, Maragno L, Santi CG, Criado PR. Drug reaction with eosinophilia and systemic symptoms/drug-induced hypersensitivity syndrome: clinical features of 27 patients. *Clinical and experimental dermatology*. 2015;40(8):851-9.
25. Zimmerman HJ. Drug-induced liver disease. *Drugs*. 1978;16(1):25-45.

© 2021 Memon and Ahmed; This is an Open Access article distributed under the terms of the Creative Commons Attribution License (<http://creativecommons.org/licenses/by/4.0>), which permits unrestricted use, distribution, and reproduction in any medium, provided the original work is properly cited.

Peer-review history:

The peer review history for this paper can be accessed here:
<https://www.sdiarticle4.com/review-history/68758>