



# Degeneration in Renal Cells of Freshwater Fish (*Channa punctata*) under Exposure of Nigrosine Black (Acid Black-2), a Tanning Industry Dye

Jyoti Prakash Srivastava <sup>a\*</sup> and Vishal Chand <sup>b</sup>

<sup>a</sup> Department of Zoology, D.B.S. College, Kanpur-208001, India.

<sup>b</sup> Department of Biotechnology, CSJM University, Kanpur-208024, India.

## Authors' contributions

This work was carried out in collaboration between both authors. Both authors read and approved the final manuscript.

## Article Information

DOI: 10.9734/AJFAR/2022/v17i430412

## Open Peer Review History:

This journal follows the Advanced Open Peer Review policy. Identity of the Reviewers, Editor(s) and additional Reviewers, peer review comments, different versions of the manuscript, comments of the editors, etc are available here: <https://www.sdiarticle5.com/review-history/87600>

Original Research Article

Received 12 March 2022

Accepted 24 May 2022

Published 28 May 2022

## ABSTRACT

Nigrosine Black (Acid Black-2) is popularly used in tanning industries and a huge amount of this dye comes out with effluent of tanning industries, this dye reached near water bodies, and what impact produced on their aquatic life not reveal yet, Hence a study was plan to find out the impact of Nigrosine black dye on the renal cell of freshwater fish *Channa punctata*. Sub-acute and chronic exposure to Nigrosine Black produced significant renal cellular degeneration in fish *C. punctata*. The 1/20th LC<sub>50</sub> (96h) of the Nigrosine Black produced degenerating changes in the kidney tissues of fish. Renal corpuscles were revealing swollen and contained some degenerated RBC and thmbrocytes, which appeared to be cellular debris in Bowman space, due to the rapid destruction of the nuclei of erythrocytes. The liberated hemoglobin and other cytoplasmic materials were also observed, while 1/20th of LC<sub>50</sub> (96hr) of Nigrosine Black produced renal degeneration in Bowman's capsule and swelling in the glomerulus in the intoxicated fish along with renal tubules atrophy, degeneration as compared to the control group of fish. The low dose of Nigrosine Black Toxicity in fish produced nephropathy, and nephrosis. While the high dose of Nigrosine black dye produces Glomerulonephritis in experimental fish. The kidney cells of experimental fish are damaged by both doses of Nigrosine Black. The physico-chemical property of aquarium water was kept constant during whole duration of experiment.

\*Corresponding author: Email: [srivastavasjps@gmail.com](mailto:srivastavasjps@gmail.com);

**Keywords:** *Channa punctata*; *bowman's capsule*; *renal corpuscles*; *renal cell*; *cellular degeneration*; *thmbrocytes(a white blood cell)*; *nigrosine black*.

## 1. INTRODUCTION

In Indian tanning industries, about 700000 tons of hides have processed every year by 3000 tanneries. Among these tanneries, few large firms are reported and more than 90 percent of tanneries are small to medium-sized. Small and medium-size tanning industries are processed less than two to three tons of skin/per day. These tanneries are processed sheep goat cow and buffalo hides and use vegetable and chrome tanning techniques. The thick concentration of tanning industries is located in India along the bank of the Ganga River System at Jajmau area in city Kanpur of Uttar Pradesh while in South India these industries are located around the Palar River System. Most of the Indian tanneries are using old techniques and production methods and these techniques are responsible for a high load of effluent pollutants. So, a tannery needs 130 tons of dye instead of 100 tons of dye. These 30 tones dyes go out as effluent that contaminates soil and water bodies located around the tanning industries. Olivera et al., [1] reported the presence of Azo dyes in drinking water in Brazil and produced mutagenicity in aquatic animals. Cavallin et al., [2] observed the effect of wastewater treatment plant effluents on fish reproduction and they conclude that wastewater containing compounds has affected the endocrine system especially hypothalamic-pituitary-gonadal axis function.

Pickering et al., [3] investigated acute and chronic toxicity of dyes and pigment receiving effluent to fathead minnow and they found that effluent is lethal to the embryos and larvae of Zebra fish. Bomberger and Boughton [4] reported the waste from the manufacture of dyes and pigments is a large source of aquatic pollution. Some workers also studied the toxic effect of different dyes on freshwater fish Rai et al., [5]; Barot and Bahadur [6-9]; Kaur et al., [10] in fishes and King (2015) in Human. Otavio et al., [11] studied ecotoxicology risk assessment of the leather industries using Acid Black-210 dye and they conclude this dye is safe from the ecotoxicological point of view.

Yoshifumi et al., [12] observed the lethal and sub lethal effects of Aniline and chlorinated Aniline on Zebra fish embryos and larvae and they were found that Aniline showed delayed lethal effect on the fish embryo. Srivastava et al., [13]

revealed alterations in the activity of a certain enzyme in the gill of a *Labeo rohita* when exposed to an Azo dye, Eriochrome Black -T. Vigneshpriya et al., [14] found out that green dye exposure to *Labeo rohita* brings out alteration in hematology, biochemistry, enzymology, and histopathology parameters in experimental fishes.

Alaguprathana and Poonkothi [15] were observed histoarchitecture alteration in the cell of the kidney when they exposed to methyl orange dye solution. Pathophysiological alteration in RBC of freshwater fish *Channa punctata* under Nigrosine Black dye was observed by Srivastava [16].

The effluent brought out by tanning industries contains many dyes and exerts a severe impact on the ecosystem. The released effluent from tanning industries contains investigating dye that contaminates the water stream, river, and underground water system as well as the ecosystem nearby [17-20]. The effluent which contains the dye Nigrosine Black will cause a variety of toxic effects on aquatic organisms in recipient water. Kidney, gill, and skin play a major role in osmoregulation, ion salt balance, and excretion in freshwater fishes. If these dyes affect the renal system, it will negatively impact the fish's health and well-produced high mortality among them [21-25]. There are copies of literature available on the various impacts of dyes on the different organs of fish but no study is present on the impact of Nigrosine Black on the renal system of freshwater fish. Hence keeping this point of view, we decided to investigate the Impact of Nigrosine Black (Acid Black -2) a tanning industry dye on the histoarchitecture of renal cells in freshwater fish *Channa punctata*.

## 2. MATERIALS AND METHODS

### 2.1 Test animal

According to USEPA, [26], because of their surroundings, fishes are excellent study models for studying the effects of water and sediment borne pollutants. There are several other good reasons for studying toxicity in fish.

1. As many of disease are related to environmental quality.

2. Various pollutants have toxic potential.
3. Fishes are easy to obtain. There is a wide range of knowledge and its economic interest facilitates the search for research resources.

Our test animal model is freshwater fish *Channa punctata* (Bloch.) fulfill all the criteria as out lined above. It is easy to available and acclimatizes due to its air breathing habitat and hardy in nature. The fish live generally in low oxygen contained polluted freshwater bodies and can be cultured for its economic and food value.

## 2.2 Collection of Freshwater Fish *Channa punctata* and Acclimatization

About 180 fishes of both sexes with varying weight (150gm±3.45) approx. 4 inches in length



were collected from a local fish farmer from Jyoti fish Farm, Kanpur city, and disinfected by dipping them in 0.01% KMNO<sub>4</sub> solution. After collection, the fish were maintained in glass aquaria for about 10 days for acclimatization. Fish were kept in a large size aquaria (3`x1.5`x1.5`) containing 80 liters of water in each. Commercial fish food was supplied daily with water that was 1/10th of their body weight. The water was changed daily with aeration (Figs. 1 and 2).

## 2.3 Test Chemicals

The test chemical is used in the present study is Nigrosine black dye (Acid Black-2), procured from a local vendor in Kanpur city and it has the following chemical property (PUBCHEM 2022).

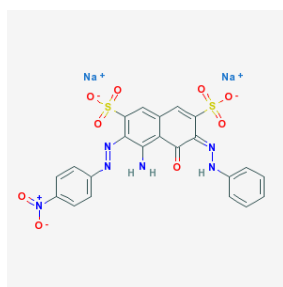


Fig. 1 and 2. showing test animal *Channa punctata* is acclimatized ten days prior to experiment

## 2.4 Chemical Properties of Test Chemical

Appearance	Black Powder
CAS Number	8005-03-6
IUPAC Name	Disodium(6e)-4-Amino-3-(4-Nitrophenyl)Diazenyl-5-Oxo-6-(Phenylhydrazinylidene)Naphthalene-2,7-Disulfonate
Melting Point	275° C
Molar Mass	616.49g/mol
Molecular Formula	C <sub>22</sub> H <sub>14</sub> N <sub>6</sub> Na <sub>2</sub> O <sub>9</sub> S <sub>2</sub>
NFPA 704	H-0,F-1,R-0,C-NA
RTECS Number	GC4762250
Solubility	Soluble 10-50 mg/ml at 64 °F (NTP)

Uses: Nigrosine is used in the dyeing of leather, wood, and textiles, manufacturing of ink, shoe polish cream, carbon paper, and toner.



Molecule Structure Image of Nigrosine black

### Physico - Chemical Parameters of water, which was used in aquaria and their Methods of Analysis.

Parameter	Method Of Analysis	Range	References
pH	Digital pH meter	7.36 ± 1.97	
Total hardness	EDTA titrimetric method	283.22 ± 4.57 mg/l	APHA (2005)
Dissolved oxygen	Wrinkle method	10.2 ± 0.44 mg/l	APHA(2005)
Turbidity	Nephelometric	281 ± 3.85 mg/l	APHA (2005)
Temperature	Digital thermometer	28.87 ± 1.47°C	APHA (2005)

### Experiment design, Dose, and schedule of Experiment.

Dose and schedule of experiment was followed as Srivastava [16]

- 1/5th concentration of LC<sub>50</sub> i.e. 378 mg/liter for 56 days exposure (sub-acute).
- 1/20th concentration of LC<sub>50</sub> i.e. 94.5 mg / liter for 80 day exposure (chronic).
- Exposed fish in normal water used as controlled with the whole duration of the treated experiment.

All parameters for study in fish will measure at 7, 21, and 35 days for sub-acute toxicity while 20, 40, 60, and 90 days for chronic toxicity test along with control. Each group had 10 fish.

### 2.5 Histological Study

All treated and control fish was sacrificed according to the schedule of the experiment. Tissues of treated and control animals were preserved in 10 per cent saline formaldehyde solution and the procedure for histology was as follows (Kolomer et al., 1960).

Tissue fixation → washing → Dehydration  
 Cleaning → Wax embedding → Wax Block  
 Making → Wax block cutting → Wax ribbon  
 making → Wax ribbon → de-waxing → Hydration  
 Staining (Haemotoxyline + Eosin) → Mounting.

Histologically prepared slides were seen under microscope for identification of pathological lesion in renal tissues of kidney in experimental fish.

### 2.6 Kidney Histology of Control Group Fish

The histopathology of the control group fish kidney shows that the nephron is an excretory part and it is inter-fused into hematopoietic tissue. The anterior region of the kidney has more hematopoietic tissues but the number of nephrons increased caudally with reduced hematopoietic tissue. Nephrons are arranged in a chaotic manner and different parts of nephrons are scattered virtually anywhere. A nephron of control fish has the following parts.

1. Glomerulus
2. Different tubules (Neck segment, proximal and distal tubules)
3. Collecting ducts: - These are differentiated from tubules by their cuboidal epithelium manner, large diameter and presence of smooth muscle fibers with connective tissue.

The glomerulus is a complex structure and its components are the fenestrated capillary endothelium, Glomerulus basement membrane, podocytes, and parietal epithelium cells. These parietal epithelial cells lined the bowman's

space. Some plasma filtrates were also seen in bowman's space. The entire glomerular tuft is supported by mesangial cells. The capillaries branches of the renal artery are seen in the glomerulus. Few melanomacrophages (Mnc's) were also present in between hematopoietic and lymphoid tissues of the control group fish's kidneys. Eosinophilic granules cell (EGC) was also revealed (Fig. 3).

Neck renal tubules were small in size with low cuboidal epithelium and their brush border has long cilia. The central canal of neck tubules has a small diameter in comparison with proximal tubules. The nuclei of neck tubules were oval in shape and located basally (Fig. 3).

The proximal convoluted tubule (1<sup>st</sup> segment) was large in comparison with neck tubules and small in comparison with distal tubules in terms of diameter. The anterior region of proximal tubules epithelium was cuboidal to columnar in shape and their nuclei are large in size and round in shape. The nuclei were located in the center of the cell and a few were located at the base portion of the cell. The Brush border of proximal tubules was distinct and the central canal was large in comparison with neck tubules (Fig. 3).

The posterior proximal convoluted tubule (2<sup>nd</sup> segment) epithelium was tall columnar in shape and their nuclei are oval in shape and it was located centrally in the cell. Their brush boarder was prominent (Fig. 3).

Distal convoluted renal tubules have columnar was wide in diameter. The epithelium has oval shape nuclei and is located at the base of the cell. There was no brush boarder in distal convoluted renal tubules (Fig. 3).

### **2.7 Histology of Fish Kidney Exposed in to 1/5<sup>th</sup> LC<sub>50</sub> of Nigrosine Black**

In the present study, the exposure of 1/5th of LC<sub>50</sub> of Nigrosine black (378 mg/liter) produced vacuolization of the epithelial cells of tubules. The nuclei of proximal renal tubules showed vacuolation and some of them were pycnotic. There were mild degenerations of the cells membrane also present on the 7th day of the experiment. (Fig. 4).

Exposure to 1/5th LC<sub>50</sub> of Nigrosine black for 21 days in experimental fish produced more vacuolization in the different renal cells. There

was hyperplasic growth of cells and the nuclei of the cells were displaced to the periphery. The cells of the renal corpuscles showed cytoplasmolysis. The nucleus of cells showed lysis leading to a gap in between the cells. Due to the lysis of the cell membrane of adjacent cells, there was an aggregation of the nuclei leading to the syncytial condition. (Fig. 5).

In experimental fish that were exposed to 1/5th LC<sub>50</sub> of Nigrosine black for 35th days, the toxicant produced significant pathological changes in the kidneys of experimental fish. There were large vacuoles found in the interstitial cells. Most of the cells showed cytoplasmolysis in the multinucleated condition. (Fig. 6).

### **2.8 Histology of Fish Kidney Exposed into 1/20<sup>th</sup> LC<sub>50</sub> of Nigrosine Black**

The present study found that on the 20th day of the experiment, 1/20th of LC<sub>50</sub> Nigrosine black (94.5 mg/l) exposure to experimental fish produced mild histopathological changes in the kidney. The distal and collecting tubules (convoluted) of the kidney showed mild degeneration and have a large lumen due to hypertrophy (Fig. 7).

After the 40<sup>th</sup> day of experiment, the cells of the kidney were showing vacuolization, shrinkage and breakage of tissue. Swollen nuclei in degenerated tubular epithelium were also observed in the kidney of fish exposed to 1/20<sup>th</sup> LC<sub>50</sub> of Nigrosine Black (Fig. 8).

Within the 60th days of the experiment, the kidney of fish showed that the cell boundaries were disrupted and hence the cells became indistinct. Glomerulus disorganization, pycnotic nuclei, degeneration and atrophy of renal tubules, Intercellular spaces formation were also observed in experimental fish (Fig. 9).

Degeneration and atrophy of renal tubules, degeneration in the glomerulus, disorganization of the glomerulus, severe necrosis, and highly pycnotic nuclei were observed at the 90th days of the experimental fish that were exposed to 1/20th LC 50 of Nigrosine black with the variable degree. (Fig. 10).

## **3. DISCUSSION**

Fish kidney is a composite organ with three distinct functions i.e. excretory, hematopoietic and endocrine. In Nigrosine black dye exposed



fish kidney were showed a lot of histopathological variation which indicate alteration in renal function of toxicated fish. In any renal disease they affected any of the four major structural component of kidney i.e.

glomerulus, tubules, interstitial tissue and blood vessels separately, because these all structure are interdependent hence that disease in one functional unit almost affected neighboring structure [27].

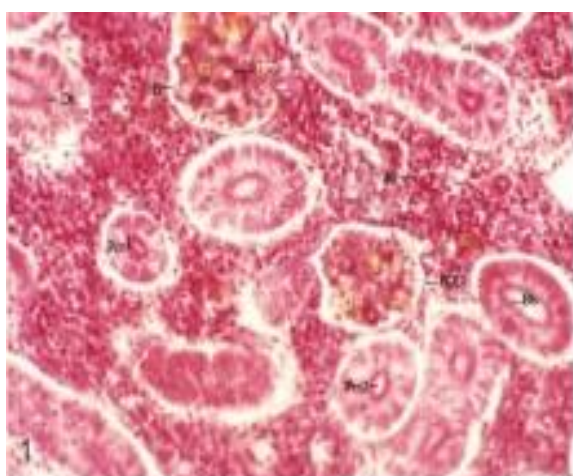

Fig. 3. Showing T.S. kidney of *C.punctatus* in control group with standard structure Glomeruli (G)Bowman space (B), Brush border (Bb),Erythrocyte (E), Distal convoluted tubules (DT), Proximal convoluted tubules (pct-1) and (Pct-2),Haematopoietic tissue (Ht), Podocytes cells (POD) X400.



Fig. 5. showing T.S. Kidney of *C.punctatus* exposed 1/5<sup>th</sup> LC<sub>50</sub> of Nigrosine black dye. Shrinkage in renal peripheral tubules is seen at 21<sup>st</sup> day of experiment along with thrombocyte in blood vessels X400

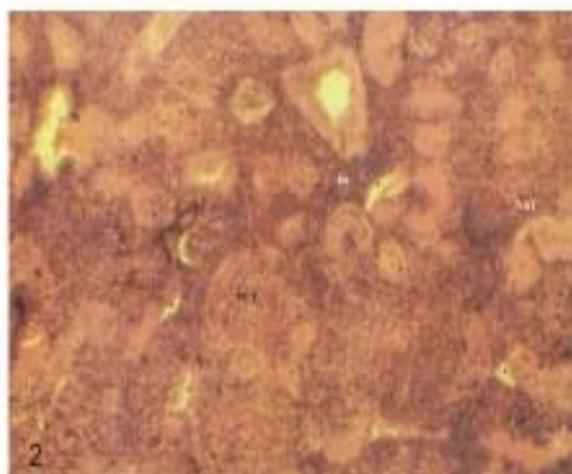


Fig. 4. showing T.S. Kidney of *C.punctatus* exposed 1/5<sup>th</sup> LC<sub>50</sub> of Nigrosine black dye. Mild degeneration in renal peripheral tubules is seen at 7<sup>th</sup> day of experiment along with thickening of renal tubules. X400

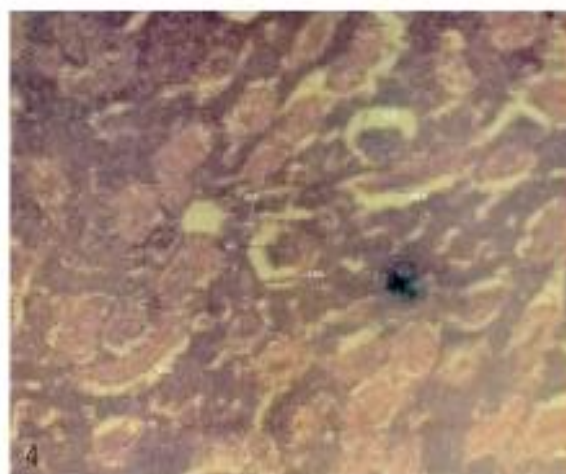

Fig. 6. showing T. S. Kidney of *C. punctatus* exposed 1/5<sup>th</sup> LC<sub>50</sub> of Nigrosine black dye. Thicken of parietal epithelium cell line of Bowman Capsule, increased space between glomerulus and bowman(SB) Shrink glomerulus(SG),Necrosis in renal tubules, renal tubule atrophy (RTA) were seen at 35<sup>th</sup> day of experiment. X400

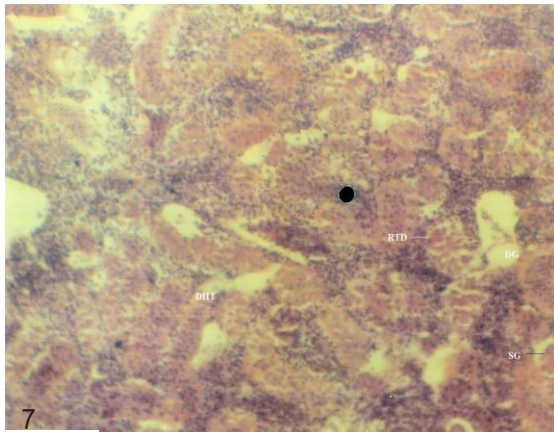


Fig. 7. showing T.S. Kidney of *C.punctata* exposed  $1/20^{\text{th}}$   $LC_{50}$  of Nigrosine black dye. Mild renal tubules degeneration (RTD) , renal tubules atrophy(RTA), Degenerated Glomerulus (DG), shrunken glomerulus ( SG), were seen at  $20^{\text{th}}$  day of experiment . X400

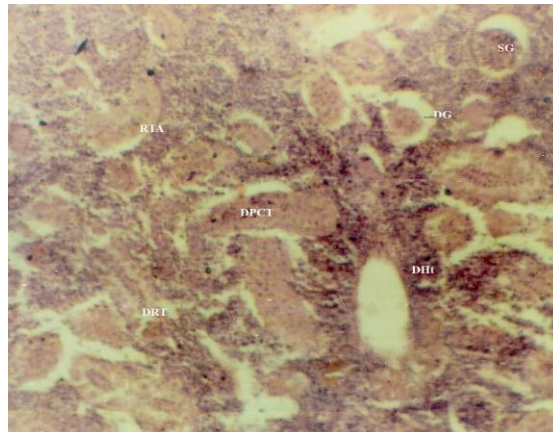


Fig. 9. showing T.S. Kidney of *C.punctata* exposed  $1/20^{\text{th}}$   $LC_{50}$  of Nigrosine black dye. Renal tubules atrophy (RIA), degenerated proximal convoluted tubules (DPCT), Degenerated glomerulus (DG), Degeneration of hematopoietic tissue were seen at  $60^{\text{th}}$  day of experiment . X400

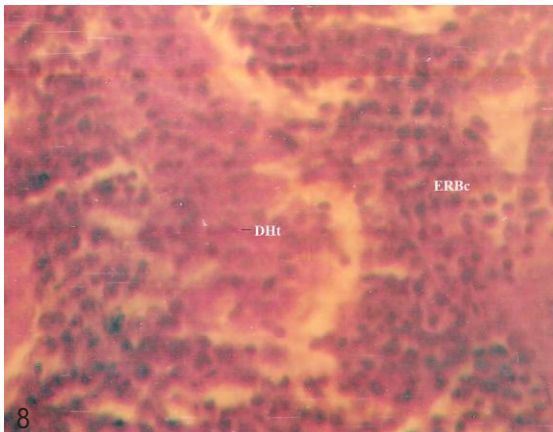


Fig. 8. showing T.S. Kidney of *C.punctata* exposed  $1/20^{\text{th}}$   $LC_{50}$  of Nigrosine black dye. Degeneration in hematopoietic tissues(DHt) and fragmented Red blood cells (F,RBc) were seen at  $40^{\text{th}}$  day of experiment . X400

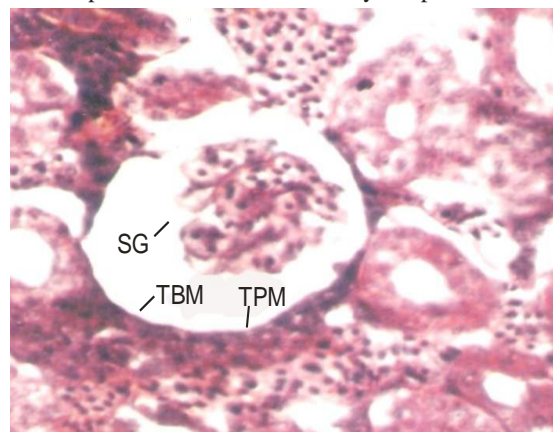


Fig. 10. showing T.S. Kidney of *C.punctata* exposed  $1/20^{\text{th}}$   $LC_{50}$  of Nigrosine black dye. Increase space between Glomerulus and bowman parietal epithelium cell line(TBM), Shrink Glomerulus(SG) and thick parietal membrane(TPM) were seen at  $90^{\text{th}}$  day of experiment . X1000

The kidney of the Nigrosine black dye exposed group fish showed highly significant histopathological alteration like fatty change in the renal tubular cells. The most common changes found in the kidneys of both exposure groups were severe degeneration and necrotic changes in the tubules of renal tissues. However, intra-renal hematopoietic tissue also showed significant changes like distortion of the continuity for the parenchyma of renal tissues and increased lymphocytes in the kidney. Dose and time duration enhance the quantity of hemosiderin pigment was also observed indicating the erythrocyte disruption and accumulation of this pigment in

melanomacrophages (Mela et al., 2007). In addition to necrotic and degenerative changes in the focal areas of the epithelium and necrosis of the renal tubules, there was atrophy of glomeruli and widening of the space between the Bowman's capsule and declinator glomeruli. The fatty change in the renal tubular cell was significantly increased over time [28,29,30]. In fish, as in higher vertebrates, the kidney performs an important function to maintain homeostasis. Kidney tissues are the main organs that are affected by water contaminants [31] (Mela et al., 2007). In the present study, the kidneys often show cloudy swelling in the tubular cells after exposure to Nigrosine Black. Cengiz

(2006) observed degeneration in the renal canal, pycnotic nuclei in hematopoietic tissue, and glomerulus degeneration. Similar kidney changes have been reported in Nile Tilapia [232].

In the present study, the exposure of 1/10th and 1/20th LC<sub>50</sub> of Nigrosine black dye toxicant to experimental fish showed mild changes in intra-renal hematopoietic tissue like distortion of the continuity of the renal parenchyma and increased lymphocyte in the kidney. The cells showed hyperplastic condition and there was an aggregation of the cells also. Along with time duration the hemosiderin pigment that indicating the erythrocyte disruption and accumulation of this pigment in melanomacrophages. Cytoplasmolysis was observed in the corpuscles of kidney cells. Declinator and necrotic changes in renal tubular epithelium and focal areas of necrosis, there was atrophy of glomeruli, and widening of the space between the Bowman's capsule and glomerulus were also revealed [33].

The results of the present study are different from the above-mentioned results of various authors and there is no study is seen in past and current literature cited for Nigrosine black toxicity. This is the first study about the toxicity of Nigrosine Black on the kidneys tissues of fish.

Changes in the kidneys of the tilapia have been observed in a wide variety of fish exposed to heavy metals, and these changes have been described by Oliveira Ribeiro et al., [34]; Thophon et al., [31] and Gupta and Srivastava [35].

Some authors [36,33,37,38,39,40,29,30,15,28] were also reported cyto- nephrotoxicity in fishes under exposure of different industrial effluents and dyes. The present result shows that the Nigrosine black dye directly affects the aquatic life of freshwater fish. Therefore, a scientific method of detoxification is necessary to improve the health of these economical fish in any stressful environmental conditions. However, the high concentration of the analyzed dye in the whole body tissue examined can explain the role of these problems. Fish contaminated with Nigrosine black dye undergo pathological changes, resulting in inhibition of metabolic processes, hematological changes, and reduced fertility and survival [41,42,43]. From this study, it can be concluded that dye tends to accumulate in polluted environments along with fish. Since practically all dyes tested were found to be in high concentration, the government should maintain laws that ensure that industries have

standard waste treatment plants before discharging their waste into water bodies.

## CONCLUSION

- The low dose of Nigrosine Black has produced an alteration in the histology of kidney tissue especially proximal tubules, distal tubules, Collecting duct, and glomeruli but it was not severe.
- Changes in Glomerular structure indicate an alteration in blood flow as well as flow-through tubules and composition of filtrate after which it affected the tubular epithelium.
- Occlusion of the tubular lumen may increase as the pressure in Bowman's space increases-resulting in glomerular atrophy.
- As a consequence, a disorder of one component of the kidney will sooner or later have severe implications for another component of the kidney as well.
- The low dose of Nigrosine Black Toxicity in fish produced nephropathy, and nephrosis.
- While the high dose of Nigrosine black dye produces Glomerulonephritis in experimental fish.
- These histological alterations (nephropathy, nephrosis, and Glomerulonephritis) may also affect the hematopoietic and endocrine function of experimental fish. There is a need to further investigation of these factors under Nigrosine Black toxicity in fishes.
- Thrombocyte accumulation in renal tissue also indicates extensive hemorrhage due to glomerulonephritis.

## COMPETING INTERESTS

Authors have declared that no competing interests exist.

## REFERENCES

1. Olivera DP, Cannerio PA, Rech CM, Zanoni MY, Claxton LD, Umbuzeiro G. Mutagenic compounds generated from the chlorination of dispersed azo-dye and their presence in drinking water. *Environmental Sci. and Technol.* American Chemical Society, Washington, DC. 2006; 40(21):6682-6689,
2. Cavallin J, Jensen K, Khal M, Dan Villeneuve, Mayasich J, Lee K, Schroeder



- A, Eid E, Nelson K, Milsk R, Blackwell B, Berninger J, Lalone C, Lee L, Hughes M, Blanksma C, Jhonson R, Ankley G. Assessment of wastewater treatment plant effluent effects on fish reproduction. Society of Environmental Toxicology and Chemistry. Duluth, MN; 2015.
3. Pickering Q, Shaul GM, Dostal K. Acute and Chronic toxicity to the Fathead Minnow, *Pimephales promelas* of effluents from a treatment plant receiving dyes and pigment processing wastewater. U.S. Environmental Protection Agency, Washington, D.C., EPA/600/D-84/161(NTIS PB84210517); 1984.  
Available:[http://cfpub.epa.gov/si/si\\_public\\_comments.cfm](http://cfpub.epa.gov/si/si_public_comments.cfm)
  4. Bomberger D, Boughton R. Wastes from the manufacture of dye and pigments: volume 1. Azo dyes and pigments (benzidine and its congeners subsector) U.S Environmental Protection Agencies, Washington, D.C., EPA/600/2/-84/111A; 2004.  
Available:[http://cfpub.epa.gov/si/si\\_public\\_comments.cfm](http://cfpub.epa.gov/si/si_public_comments.cfm)
  5. Rai H, Bhattacharya M, Singh J, Bansal TK, Vats P, Banerjee UC. removal of dyes from the effluent of textile and dyestuff manufacturing industries: A review of emerging techniques with reference to biological treatment. Critical review in environmental Science and Technology. 2005;35:219-238, ISSN.
  6. Barot J, Bahadur A. Behavioural and histopathological effect of Azo dye on kidney and gill of *Labeo rohita* fingerlings. Journal of Environmental Biology. 2013;34:147-152.
  7. Barot J, Bahadur A. Toxic effect of Azo dye (C.I. Direct Green 6) on blood parameters of freshwater fish *Labeo rohita* (Hamilton) Journal of Cell and Tissue Research. 2014;14(2):4251-4254.  
Available:[www.tcrjournal.com](http://www.tcrjournal.com)
  8. Barot J, Bahadur A. Evaluation of Azo dye toxicity using some hematological and histopathological alteration in fish *Catla catla*. World Academy of Science, Engineering and Technology International journal of biological food, Veterinary, and Agricultural Engineering. 2015;9(5).  
Available:<https://www.researchgate.net/publication/326914598>
  9. Barot J, Bahadur A. Toxic impacts of C.I. acid orange 7 on behavioral, haematological and some biochemical parameters of *Labeo rohita* fingerlings. International Journal of Scientific Research in Environmental Sciences. 2015a; 3(8):0284-0290
  10. Kaur Kirandeep, Kaur Arvinder, Kaur Rajvir. Cytogenotoxicity of Azo dye acid blue-113(ab-113) to *Channa punctata* (Bloch.). Journal of Environmental Research and Development. 2015; 9(03):547-554.
  11. Otavio Pelegriño Rocha, Cibele Aparecida Cesila, Elisa Maria Christovam, Silvia Berlanga de Moraes Barros, Maria Valnice Boldrin Zanoni, Danielle Plamade Oliveira. Ecotoxicological Assessment of the "Acid Black 210" dye. Toxicology. 2017; 376(1):113-119.  
Available:<https://doi.org/10.1016/j.tox.2016.04.002>
  12. Yoshifumi Horie, Takahiro Yamagishi, Masaaki Koshio, Taisen Iguchi, Norihisa Tatarazako. Lethal and sublethal effects of aniline and chlorinated aniline on zebrafish embryos and larvae. Journal of Applied Toxicology. 2017;37(7):836-841.  
Available:<https://doi.org/10.1002/jat.3431>
  13. Srivastava A, Kumari U, Nigam AK. Alterations in the activity of certain enzymes in the gills of a carp *Labeo rohita* exposed to an Azo dye, Eriochrome black T: A biochemical investigation. Fish Physiol. Biochem. 2018;44:629-637.  
Available:<https://doi.org/10.1007/s10695-017-0458-9>
  14. Vigneshpriya D, Krishnaveni N, Renganathan S, Sri R, Sakthi priyadarshani. Impact of untreated and Sargassum wightii-treated brilliant green dye exposure on Indian major carp *Labeo rohita* Ham.: haematology, biochemistry, enzymology, and histopathology. International Journal of Phytoremediation. 2020;22(8):819-826.  
Available:<https://doi.org/10.1080/s15226514.2019.1710816>
  15. Alaguprathana M, Poonkothi M. Haematological, biochemical, enzymological, and histological responses of *Labeo rohita* exposed to methyl orange

- dye solution treated with *Oedogonium subplagiostomum* AP1. *Environ. Sci. Pollut. Res.* 2021;28:17602-17612.  
Available:<https://doi.org/10.1007/s11356-020-12208-7>
16. Srivastava, Jyoti Prakash. Pathophysiological Mechanism of Erythrocyte Morphological Alteration in Freshwater Fish *Channa punctata* Under Exposure of Nigrosine Black (Acid Black-2 a Tanning Industry Dye). *International Journal of Environment, Agriculture and Biotechnolog.* 2022; 7(1):162–167.  
Available:<https://doi.org/10.22161/ijeab.71.19>
  17. OECD T. OECD guidelines for the testing of chemicals. Genetic Toxicology: Mouse Heritable Translocation Assay. Adopted on. 1986;23.
  18. PubChem. Acid Black 2; SID 459281445; 2022.  
Available:<https://pubchem.ncbi.nlm.nih.gov>
  19. PubChem [internet]. Bethesda (MD): National Library of Medicine (US), National center for biotechnology information PubChem Substances Record for SID 135331703, 8005-03-6, Source: ChemIDplus; 2004.  
Available:<https://pubchem.ncbi.nlm.nih.gov/substance/135331703>
  20. Walia GK, Handa D, Kaur H, Kalotra R. Erythrocyte abnormalities in a freshwater fish, *Labeo rohita* exposed to tannery industry effluent. *International Journal of Pharmacy and Biological Sciences.* 2013;3(1):287-295.
  21. American Public Health Association. Standard methods for the examination of water and wastewater. American Public Health Association. 1926;6.
  22. Ceger P, Allen DG, Choksi N, Daniel A, Eckel W, Hamm J, Harwood E, Johnson T, Kleinstreuer N, Sprinkle C, Truax J, Lowit M. Retrospective evaluation of the acute fish toxicity test for pesticide registration. NICEATM Abstract: 11th World Congress on Alternatives and Animal Use in the Life Sciences; 2021.
  23. Kaur R, Kaur A, Kaur K. Ultra-morphology of the scale as an indicator of the stress of Acid Black-1 (AB-1, C.I.:20470) and zinc (Zn). *Environ. Sci. Pollut. Res.* 2019; 26:17121-17134.  
Available:<https://doi.org/10.1007/s11356-019-05067-4>
  24. King-Thom Chung. Azo dye and human health: A review. *Journal of Environmental Science and Health, Part C. Environmental Carcinogenesis and Ecotoxicology Reviews.* 2016;34(4):233-261.
  25. Kolmer JA, Spaulding EH, Robinson HW. In: *Approved laboratory techniques* V<sup>th</sup> Ed. Scientific Book Agencies Calcutta, India; 1951.  
Available:<http://www.worldcat.org/title/approved-laboratory-technic/oclc/646503>
  26. USEPA. Standard evolution procedure: Acute Toxicity Test for Freshwater Fish. Report no. 540/9 - 85006. 1985;1-17. NSCCEP.  
Available:<https://nepis.epa.gov/Exe/ZyPURL.cgi?>
  27. Frank Genten, Eddy Terwinghe, Andri Danguy. in book : *Atlas of fish histology* Science Publishers, Enfield, NH, USA; 2009.  
Available:<https://www.taylorfrancis.com/books/mono/10.1201/9780367803599/atlas-fish-histology-andr%C3%A9-danguy-franck-genten-eddy-terwinghe>
  28. Shahid S, Sultana T, Sultana S, Hussain B, Irfan M, Al-Ghanim KA, A-Misned F, Shahid Mahboob. Histopathological alterations in gills, liver, kidney and muscles of *Labeo rohita* collected from polluted areas of River. *Braz. J. Biol.* 2021;81(3).  
Available:<https://doi.org/10.1590/1519-6984.234266>
  29. Bilal Hussain, Hassan Sardar, Muhammad Sajad, Hira Yaseen, Sulman Shafeeq, KAAI-Ghanim, Ahmed Mustafa, Shahid Mahboob. Assessment of cytonephrotoxicity and growth performance in *Labeo rohita* induced by fluorescein dye Y and B. *Journal of King Saud University - Science.* 2021;33(8):101672.  
Available:<https://doi.org/10.1016/j.jksus.2021.101672>
  30. Bilal Hussain, Hira Yaseen, Khalid-Al-Ghanim, Al-Misned F, Muhammad Qasim, Al-Mulhm N, Shahid Mahboob. A study on risk assessment of effect of hematoxylin dye on cytotoxicity and nephrotoxicity in freshwater fish: Food and water security prospective research. *Saudi Journal of*

- Biological Sciences. 2021;28(4):267-2271.  
Available:<https://doi.org/10.1016/j.sjbs.2021.01.019>
31. Thophon S, Kruatrachue M, Upatham ES, Pokethitiyook P, Sahaphong S, Jaritkhuan S. Histopathological alterations of white seabass, *Lates calcarifer*, in acute and subchronic cadmium exposure. *Environ Pollut.* 2003; 121(3):307-20.  
DOI: 10.1016/s0269-7491(02)00270-1
32. Benli Aysel Çağlan Karasu, Gülten Köksal, Ayhan Ozkul. Sublethal ammonia exposure of Nile tilapia (*Oreochromis niloticus* L.): Effects on gill, liver and kidney histology. *Chemosphere.* 2008;72(9):1355-8.  
DOI: 10.1016/j.chemosphere.2008.04.037
33. Rantilla Amwele H, Papirom P, Chukanhom K, Beamish FWH, Petkam R. Tissue Alterations in *oreochromis niloticus* following chronic exposure to metal complex dark green azo acid dye and anionic surfactant oil. *Environment and Natural Resources Journal.* 2017; 15(1):41–50.  
DOI:<https://ph02.tci-thaijo.org/index.php/ennrj/article/view/80745>
34. Oliveira Ribeiro CA, Belger L, Pelletier E, Rouleau C. Histopathological evidence of inorganic mercury and methyl mercury toxicity in the arctic charr (*Salvelinus alpinus*). *Environ Res.* 2002;90:217-225.  
DOI: 10.1016/s0013-9351(02)00025-7
35. Gupta Pallavi, Neera Srivastava. Effects of sub-lethal concentrations of zinc on histological changes and bioaccumulation of zinc by kidney of fish *Channa punctata* (Bloch). *Journal of Environmental Biology.* 2006;27(2):211-215.
36. Venkatram Reddy, Velma Paul, Tchounwou B. Chromium-induced biochemical, genotoxic and histopathologic effects in liver and kidney of goldfish, *carassius auratus*. *Mutation Research/Genetic Toxicology and Environmental Mutagenesis.* 2010;698(1–2).  
DOI: 10.1016/j.mrgentox.2010.03.014
37. Borgia VJ. Florence, Thatheyus AJ, Murugesan AG, Catherine S, Alexander P, Geetha I. Effects of effluent from electroplating industry on the immune response in the freshwater fish, *Cyprinus carpio*. *Fish & Shellfish Immunology.* 2018;79:86-92.  
Available:<https://doi.org/10.1016/j.fsi.2018.05.010>
38. Millena Bruna Lunardelli T. Cabral, Carlos ED Vieira, Luciana F Oliveira, Wagner E Risso, Paulo C Meletti, Claudia BR Martinez. Chromium accumulation and biomarker responses in the Neotropical fish *Prochilodus lineatus* caged in a river under the influence of tannery activities. *Ecotoxicology and Environmental Safety.* 2018;153:188-194.  
Available:<https://doi.org/10.1016/j.ecoenv.2018.02.023>
39. Priyatha CV, Chitra KC. Sublethal toxicity of acid orange 7 in the freshwater fish, *anabas testudineus* (Bloch, 1792), and the role of vitamin c as antioxidant in the prevention of oxidative stress. *International Journal of Scientific Research in Biological Sciences.* 2019;6(2):92-101,  
Available:<https://doi.org/10.26438/ijrsbs/v6i2.92101>
40. Malik DS, Sharma AK, Sharma AK, Thakur R, Sharma M. A review on impact of water pollution on freshwater fish species and their aquatic environment. In: *Advances in Environmental Pollution Management: Wastewater Impacts and Treatment Technologies*, Volume 1, Eds. Kumar, V., Kamboj, N., Payum, T., Singh, J. and Kumar, P. 2020; 10-28.  
Available:<https://doi.org/10.26832/aesa-2020-aepm-02>
41. Mela M, Neto FF, Yamamoto FY, Almedia R, Grotzner SR, Ventura DF, Ribeiro CA.de.O. Mercury distribution in target organs and biochemical responses after subchronic and trophic exposure to Neotropical fish *Hoplias malabaricus*. *Fish Physiol Biochem.* 2014;40:245-256  
DOI: 10.1007/s10695-013-9840-4
42. Murugesan AG, Ramathilaga A, Samson Ponselvan JK, Michael R. Dinakaran immunotoxicity of tannery effluent to the freshwater fish *Cyprinus carpio*. *Bull Environ Contam Toxicol.* 2012;88:639–643.

Available:<https://doi.org/10.1007/s00128-011-0511-9>

43. WHO. Environment health criteria No 180 USA; 1966.

---

© 2022 *Srivastava and Chand*; This is an Open Access article distributed under the terms of the Creative Commons Attribution License (<http://creativecommons.org/licenses/by/4.0>), which permits unrestricted use, distribution, and reproduction in any medium, provided the original work is properly cited.

*Peer-review history:*

*The peer review history for this paper can be accessed here:  
<https://www.sdiarticle5.com/review-history/87600>*