

Asymptomatic Acute Dissection of the Abdominal Aorta as a Rare Complication of Takayasu Disease

Hind Nabawi ^{a*}, Halima Eljazouli ^a, Basma Dihi ^a, Soukaina Oumlil ^b,
Mohamed El Jamili ^a, Nadia Charai ^a, Mustapha El-Hattaoui ^a
and Lamia Essaadouni ^b

^a Cardiology Department, Mohammed VI University Hospital, Marrakesh, Morocco.
^b Internal Medicine Department, Mohammed VI University Hospital, Marrakesh, Morocco.

Authors' contributions

This work was carried out in collaboration among all authors. All authors read and approved the final manuscript.

Article Information

DOI: 10.9734/CA/2022/v11i4301

Open Peer Review History:

This journal follows the Advanced Open Peer Review policy. Identity of the Reviewers, Editor(s) and additional Reviewers, peer review comments, different versions of the manuscript, comments of the editors, etc are available here: <https://www.sdiarticle5.com/review-history/94426>

Received 12 October 2022
Accepted 16 December 2022
Published 21 December 2022

Case Study

ABSTRACT

The present study describes a case of a 24-year-old who had an asymptomatic acute dissection of the abdominal sub-renal aorta along with an inflammatory syndrome suggestive of Takayasu disease. Aortic dissection is a rare complication of Takayasu's disease that has only been reported a few times in the literature. The type of aortic dissection (type III b, according to the classification of De Bakey and Stanford) confirmed by computed tomography scan of the aorta (CT scan) in our patient. The patient underwent conservative medical treatment.

Keywords: Takayasu's disease; asymptomatic aortic dissection; abdominal sub renal aorta; CT scan.

1. INTRODUCTION

A large vessel vasculitis affecting the aorta and its main branches is known as Takayasu's arthritis (TA). Aneurysmal disease caused by inflammatory bulges in the arterial wall or an

absent pulse (pulse less disease) are two different clinical presentations. Aortic dissection (AD) is a relatively uncommon feature of TA, according to the literature [1]. In this report, a 24-year-old woman presents with an acute complicated type of AD.

*Corresponding author: E-mail: hindnabawi1@gmail.com;

2. CASE PRESENTATION

A 24 years old female, with a history of anemia in childhood that was not investigated. She presented to the emergency room for a mandibular fracture secondary to an aggression requiring maxilomandibular fixation, with the fortuitous discovery, before the surgical procedure, of a severe arterial hypertension, blood pressure in the right upper limb was 180/100 mmHg requiring to cancel the procedure. The patient did not report any chest pain or abdominal pain.

On clinical examination the patient had a blood pressure asymmetry between the 2 upper limbs. Blood Pressure =158/80 mmHg right upper limb and 94/61mmHg left upper limb, Heart Rate= 75 bpm, without murmur on cardiac auscultation with bilateral carotid bruit, left subclavian bruit, she had also bruit at the abdominal level and at the renal arteries course. She had an intermittent claudication of both lower limbs, the peripheral pulses were decreased in both lower limbs without signs of ischemia (right systolic pressure index= 0.8, left systolic pressure index= 0,9) with a decrease in the left radial pulse compared to the right side. The rest of the clinical examination: pulmonary, neurological, osteoarticular and dermatological was unremarkable.

Electrocardiogram is in regular sinus rhythm at 75bpm, electrical left ventricular hypertrophy with Cornell score at 25 mm.

A thoraco-abdominal CT scan was performed urgently with diffuse intimal thickening of the thoraco-abdominal aorta (Fig. 1), raising the suspicion of vasculitis, responsible for a significant stenosis of the left common carotid artery(CCA), thrombosis of the right primary iliac artery (Fig. 2) with the presence of a 14-mm dissection of the supra- and sub-renal abdominal aorta lateralized on the right (Fig. 3).

Emergency surgery was ruled out because of the location of the dissection and the absence of ischemic manifestations.

Arterial Doppler of the supra-aortic vessels and upper extremities:

Right side:

- Common carotid artery(CCA): diffuse parietal thickening of 2.2 mm, with subocclusion at its middle part with moderately demodulated flow downstream (Figs 5 , 6).
- Internal carotid artery (ICA): diffuse parietal thickening without significant stenosis, with good flow

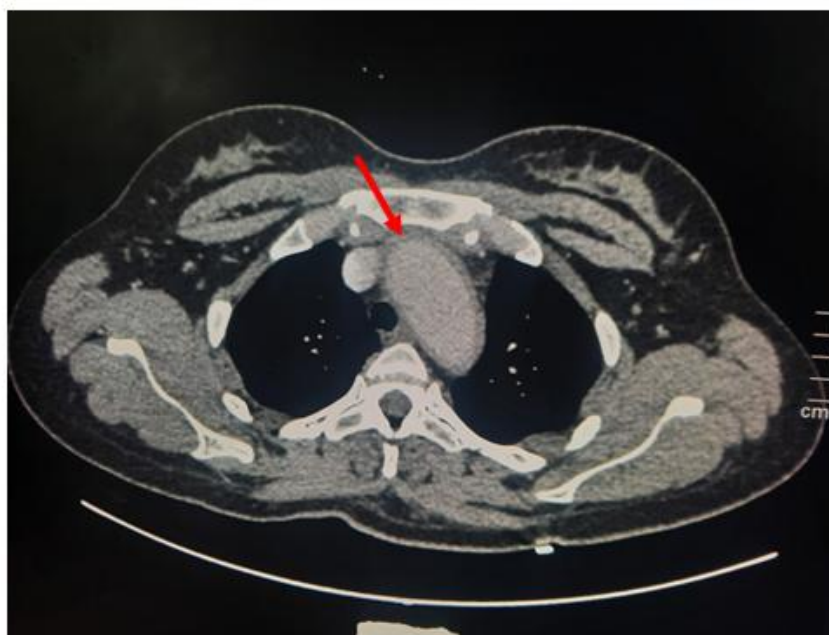

Fig. 1. CT scan of the thoracic aorta showing a diffuse intimal thickening of the aortic arch

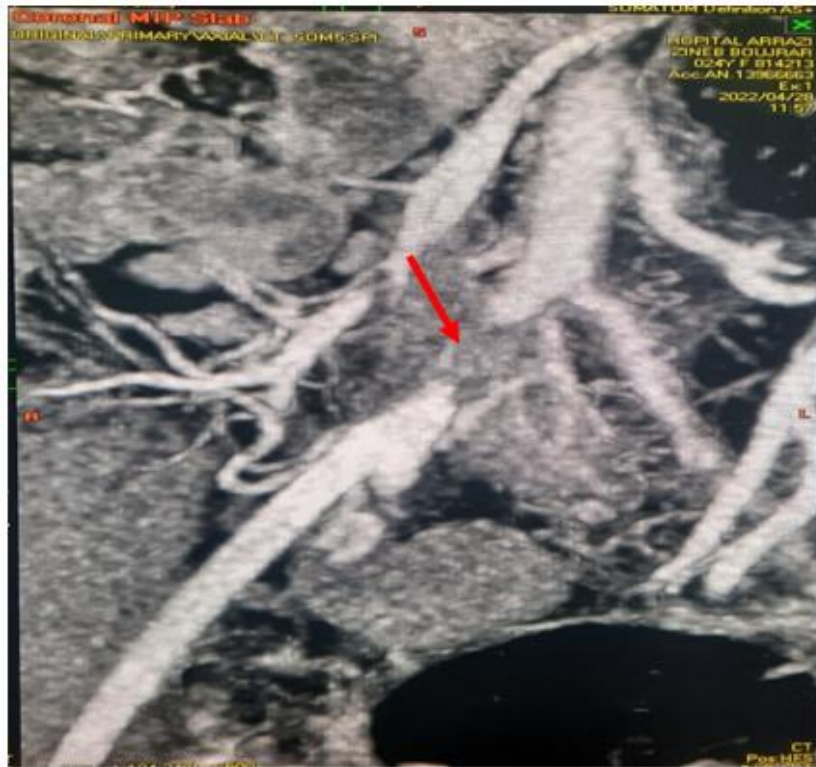

Fig. 2. CT scan of the abdominal aorta showing a thrombosis of the right primary iliac artery

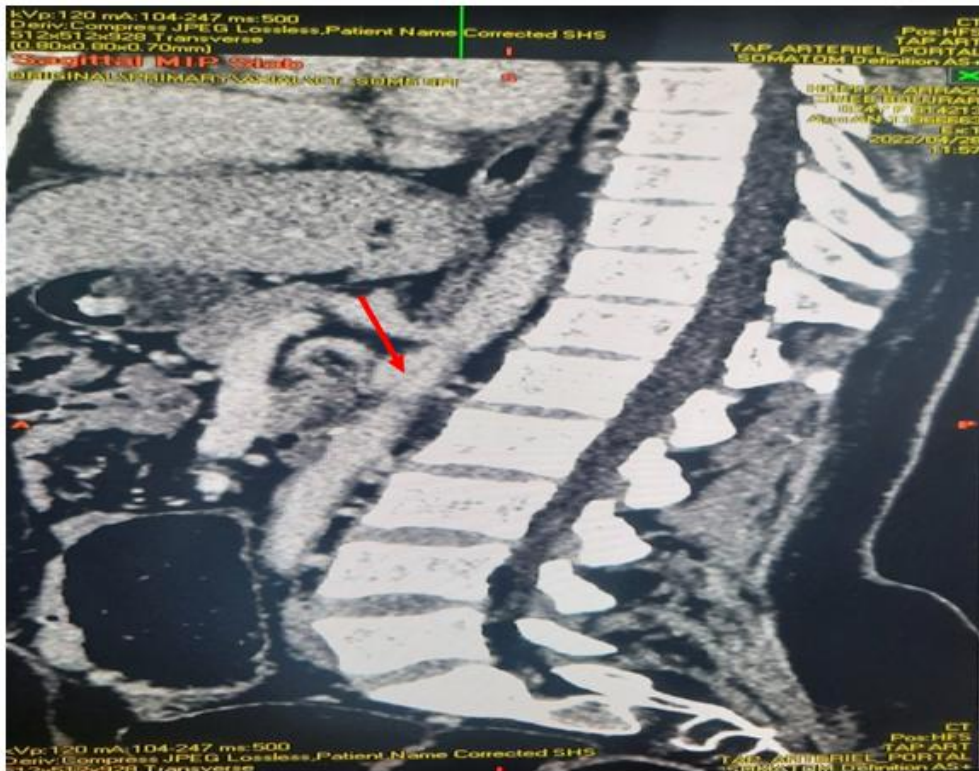


Fig. 3. CT scan showing the presence of a 14-mm dissection of the supra- and sub-renal abdominal aorta lateralized on the right

Left side :

- Common carotid artery(CCA): significant parietal thickening with demodulated flow with presence of collateral circulation
- Internal carotid artery (ICA) and external carotid artery(ECA): diffuse parietal thickening without stenosis with moderate demodulated flow
- Subclavian : tight stenosis at its origin , peak systolic velocity (PVS) at 639 cm/s with demodulated flow downstream (Fig. 4)
- Radial artery : normal flow but decreased compared to the right
- Brachial artery : no stenosis with moderate demodulated flow

Abdominal aorta echography:

- Supra-renal abdominal aorta: Diffuse parietal thickening with normal flow.
- Sub renal aorta: Presence of a tight stenosis with presence of collaterally

Trans-thoracic echocardiography noted left ventricle normal in size but hypertrophied and good contraction with ejection fraction at 64% .There is Moderate Aortic regurgitation (Fig. 7). Aortic root, ascending aorta and the aortic arch measured respectively: 32 mm, 32 mm and 37 mm (Figs. 8, 9).

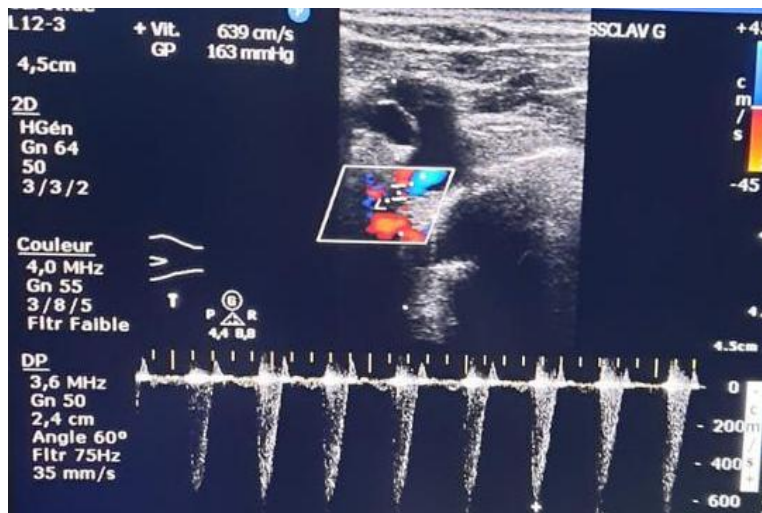


Fig. 4. Stenosis of the left subclavian artery PVS=639 cm/s

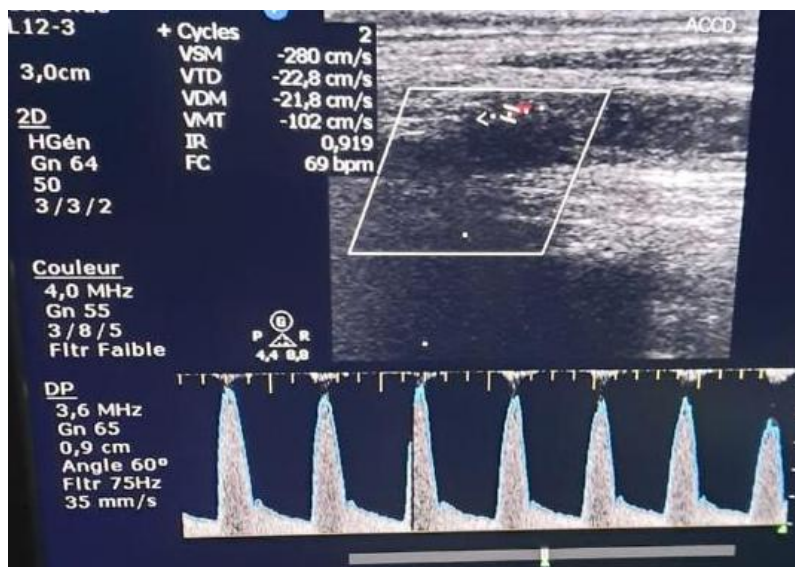


Fig. 5. Tight stenosis of the right common carotid artery with circumferential intimal thickening

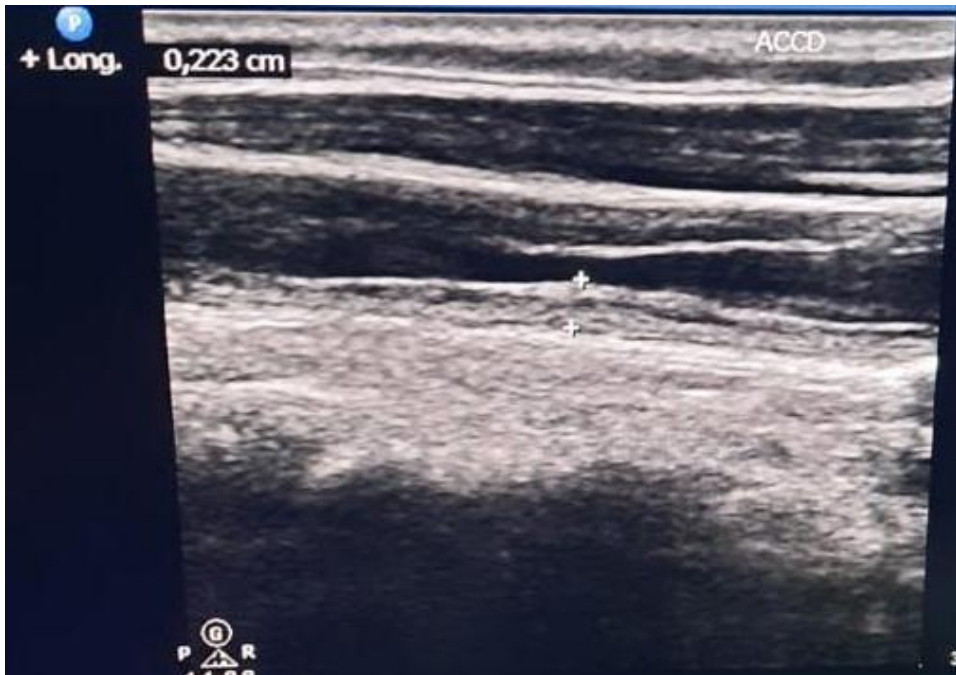

Fig. 6. Circumferential parietal thickening of the right common carotid artery of 2 mm

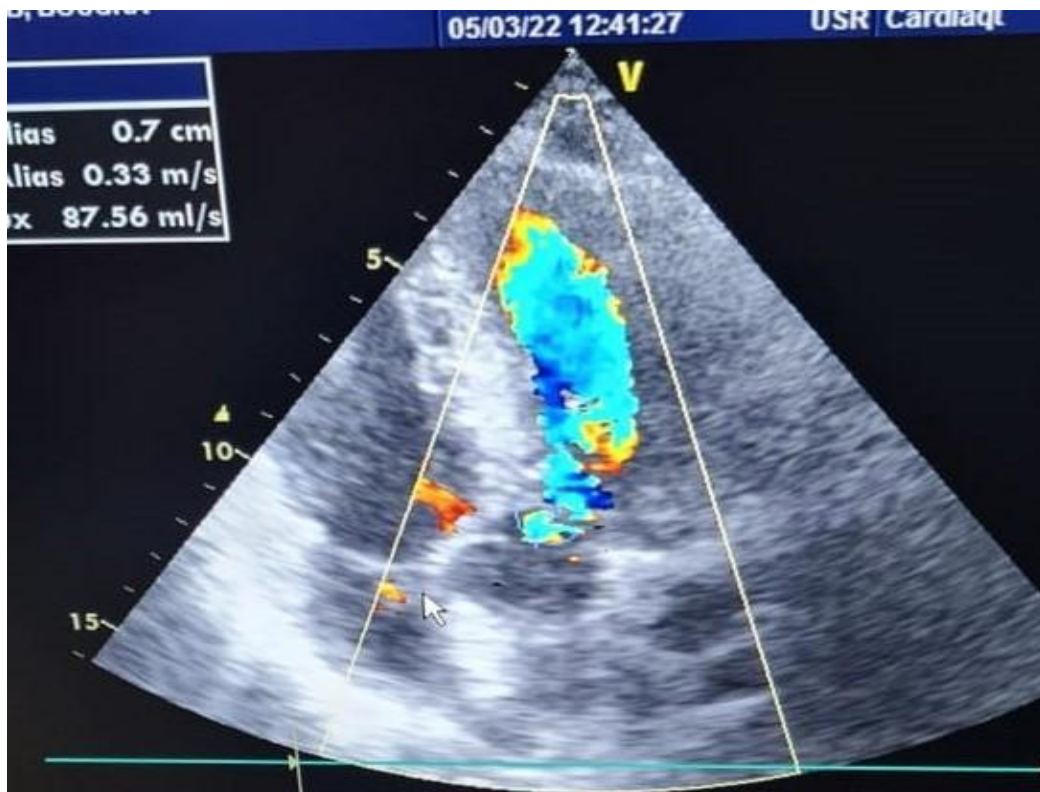


Fig. 7. Transthoracic echocardiography in the apical 5-chamber view showing a Moderate Aortic regurgitation

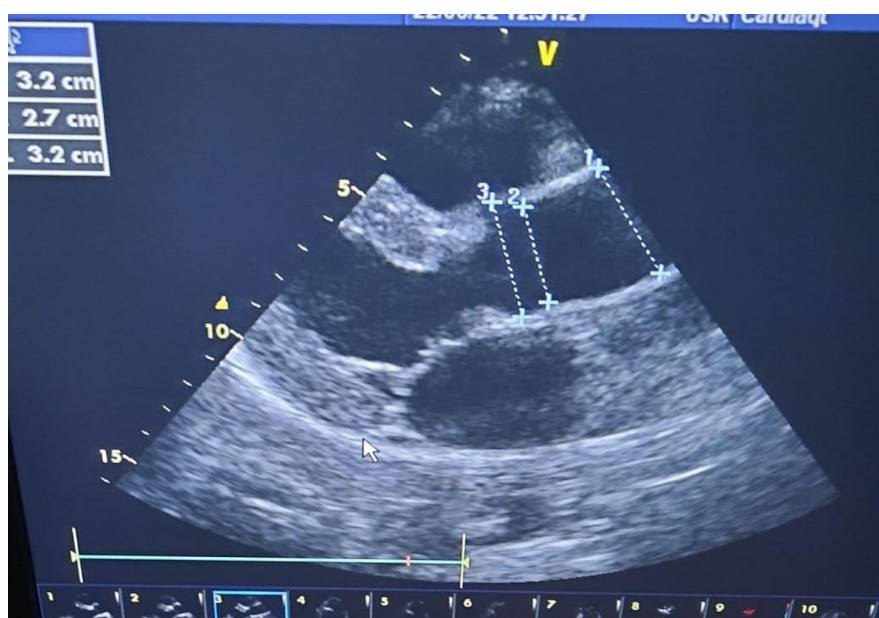


Fig. 8. Transthoracic echocardiography in the Parasternal long axis view demonstrating the diameters in diastole of aortic root [3] and tubular ascending aorta [1] (both at 32 mm)

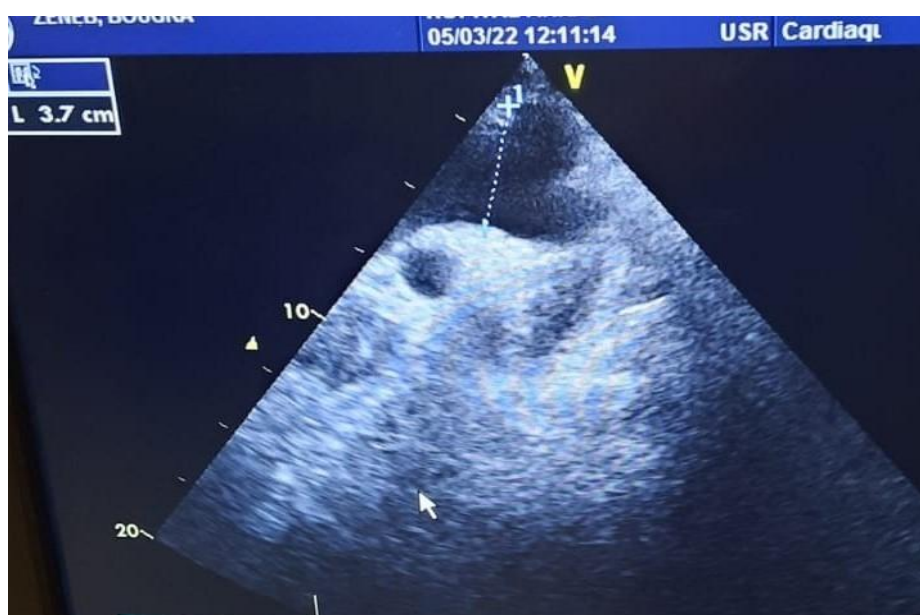


Fig. 9. Transthoracic echocardiography in suprasternal view demonstrating the diameter of aortic arch at 37 mm [1]

Biological check-up: normocytic normochromic anemia at 10.1g/dl, White blood cells: 9460 g/dl , platelet cells: 357000, inflammatory work-up: C-reactive protein (CRP) elevated to 42.9mg; ferritinemia: 33; accelerated sedimentation rate (VS) at 79mm first hour; normal hepatic work-up, normal renal function, negative viral serologies and negative immunological tests.

At the end of the clinical and paraclinical examination and considering the criteria of the American College of Rheumatology, the diagnosis of Takayasu disease was retained. Medical treatment was based on corticosteroid therapy 1mg/kg/d with adjuvant treatment + Methotrexate 25mg/week, with control of heart rate and blood pressure by calcium channel blockers and beta-blockers.

The evolution was marked by clinical improvement with blood pressure and biological control (inflammatory work-up), the control CT scan showed the same radiological image. The progressive decrease of the corticosteroid therapy was started after one month of initial treatment, with biological and radiological monitoring.

3. DISCUSSION

According to the American College of Rheumatology classification criteria, which were primarily intended to distinguish this disorder from other types of vasculitis, this patient had a classic clinical and arteriography finding of TA [2]. These criteria, include:

- 1) Age of onset younger than 40 years;
- 2) Claudication of the extremities;
- 3) Decreased pulsation of one or both brachial arteries;
- 4) Difference of at least 10 mmHg systolic pressure between arms;
- 5) Bruits over one or both subclavian arteries or the abdominal aorta; and
- 6) Arteriography narrowing or occlusion of the entire aorta, its primary branches, or large arteries in the proximal upper or lower extremities, not caused by arteriosclerosis, fibro muscular dysplasia, or other causes.

The diagnosis is most likely when three of these six criteria are met [2], our patient had 6 criteria [1-5 and 6] of these criteria. In addition, clinical and serological workups did not support the presence of other large-vessel or medium-vessel vasculitis.

Other than non specific inflammatory symptoms, TA maybe complicated by either ischemic symptoms attributed to stenotic lesions or by aortic wall disruption, dilation, and dissection [3]. The risk of arterial vessel wall dissection, a rare but potentially fatal complication that is less frequent in paediatric than in adult TA, may be increased by systemic hypertension. Discrepancy of any of four limbs blood pressure >10 mm Hg (which constitutes a classification criteria) as well as bruits over aorta and its major branches are present in over 50% of patients. Takayasu disease makes it unusual and difficult for an aortic type B dissection to occur because the vessel's wall has significantly thickened, making it resistant to rupture or dissection and frequently challenging to treat using traditional surgical techniques [4].

“Diagnostic evaluation of vasculitis relies on non-invasive imaging: color Doppler ultrasound is the method of choice for evaluating aortic vessel involvement, whereas computed tomography and cardiovascular magnetic resonance are useful in assessing the thoracic and abdominal aorta; positron emission tomography imaging allows direct visualization of the extent of vascular inflammation” [5].

An arterial segment's mural thickening, which usually forms the "macaroni" sign and is circumferential and greater than 3 mm, is the key imaging finding. This feature is prevalent in the carotid and subclavian arteries, where it is found at 97% in the pre-occlusive phase [6,7].

Our patient presents a non-aneurysmal and asymptomatic dissection Stanford type B of the sub renal aorta sparing the iliac arteries (Fig. 1). Dissection Stanford type B is more frequent than type A in association with Takayasu disease [8].

“Medical treatment for Takayasu aortitis includes steroids and immunosuppressive drugs; recently. The goal of the medical treatment is inflammatory arterial decrease with the use of immunosuppressors: 50% respond to steroids and 50% to methotrexate. Many new biological agents have been discovered for refractory cases, such as the interleukin-6 inhibitor tocilizumab” [9]. In our case, methotrexate induced an improvement in the inflammatory parameters (erythrocyte, sedimentation rate, CRP); however, clinical and radiological signs remain stable.

For patients with uncomplicated cases, the most recent consensus document on the management of type-B aortic dissection suggests medical care and imaging follow-up [10]. Aortic dissection complicating Takayasu disease has unclear surgical treatment indications that are predominately ischemic in nature. However, it is advised to proceed with the surgery after the disease's inflammatory phase [11].

4. CONCLUSION

It is concluded that the patient from our clinic who had an abdominal aortic dissection is an illustration of the variety of vascular lesions seen in TA. A team composed of surgeons with experience treating this condition, pathologists, and medical experts in vascular pathologies should manage young patients with aortic dissection in order to provide highly individualised treatment and follow-up plans.

CONSENT

As per international standard or university standard, patient(s) written consent has been collected and preserved by the author(s).

ETHICAL APPROVAL

As per international standard or university standard written ethical approval has been collected and preserved by the author(s).

COMPETING INTERESTS

Authors have declared that no competing interests exist.

REFERENCES

1. Mason JC. Takayasu arteritis – advances in diagnosis and management. *Nat Rev Rheumatol*. 2010;6:406–415.
2. Arend WP, Michel BA, Bloch DA, Hunder GG, Calabrese LH, Edworthy SM, et al. The American College of Rheumatology 1990 criteria for the classification of Takayasu arteritis. *Arthritis Rheum*. 1990;33:1129–34.
3. Isobe M. Takayasu arteritis revisited: Current diagnosis and treatment. *Int J Cardiol*. 2013;168:3–10. DOI: 10.1016/j.ijcard.2013.01.022. 2
4. Tyagi S, Nigam A. Aortic dissection: A rare presenting manifestation of Takayasu's aortitis. *Indian Heart J*. 2008;60:58–60.
5. Czihal M, Förster S, Hoffmann U. Imaging diagnostics of large vessel vasculitis [in German]. *Radiologe*. 2010;50:855–860. DOI: 10.1007/s00117-010-2001-1
6. Mirault T, Messas E. La maladie de Takayasu. *Rev Med Int*. 2016;37(4):223–9.
7. Ma LY, Li CL, Ma LL, Cui XM, Dai XM, Sun Y, et al. Value of contrast-enhanced ultrasonography of the carotid artery for evaluating disease activity in Takayasu arteritis. *ArthritisResTher*. 2019;21:24.
8. Yang KQ; Yang YK; Meng X; Zhang Y; Zhang, HM. Aortic Dissection in Takayasu Arteritis; 2017.
9. Loricera J, Blanco R, Castañeda S, Humbría A, Ortego-Centeno N, Narváez J, et al. Tocilizumab in refractory aortitis: study on 16 patients and literature review. *Clin Exp Rheumatol*. 2014;32(3 suppl 82):S79–S89.
10. Fattori R, Cao P, De Rango P, Czerny M, Evangelista A, Nienaber C, et al. Interdisciplinary expert consensus document on management of type B aortic dissection. *J Am Coll Cardiol*. 2013;61:1661–78.
11. Theresa K, Jean-Marc A, Jean-Paul DVH, Jean EF. Diagnosis and surgical treatment of a Takayasu disease on an abdominal aortic dissection. *Ann VascSurg*. 2011; 25:556

© 2022 Nabawi et al.; This is an Open Access article distributed under the terms of the Creative Commons Attribution License (<http://creativecommons.org/licenses/by/4.0>), which permits unrestricted use, distribution, and reproduction in any medium, provided the original work is properly cited.

Peer-review history:

The peer review history for this paper can be accessed here:

<https://www.sdiarticle5.com/review-history/94426>