



A Case Study of Secondary Synovial Osteochondromatosis of Knee

**Mohit Gera ^a, Basant Rai ^{a#}, Parminderjeet Singh Bhullar ^{a*o},
Ashish Shukla ^b, Dixit Bansal ^{a‡}, Vishal Preet Singh ^{a‡}
and Ashish Chauhan ^{a‡}**

^a Department of Orthopedics, GMC, Amritsar, India.

^b Department of Pulmonary Medicine, GMC, Patiala, India.

Authors' contributions

This work was carried out in collaboration among all authors. All authors read and approved the final manuscript.

Article Information

Open Peer Review History:

This journal follows the Advanced Open Peer Review policy. Identity of the Reviewers, Editor(s) and additional Reviewers, peer review comments, different versions of the manuscript, comments of the editors, etc are available here: <https://www.sdiarticle5.com/review-history/90953>

Received 17 June 2022

Accepted 29 August 2022

Published 23 September 2022

Case Report

ABSTRACT

Synovial osteochondromatosis (SOC) is a proliferative synovial disease. Which has a rare incidence and presents as numerous osteo-cartilaginous nodules in bursae, synovial joints and tendon sheaths. Diagnostic modalities for synovial chondromatosis include radiographs, CT scan or MRI, with definitive characteristics being determined by histological examination. Therapeutic options commonly include either arthroscopic or open procedures which prevent further articular and peri-articular damage and abolish symptoms. The following case report describes a 42 year male patient presenting with a secondary synovial osteochondromatosis of knee managed successfully with open procedure for the removal of the loose bodies.

Keywords: Synovial osteochondromatosis; intra-articular loose bodies; benign.

1. INTRODUCTION

“Synovial osteochondromatosis (SOC) is a proliferative synovial disease usually affecting a single joint. Rare in incidence, it usually present

as multiple osteo-cartilaginous nodules in bursae, synovial joints and tendon sheaths” [1-3]. Although generally a primary condition, it can occur secondary to osteoarthritis of the affected joint. This disease is prevalent between fourth to

^o Senior Resident;

[#] Associate Professor;

[‡] Junior Resident;

*Corresponding author: Email: bhullarparminder1@gmail.com;

fifth decades. Males are more frequently affected than females [1].

“Synovial chondromatosis commonly manifests in single large joints, which includes the knee, hip, elbow, shoulder, ankle, etc” [4]. “However, it may occasionally affect smaller joints, including the distal radioulnar, tibio-fibular, metacarpophalangeal and metatarsophalangeal joints” [5-8]. “Patients with synovial chondromatosis may either be relatively asymptomatic or may present with pain, swelling and restriction of functional movements of the involved joints” [8]. “The etiology factors associated with the disease are uncertain. Synovial chondromatosis generally presents with decreased range of motion, palpable swelling, effusion, and crepitus” [9]. “Milligram classified synovial chondromatosis into three distinct phases: Early phase (active intra-synovial disease without loose bodies), transitional phase (active disease with loose bodies), and late phase (multiple loose bodies but with no intra-synovial disease)” [10]. Clinical management of the condition is usually surgical and involves either open or arthroscopic procedure [11] to prevent further articular and peri-articular damage and to relieve symptoms [12]. “Diagnostic modalities for synovial chondromatosis include radiographs, CT scan or MRI, with definitive characteristics being determined by histological examination” [13]. “However, radiography is the most commonly used diagnostic method, as it can identify ossified nodules” [14].

The following study illustrates synovial osteochondromatosis of the knee in a patient with conventional symptoms.

2. CASE REPORT

42-year-old gentleman, farmer by profession, presented to the OPD of the Department of Orthopedics, Government Medical College, Amritsar complaining of pain and swelling left knee for 1 year. The patient reports that the pain started around a year back and progressed from a sporadic type of pain to become continuous and with increasing intensity. The swelling was progressive and led to restriction of movement of the knee from the last 3 months. The patient had great difficulty during the functional range of movements his left knee.

On physical examination, the patient presented with a reduced range of motion and a diminished muscle power.

Patient had a previous history of spinal injury 22 years back due to a fall from height, leading to bilateral lower limb weakness. This gradually led to the development of hip and knee flexion contractures of the left lower limb for which contracture release was performed on the left knee at a private hospital.

Radiographic images of the knee were ordered and these showed an osteoblastic mass in and around the knee joint. For superior explication of the diagnosis, MRI scan of the left knee was requested. This demonstrated numerous similar sized intra-articular loose bodies (largest measuring 4x2.8 cm) of variable signal intensity in the knee joint, supra-patellar bursa, and popliteal fossa, with signs of osteoarthritis grade IV with secondary synovial chondromatosis.

The patient was treated with an open surgical procedure, with total excision of the affected synovium and the removal of the associated loose bodies, which were sent for histopathological examination. Post-operatively skin traction was applied to the limb and physiotherapy was initiated. Two weekly follow-up was done following the operative procedure, and the patient's functional range of motion in this left knee had improved.

The report of the histopathological examination confirmed that this was a case of synovial chondromatosis.

3. DISCUSSION

“Synovial chondromatosis is a benign, infrequent mono-articular neoplasm with an unknown etiology. It can originate from any structure that has synovial tissue. The disease is described by cartilaginous nodule formation secondary to metaplasia of the synovium. These nodules may later get calcified apart from synovial tissue. Although it is generally progressive, it can be self limiting and may regress on its own” [3].

The natural course of synovial chondromatosis includes three phases. Phase 1-.Metaplastic changes of synovium with active synovitis but with absence of loose bodies. Phase 2- Active synovial disease along with the formation of cartilaginous loose bodies. Phase 3- calcification of loose bodies with subsidence of synovitis [2]. Primary synovial chondromatosis is a very rare mono-articular synovial disease [10]. “Secondary synovial chondromatosis is common, where articular cartilage is shred from the surface and

found as loose bodies in the joint. Extra-articular synovial chondromatosis is rare and can be classified as bursal chondromatosis or tenosynovial chondromatosis depending on the site of origin” [15]. “The radiologic features of disease can vary according to the stage of the disease. In the first stage, the swelling is only around the involved joint” [16]. “The most common radiographic finding is the radiopaque free bodies of varying sizes, which can be seen at any site in the joint cavity” [17]. “Calcification of the cartilaginous loose bodies occurs at the

last stage and may not be evident in every patient” [18]. Matsumoto et al. [19] reported that “the MRI scan is much more helpful than CT scan for the disease. Loose bodies on MRI exhibit a low signal intensity on T1-weighted images and a high signal intensity on T2-weighted images, although there may be a low signal intensity on all images when there is extensive mineralization of the loose bodies” [20] Ultrasound also is an useful diagnostic tool that can show multiple echogenic loose bodies, effusion, and synovial hypertrophy [20].

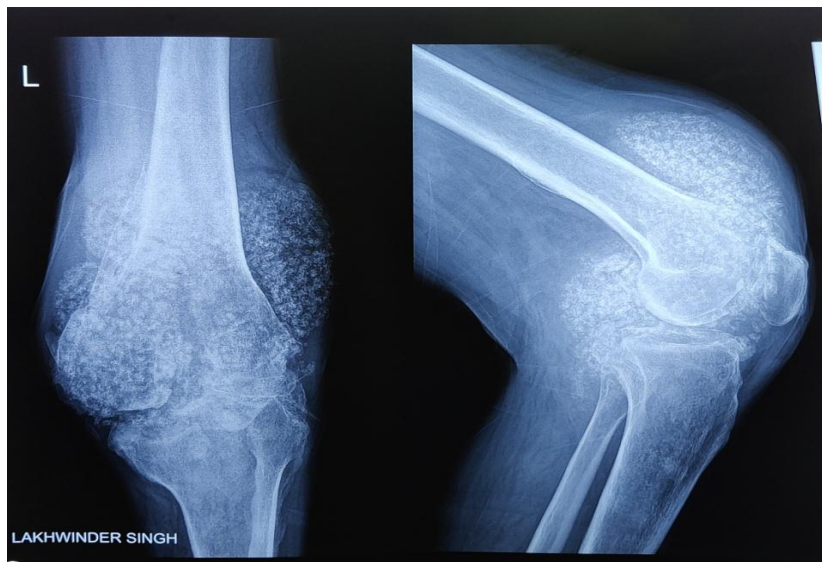
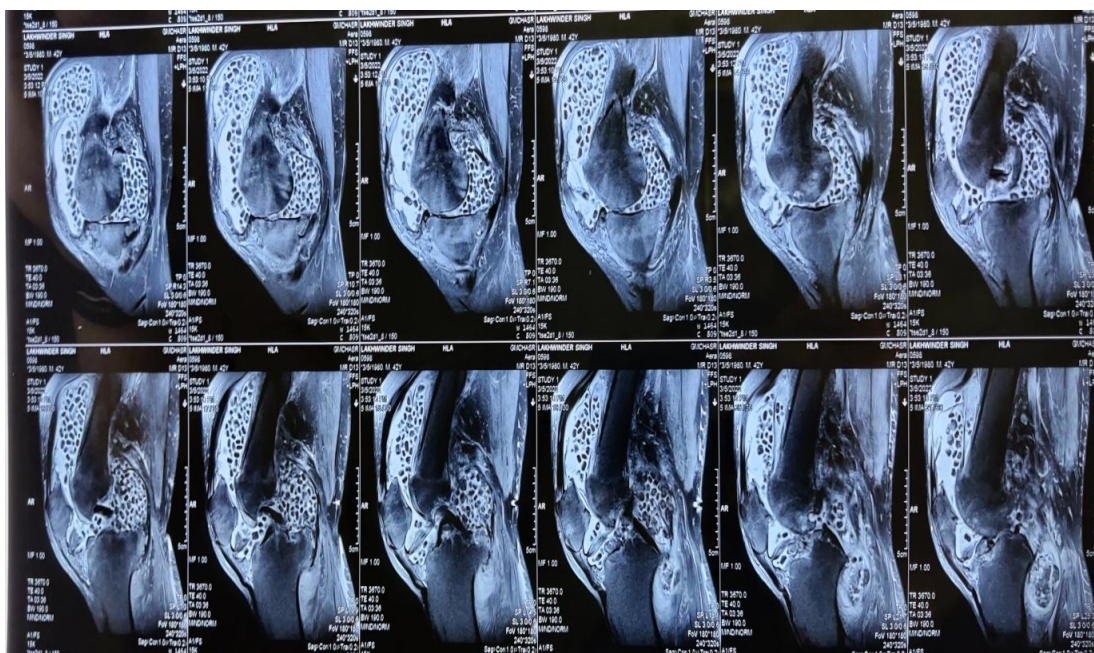
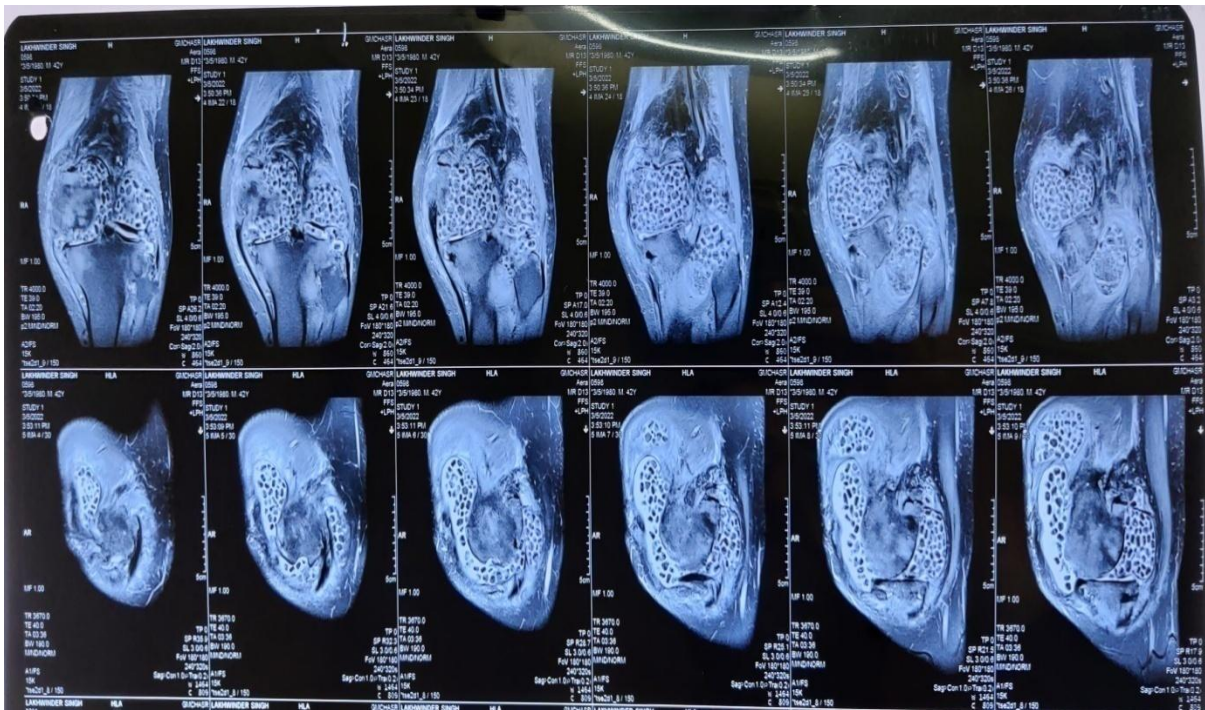

Fig. 1. Pre operative X-ray

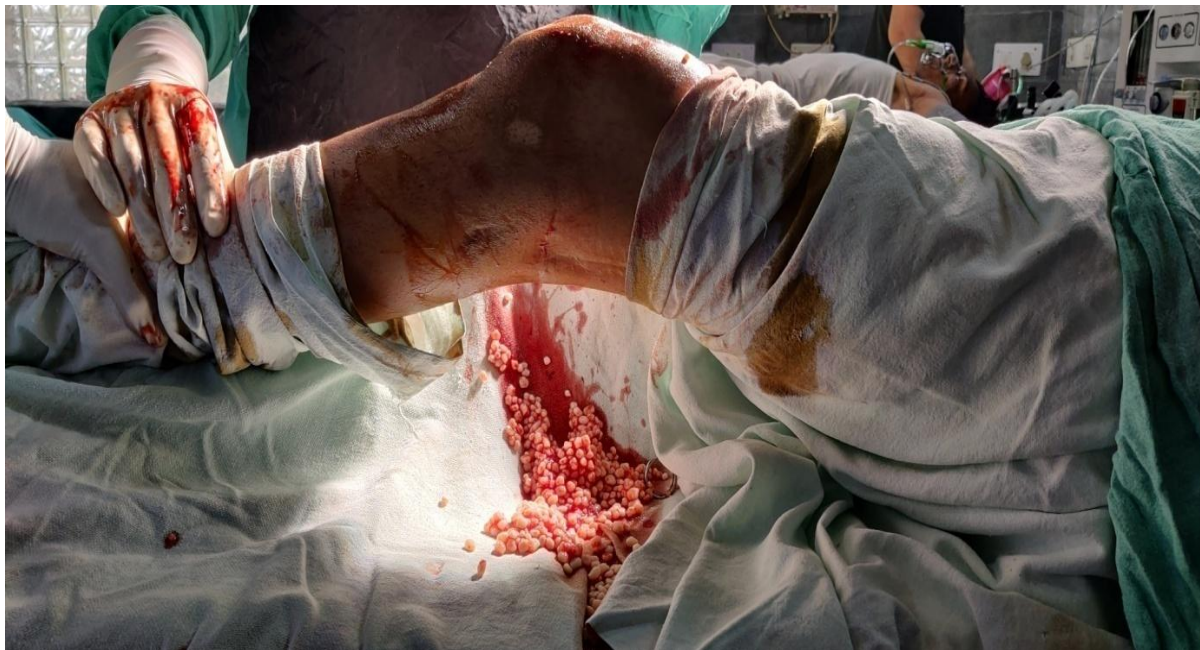

(A)

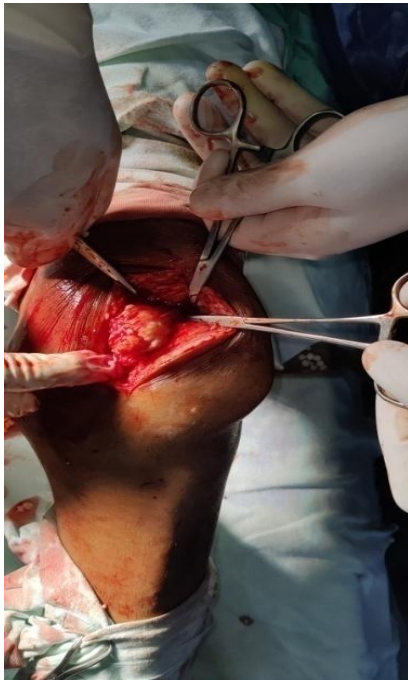


(B)

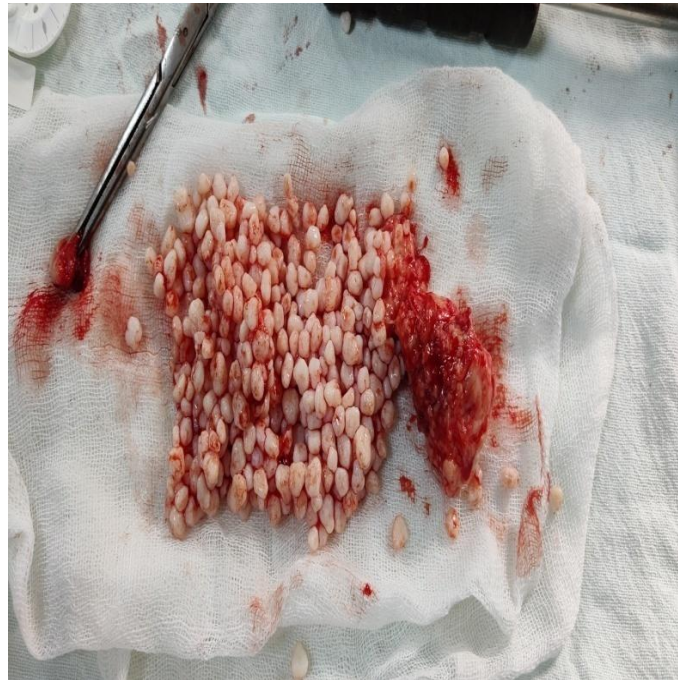Fig. 2(A-B). Pre operative MRI demonstrating numerous osteochondral loose bodies in and around the knee joint



(A)



(B)



(C)

Fig. 3(A-C). Intra operative pictures showing multiple loose bodies

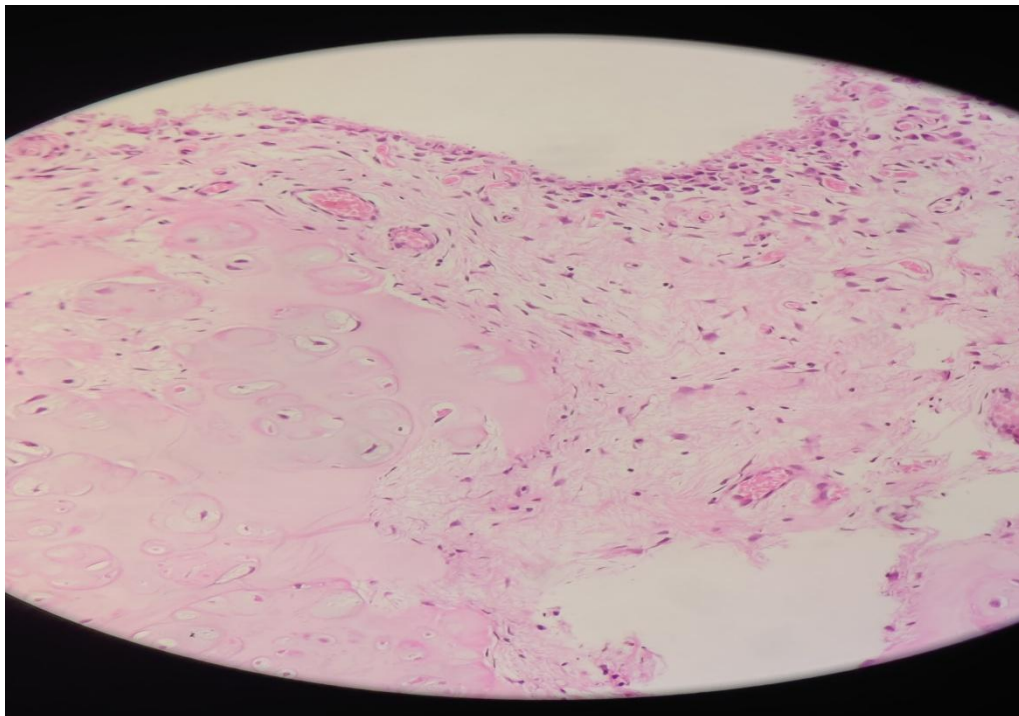


Fig. 4. Histopathological image of the biopsy specimen showing synovial chondromatosis with active synovitis

The differential diagnosis include synovial hemangioma, synovial cyst, pigmented villonodular synovitis (PVNS), lipoma arborescence, and malignant neoplasms, such as synovial sarcoma or synovial chondrosarcoma [19]. Patients typically present with an insidious onset and gradually increasing mechanical symptoms, such as pain (> 85% of cases), swelling (42%-58%), and reduced motion (38%-55%) of the affected joint [20-22].

“Arthroscopy has circumspectly replaced the traditional incision surgery, as it requires only a small skin incision and causes very little pain; patients exhibit a faster post-operative recovery and arthroscopic removal of the diseased tissue is more effective treatment than loose body removal alone” [23,24]. Urbach et al. [25] proclaimed that “the loose body removal, combined with localized synovectomy, was able to remove the abnormal synovial tissue and prevent a recurrence”.

4. CONCLUSION

In inference, Synovial osteochondromatosis with monoarticular involvement is a very rare disease. The clinical diagnosis is quite tough. The clinical, radiological, and histological findings should be correlated for reaching to a diagnosis. After the diagnosis synovial excision, as complete as possible, removal of loose bodies, and a close follow-up are warranted.

CONSENT

As per international standard or university standard, patients' written consent has been collected and preserved by the author(s).

ETHICAL APPROVAL

As per international standard or university standard written ethical approval has been collected and preserved by the author(s).

COMPETING INTERESTS

Authors have declared that no competing interests exist.

REFERENCES

1. Dahlin DC, Murphy FP, Sullivan CR. Articular synovial chondromatosis. *J Bone Joint Surg Am.* 1962;44:77-86.

2. Milgram JW. Synovial osteochondromatosis: A histopathological study of 30 cases. *J BoneJoint Surg Am.* 1977; 59(6):792-801.

3. Maurice H, Crone M, Watt I. Synovial chondromatosis. *J BoneJoint Surg Br.* 1988;70(5):807-11.

4. Roberts D, Miller TT, Erlanger SM. Sonographic appearance of primary synovial chondromatosis of the knee. *J Ultrasound Med.* 2004;23:707-709.

5. Von Schroeder HP, Axelrod TS. Synovial osteochondromatosis of the distal radio-ulnar joint. *J Hand Surg Br.* 1996;21: 30-32.

6. Batheja NO, Wang BY, Springfield D, Hermann G, Lee G, Burstein DE, Klein MJ. Fine-needle aspiration diagnosis of synovial chondromatosis of the tibiofibular joint. *Ann Diagn Pathol.* 2000;4:77-80.

7. Warne BA, Tigrani DY and Ward CM. Metacarpophalangeal joint synovial osteochondromatosis: A case report. *Iowa Orthop J.* 2008;28:91-93.

8. Tagliavero G, Moro S, Stecco C, Pennelli N. Bilateral synovial chondromatosis of the first metatarsophalangeal joint: A report case. *Reumatismo.* 2011;55:263-266.

9. Temple HT, Gibbons CL. Tumors and tumor-related conditions about the knee. *Oxford Textbook of Orthopaedics and Trauma Oxford: Oxford University Press.* Bulstrode C, Buckwalter J, Carr A, Marsh L, Fairbank J, Wilson-Macdonald J, Bowden G. 2002;1(2):1153-4.

10. Ackerman D, Lett P, Galat DD Jr, Parvizi J, Stuart MJ. Results of total hip and total knee arthroplasties in patients with synovial chondromatosis. *J Arthroplasty.* 2008;23:395-400.

11. Yu GV, Zema RL, Johnson RW. Synovial osteochondromatosis. A case report and review of the literature. *J Am Podiatr Med Assoc.* 2002;92:247-254.

12. Neumann JA, Garrigues GE, Brigman BE, Eward WC. Synovial Chondromatosis. *JBJS Rev.* 2016;4. PII: 01874474-201605000-00005

13. Varol A, Sencimen M, Gulses A, Altug HA, Dumlu A, Kurt B. Diagnostic importance of MRI and CT scans for synovial osteochondromatosis of the temporomandibular joint. *Cranio.* 2011;29: 313-317.

14. Xie S, Nevis J, Lezmi S. Pathology in practice. Chondro-osseous metaplasia consistent with synovial chondromatosis

- a great horned owl. J Am Vet Med Assoc. 2014;245:767-769.
15. Symeonides PJ. Bursal chondromatosis. J Bone Joint Surg Br. 1966;48:371-3.
 16. Hsueh CJ, Huang GS, Juan CJ, Wang SG, Liou CH, Hsiao HS et al. Synovial chondroma of the ankle in a young child after recent trauma. CT and MR features. Clin Imaging. 2001;25(4):296-9.
 17. Kural C, Akyildiz MF, Erturk H, Bayraktar K. Synovialchondromatosis of the ankle joint and elbow in two cases. Acta Orthop Traumatol Turc. 2005;39(5):441-4.
 18. Mussey RD Jr, Henderson MS. Osteochondromatosis. J Bone Joint Surg (Am). 1949;31(3):619-27.
 19. Matsumoto H, Kawakubo M, Otani T, Fujikawa K. Extensivepost-traumatic ossification of the patellar tendon: A report of two cases. J Bone Joint Surg. 1999; 81(1):34-6.
 20. Giancane G, Tanturri de Horatio L, Buonomo PS, Barbuti D, Lais G, Cortis E. Swollen knee due to primary synovial chondromatosis in pediatrics: A rare and possibly misdiagnosed condition. Rheumatol Int. 2013;33(8): 2183-2185.
 21. Serbest S, Tiftikçi U, Karaaslan F, Tosun HB, Sevinç HF, Balci M. A neglected case of giant synovial chondromatosis in knee joint. Pan Afr Med J. 2015;22:5.
 22. Hallam P, Ashwood N, Cobb J, Fazal A, Heatley W. Malignant transformation in synovial chondromatosis of the knee? Knee. 2001;8(3):239-242.
 23. Samson L, Mazurkiewicz S, Treder M, Wiśniewski P: Outcome in the arthroscopic treatment of synovial chondromatosis of the knee. Ortop Traumatol Rehabil. 2005; 7:391-396.
 24. Ogilvie-Harris DJ, Saleh K. Generalized synovial chondromatosis of the knee: A comparison of removal of the loose bodies alone with arthroscopic synovectomy. Arthroscopy. 1994;10: 166-170.
 25. Urbach D, Mc Guigan FX, John M, Neumann W, Ender SA. Long-term results after arthroscopic treatment of synovial chondromatosis of the shoulder. Arthroscopy. 2008;24:318-323.

© 2022 Gera et al.; This is an Open Access article distributed under the terms of the Creative Commons Attribution License (<http://creativecommons.org/licenses/by/4.0>), which permits unrestricted use, distribution, and reproduction in any medium, provided the original work is properly cited.

Peer-review history:

The peer review history for this paper can be accessed here:
<https://www.sdiarticle5.com/review-history/90953>