



Wandering Spleen in Operated Case of Congenital Diaphragmatic Hernia

**B. V. Musande^a, Arjun Pawar^a, Rajendra Shinde^a,
Nikita N. Marathe^{a++*} and Yash Marathe^a**

^a *Department of General Surgery, MGM College & Hospital, Aurangabad, Maharashtra, India.*

Authors' contributions

This work was carried out in collaboration among all authors. All authors read and approved the final manuscript.

Article Information

DOI: 10.9734/AJPR/2024/v14i1315

Open Peer Review History:

This journal follows the Advanced Open Peer Review policy. Identity of the Reviewers, Editor(s) and additional Reviewers, peer review comments, different versions of the manuscript, comments of the editors, etc are available here: <https://www.sdiarticle5.com/review-history/110510>

Case Report

Received: 22/10/2023
Accepted: 28/12/2023
Published: 06/01/2024

ABSTRACT

Wandering spleen (WS) is a rare condition characterized by abnormal mobility of the spleen due to laxity or absence of its supporting ligaments. We report an exceptional case of WS in a pediatric patient who had previously undergone surgical repair for congenital diaphragmatic hernia (CDH). A 16-year-old male, with a history of CDH repair in infancy, presented with a two-day history of abdominal pain and vomiting. Clinical examination revealed abdominal distension, tenderness, and sluggish bowel sounds. Imaging studies, including a contrast-enhanced computed tomography (CECT) scan, indicated small bowel obstruction due to an internal hernia, potentially involving the foramen of Winslow. Intriguingly, the patient's spleen had migrated to the left iliac fossa, accompanied by partial thrombosis of the splenic vein. Surgical intervention was deemed necessary. During exploratory laparotomy, the patient was found to have a reversed anatomy, with the ascending colon, cecum, and appendix on the left side, and the small bowel on the right side. Additionally, a WS was discovered with a long and tortuous splenic vein and artery. Surgical procedures included adhesiolysis, primary closure of serosal tears, splenopexy for spleen repositioning, and bowel derotation. The patient's postoperative recovery was uneventful, and he was monitored closely to ensure the resolution of the complications associated with this unique presentation.

⁺⁺ Senior Resident

*Corresponding author: Email: nikita.marathe04@gmail.com;

Keywords: Congenital diaphragmatic hernia; wandering spleen; splenoplexy.

1. INTRODUCTION

Wandering spleen (WS), a rare medical condition, represents the displacement of the spleen from its normal anatomical position due to the laxity or absence of the ligaments that hold it in place. While the wandering spleen is a relatively uncommon occurrence, its association with congenital diaphragmatic hernia (CDH) following surgical correction adds a layer of complexity to its management [1].

CDH is a congenital anomaly characterized by a defect in the diaphragm, allowing abdominal organs to protrude into the chest cavity. CDH is a rare condition, occurring in approximately 1 in 2000 to 1 in 5000 births, affects the development of the lungs, and can lead to life-threatening respiratory distress in neonates. Surgical intervention to repair the diaphragmatic defect is often necessary [2,3].

The coexistence of a wandering spleen and a congenital diaphragmatic hernia presents a unique clinical scenario [4]. This case report delves into the intriguing intersection of congenital diaphragmatic hernia and wandering spleen, shedding light on the complexities and challenges that can arise when managing such unique clinical presentations.

2. CASE PRESENTATION

A 16-year-old male presented to the emergency department with a history of continuous dull abdominal pain and vomiting for two days. Notably, there was no history of obstipation, fever, or trauma. His medical history revealed that he had undergone open surgery for a congenital diaphragmatic hernia at the age of two months; however, no documentation was available regarding the specifics of the procedure.

On examination, the patient displayed slight tachycardia, while other vital signs were normal. On abdominal examination, there was abdominal distension, diffuse tenderness, and sluggish bowel sounds. Biochemical parameters were found to be normal. An x-ray of the abdomen raised suspicions of dilated bowel loops.

Contrast-enhanced computed tomography (CECT) scan of the abdomen and pelvis, indicated small bowel obstruction secondary to an internal hernia, likely involving the foramen of Winslow. The spleen was also observed in the

left iliac fossa, with partial thrombosis of the splenic vein.

The patient was taken for exploratory laparotomy. The surgical approach involved using the previous surgical scar along the left costal cartilage. Intraoperatively, dense inter-bowel adhesions were encountered, along with adhesions of the bowel to the left lobe of the liver and the stomach and to the surgical scar (Fig. 1). Due to the poorly defined anatomy, careful adhesiolysis was performed, resulting in serosal tears at two sites that were subsequently closed primarily using vicryl 3-0 rb sutures.

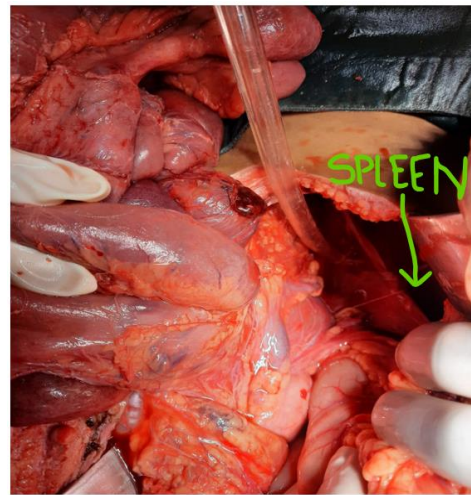


Fig. 1. Intraoperative finding of dense inter-bowel adhesions and splenic vessels visualized with spleen in left iliac fossa

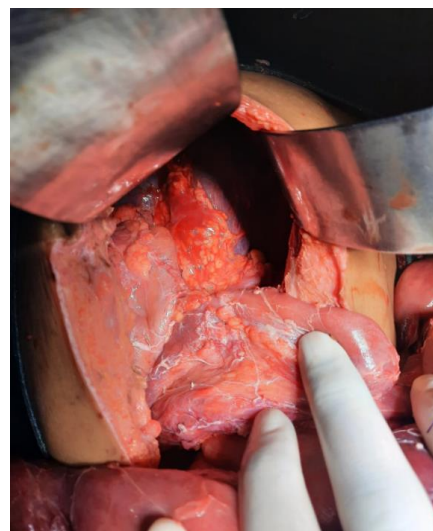


Fig. 2. Spleen in left iliac fossa

We observed that the ascending colon, cecum, and appendix were on the left side of the abdomen, while the small bowel was located on the right side. Additionally, a wandering spleen was identified in the left iliac fossa (Fig. 2), accompanied by a long and tortuous splenic vein and artery. The surgical procedure included splenopexy to reposition the spleen and derotation of the bowel.

The postoperative period was uneventful. Follow-up was arranged to monitor his progress and address any complications related to the unique presentation of WS alongside a history of CDH.

3. DISCUSSION

Wandering spleen is a rare condition that occurs in less than 0.25% of the general population. It can affect both young children and adults, with a higher incidence among females. This condition can arise due to congenital factors, such as the absence of typical splenic suspensory ligaments resulting from developmental issues in the dorsal mesogastrium, or due to abnormalities in the normal suspensory ligaments. Additionally, acquired anomalies can develop due to factors like a weakened abdominal wall, multiple pregnancies, hormonal fluctuations, or an enlarged spleen, all of which can contribute to the development of a wandering spleen [1,5].

In this case, the patient developed a wandering spleen secondary to a congenital diaphragmatic hernia. CDH is caused by the failure of the various embryologic components of the diaphragm to fuse during the 4th to 8th weeks of gestation. As a result, the abdominal viscera can herniate into the thoracic cavity. Although extremely unusual, a wandering spleen is an associated consequence of cdh, as observed in our patient. A wandering spleen can accompany CDH because the spleen loses its typical location of diaphragmatic and retroperitoneal fixation.

The majority of cases of cdh are typically identified in the pediatric population. Normally, diaphragmatic development is completed by the ninth week of fetal development. The closure of the left side of the diaphragm usually occurs about a week later than the right side, which is why left-sided cdh is more frequently observed. A significant part of diaphragmatic formation involves the fusion of the pleuroperitoneal membrane with the septum transversum, leading to the separation of the coelomic cavity into abdominal and thoracic cavities [6]. When a persistent pleuroperitoneal defect is present at around the tenth week of development, it can

result in sections of the intestines protruding into the thoracic cavity. In most cases, adults with CDH do not display symptoms when diagnosed [6]. For the diagnosis of CDH, ct scanning is considered the gold standard. A distinctive whorled appearance of the splenic vessels and the surrounding fat at the splenic hilum may be observed, Which is specific for torsion of the wandering spleen, as demonstrated in our patient's ct scan. Surgical repair is typically recommended irrespective of symptoms to prevent future complications, such as the risk of strangulation leading to gangrenous tissue within the hernia [7]. An asymptomatic wandering spleen has a complication rate of approximately 65%. Hence, operative interventions like splenopexy or splenectomy are considered the preferred treatment options. the repair of cdh can be carried out through different approaches, including laparotomy or laparoscopy, although a thoracic approach is less frequently used.

4. CONCLUSION

CDH cases should be considered for laparoscopic approaches to enhance abdominal cavity visualization, avoid potentially associated abnormalities, and reduce the risk of long-term complications associated with open surgeries, such as bowel adhesions and incisional hernias. When managing CDH, a comprehensive evaluation is essential, including assessing the diaphragmatic defect, intestinal herniation, pulmonary hypoplasia, the embryological orientation of intestinal structures, and the presence of any associated genetic syndromes.

CONSENT

As per international standards or university standards, the participant's written consent has been collected and preserved by the author(s).

ETHICAL APPROVAL

It is not applicable.

COMPETING INTERESTS

Authors have declared that no competing interests exist.

REFERENCES

1. Mehta a, vana pg, glynn I. splenic torsion after congenital diaphragmatic hernia repair: case report and review of the

- literature. journal of pediatric surgery. 2013;1;48(3):e29-31.
2. Niccolò petrucciani, sara claudia barone, leonida mucaj, francesco d'angelo, paolo aurello, gianfranco silecchia wandering spleen causing small bowel obstruction: laparoscopic surgical treatment (with video), international journal of surgery case reports. 2023;112.
Available:<https://doi.org/10.1016/j.ijscr.2023.108961>
 3. Alba ganarin, francesco fascetti leon, enrico la pergola, and piergiorgio gamba. surgical approach of wandering spleen in infants and children: a systematic review. Journal of laparoendoscopic & advanced surgical techniques.apr. 2021;468-477.
Available:<http://doi.org/10.1089/lap.2020.0759b>
 4. Dangen j, lau s, abbas s. treatment of a congenital diaphragmatic hernia with associated wandering spleen: a case report of a 17-year-old girl. international journal of surgery case reports. 2020;1;77:32-5.
 5. El bouhaddouti h, lamrani j, louchi a, el yousfi m, aqodad n, ibrahimi a, boubou m, kamaoui i, tizniti s. torsion of a wandering spleen. saudi journal of gastroenterology: official journal of the saudi gastroenterology association. 2010; 16(4):288.
 6. Weber tr, tracy jr t, bailey pv, lewis je, westfall s. congenital diaphragmatic hernia beyond infancy. the american journal of surgery. 1991;1;162(6):643-6.
 7. Swain jm, klaus a, achem sr, hinder ra. congenital diaphragmatic hernia in adults. inseminars in laparoscopic surgery. sage ca: thousand oaks, ca: sage publications. 2001;8(4): 246-255.

© 2024 Musande et al.; This is an Open Access article distributed under the terms of the Creative Commons Attribution License (<http://creativecommons.org/licenses/by/4.0>), which permits unrestricted use, distribution, and reproduction in any medium, provided the original work is properly cited.

Peer-review history:
The peer review history for this paper can be accessed here:
<https://www.sdiarticle5.com/review-history/110510>