

# Long-Term Fever and Cytomegalovirus Infection in the Field of HIV Immunosuppression in Two Cases and Review of the Literature

Angèle Azon-Kouanou, Kouessi Anthelme Agbodande, Marius Doukpo, Mahoutin Semassa Ghislain Missiho, Roberto Dossou Torès Kouassi Prudencio, Crescent Darius Cossou-Gbéto, Eugénie Dansou, Djimon Marcel Zannou, Fabien Hougbe

Internal Medicine and Medical Oncology Department, National Teaching Hospital (NTH), Hubert Koudougou Maga (HKM), Cotonou, Benin

Email: angele.azonkouanou@gmail.com, agbotem@yahoo.fr, doukpom@gmail.com, missiho.ghislain@yahoo.fr, prudenciotores@gmail.com, cossougbetocrescent@yahoo.fr, eugeniedansou1@gmail.com, djmzannou@yahoo.fr, fab2012jos@yahoo.com

**How to cite this paper:** Azon-Kouanou, A., Agbodande, K.A., Doukpo, M., Missiho, M.S.G., Prudencio, R.D.T.K., Cossou-Gbéto, C.D., Dansou, E., Zannou, D.M. and Hougbe, F. (2020) Long-Term Fever and Cytomegalovirus Infection in the Field of HIV Immunosuppression in Two Cases and Review of the Literature. *Open Journal of Internal Medicine*, 10, 151-159.  
<https://doi.org/10.4236/ojim.2020.102016>

**Received:** March 31, 2020

**Accepted:** May 8, 2020

**Published:** May 11, 2020

Copyright © 2020 by author(s) and Scientific Research Publishing Inc. This work is licensed under the Creative Commons Attribution International License (CC BY 4.0).  
<http://creativecommons.org/licenses/by/4.0/>



Open Access

## Abstract

Cytomegalovirus (CMV) infection is an infection that most often affects immunocompromised individuals with a seroprevalence of more than 80%. CMV co-infection is associated with increased mortality in HIV-infected individuals despite antiretroviral treatment. It has the potential for hematogenous dissemination to all the organs, but only becomes symptomatic when the viral load is high. This is especially possible when the human immune system is well controlled so that the individual infected with CMV generally remains asymptomatic, and possibly for a long period. Once the immune system fails, CMV infection becomes symptomatic. Diagnosis is not easy and is often done postmortem in developing countries with limited technical facilities. We report here two cases diagnosed at the Internal Medicine Service of the CNHU-HKM in Cotonou. The patients were infected with HIV and had a long term fever. The diagnoses were made on the basis of CMV serology. The first diagnosis was post-mortem, and the second patient died 48 hours after the start of the treatment.

## Keywords

CMV Infection, HIV, Deaths, Cotonou

## 1. Introduction

Cytomegalovirus (CMV) is generally accepted as a cause of disease in fetuses,

allograft recipients, and HIV-infected patients. Recently, it has been recognized as a pathogen for people admitted to intensive care units, the elderly and the general population. It is a ubiquitous beta herpes virus that causes latent infection with seroprevalence ranging from about 50% in the general adult population in high-income countries to over 80% in low-income countries [1].

CMV has the potential for hematogenous dissemination to all the organs, but only becomes symptomatic when the viral load is high. This is especially possible when the human immune system is well controlled so that the individual infected with CMV generally remains asymptomatic [1], and possibly for a long period. Once the immune system fails, CMV infection becomes symptomatic. Among high-risk groups, such as people infected with HIV, seroprevalence is over 80% [2] [3]. It has been hypothesized that CMV has an indirect effect on HIV by promoting HIV transmission and morbidity, and thus increasing mortality through undefined mechanisms [4] [5]. In high-income countries, co-infection with CMV in HIV-infected men who have sex with men has been associated with increased seminal shedding and HIV transmission [6]. In addition, CMV DNA in semen correlates with HIV seminal RNA levels [7] [8] indicating that CMV affects local HIV replication. Finally, it has become increasingly clear that CMV co-infection is associated with increased mortality in people infected with HIV despite antiretroviral (ARV) treatment [9] [10]. In the face of long-term fever in an HIV immunocompromised setting, CMV infection is not always mentioned as a first-line treatment. In some cases, it can be a source of diagnostic wandering in our context. This is the reason for this publication about two cases observed in the department and a review of the literature.

## 2. Clinical Case n°1

A 42-year-old diabetic male known to have been on metformin for 4 months is admitted to the department for investigation of a long term fever. The onset would go back to 2 months before admission with a fever of 40°C, evolving intermittently and treated as malaria without success. The onset three weeks later of a productive cough with whitish sputum motivated a first consultation in a health centre where the diagnosis of co-infection HIV/tuberculosis pulmonary has been made. He was initially put on the anti-tuberculosis treatment: Etambutol-Rifampicin-Isoniazid-Pyrazinamide (ERHZ), then supplemented by ARV treatment (Tenofovir-Lamivudine-Efavirenz). Faced with the persistence of the fever, he consulted the internal medicine department, which decided to hospitalize him for better care.

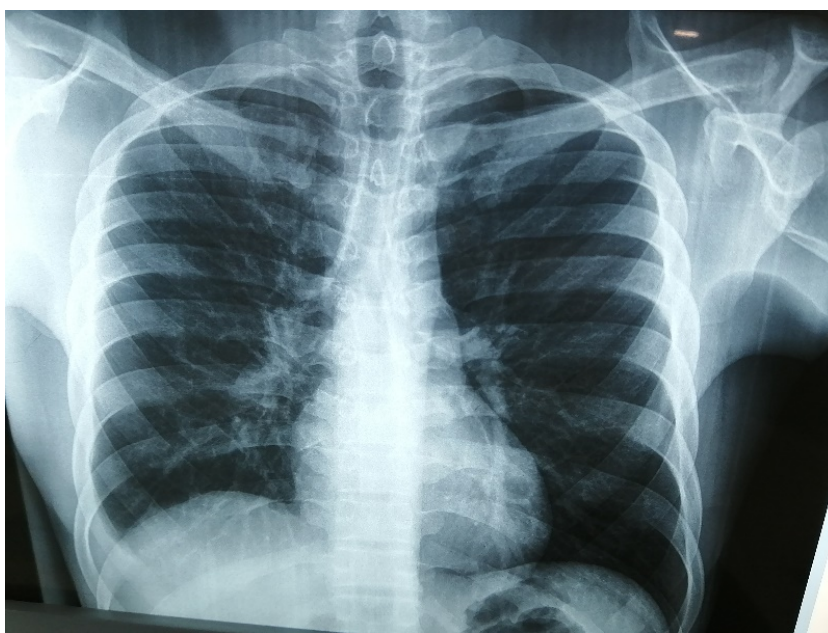
On entry, he had an altered general condition with a WHO performance index of 4 and a systemic inflammatory response syndrome (temperature at 40°C, pulse at 130 beats per minute, respiratory rate at 32 cycles per minute). Physical examination noted respiratory distress (polypnoea at 32 cycles per minute, hypoxemia at 87% in ambient air). On pulmonary auscultation, the lungs were clear. The lymph node areas were free of lymphadenopathy. The rest of the

physical examination was unremarkable. In front of this picture of long term fever with signs of pulmonary callus (a hypoxemic pneumopathy), we evoked in addition to tuberculosis, pneumocystis, pulmonary infection with pyogenic germs certainly badly or not treated. The chest X-ray (**Figure 1**) noted an absence of visible organized parenchymal focus, on the other hand, there is an enlargement of the cardiac silhouette with (TBI = 0.6).

DNA testing for *Mycobacterium tuberculosis* in sputum by GenXpert technique and TST was negative. Bronchial fibroscopy with bronchoalveolar lavage for pneumocystis jirovecii could not be performed depending on the clinical status of the patient.

Biological examinations noted a biological inflammatory syndrome with a C-Reactive Protein elevated to 96 mg/l and an increase in alpha 1 and beta 2 globulins associated with major polyclonal hypergammaglobulinemia on serum protein electrophoresis. The CBC showed pancytopenia with hypochromic adrenergic microcytic anemia (Hb = 6.0 g/dl; GMV = 75.5 fl; TCMH = 24.1 pg; Reticulocytes = 10.0 G/L), leukopenia at 2.1 G/L and thrombocytopenia at 62 g/L. The medullogram was normal. The CD4 count was 134 cells / $\mu$ L. A series of five blood cultures were negative. Hepatitis A, B, and C serologies for hepatitis were negative. Transthoracic echocardiography noted a pericardial effusion slide with no valvular involvement. There was no objectified deep adenopathy on abdominal ultrasound. Cerebro-thoraco-abdomino-pelvic scans for abnormalities (infectious or tumour) were normal. The fundus performed as part of the follow-up of his diabetes noted minimal non-proliferative diabetic retinopathy and Kirkendall's stage II hypertensive retinopathy.

In view of the high endemicity of tuberculosis in our country, the field of HIV immunosuppression, the diagnosis of multiple opportunistic diseases with



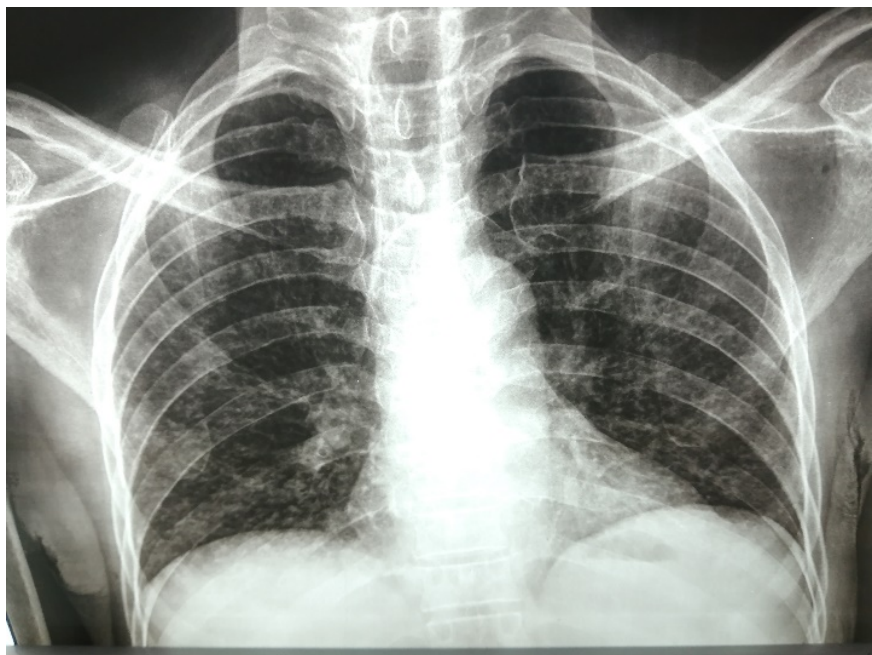
**Figure 1.** Chest X-ray: absence of visible organized parenchymal focus.

pulmonary localization (probably tuberculosis) complicated by severe anemia in a field of retrovirosis not yet initiated to ARV treatment was retained. We therefore continued the antituberculosis treatment (ERHZ 4 cp/d) and the patient was put on Cotrimoxazole 960 mg cp: 1 single tablet, oxygen therapy 4 l/min with a transfusion of red blood cells.

The evolution was stationary, with persistent fever and hepatic cholestasis (Gamma GT = 391 UI/L, PAL = 293 UI/L). This led to discontinuation of tuberculosis treatment at D11 of hospitalization and initiation of ARV treatment (Tenolam-E: 1 cp in the evening) at D15 of hospitalization. Despite this, the fever was persistent but controlled on antipyretic drugs. At D36 of hospitalization, in front of the persistence of the fever and the normalization of all the assessments carried out, we thought of a cytomegalovirus septicemia, which motivated the realization of the serology with CMV which returned positive. The result was received after the death of the patient. The diagnosis made was then a cytomegalovirus infection in a field immunocompromised by HIV.

### 3. Clinical Case n°2

Patient aged 53 years, unmarried, father of two children (the last one was 5 months old), presenting for about 10 months, before admission, a mostly bladder fever evolving intermittently associated with a weight loss of about 14 kg (20.28%) of body weight in 10 months, intense asthenia. The association with the picture of a greasy cough, stage IV dyspnea and hypoxia with ambient air saturation varying between 70% and 80% motivated a consultation in a peripheral health centre where treatment with Ceftriaxone and Azithromycin had been initiated. Emergency chest X-ray showed a diffuse miliary image, which is



**Figure 2.** Chest X-ray: diffuse miliary image.

reported in **Figure 2**. In view of the high endemicity of tuberculosis, the image of miliary, the terrain of HIV infection, and the frequent association of HIV and tuberculosis, the diagnosis of hypoxemic miliary tuberculosis was made and treated as such. Given the persistence of the clinical picture (fever, dyspnea, hypoxia) he was referred to the Internal Medicine Department of the CNHU-HKM of Cotonou for better care.

As a personal medical history, he has been infected with HIV for 10 months, initiated on ARVs (association: Tenofovir, Lamivudine, Efavirenz). The initial CD4 count was 46 cells/micromoles per litre).

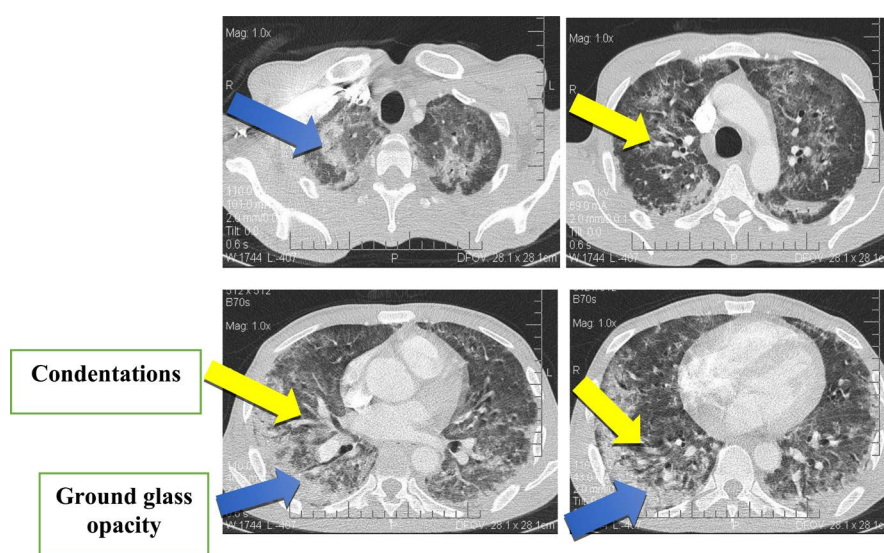
On entry, the general condition was altered with the WHO performance index at 4. The weight was 55 Kgs. The temperature was 38.6°C, blood pressure 110/60 mmHg, pulse rate was 120 beats per minute, pulse oxygen saturation (SpO<sub>2</sub>) 78% - 86% in ambient air. The palpebral mucosa was pale, and the bulbar mucosa was anicteric.

The pleuro-pulmonary level showed superficial polypnoea with respiratory rate at 48 cycles/minute, and bilateral pulmonary condensation syndrome. The heart was regular with no added noise, and tachycardia was noted. No edema of the lower extremities. The rest of the physical examination is unremarkable for the rest of the case.

On the paraclinical level, we noted the presence of images of bilateral diffuse miliary on the chest X-ray, confirmed by the chest CT scan which showed in **Figure 3**, bilateral ground glass opacity, and condensations.

Biologically the C Reactive Protein was 308 mg/L; the sedimentation rate was accelerated to 56 mm in the first hour. The blood count (CBC) showed anemia at 11.7 g/L, hematocrit at 43%. The tuberculin intradermal reaction was negative. The rest of the biological assessment, notably the renal and hepatic tests, the blood ionogram and the blood sugar level, was without particularity for the case.

In view of this clinical picture, the problem of hypoxemic diffuse infiltrative



**Figure 3.** Chest CT scan: condensations, and ground glass opacity.



pneumopathy was posed. The diagnostic hypotheses were: miliary tuberculosis, pneumocystis, immune restoration syndrome, pulmonary embolism, and cytomegalovirus pneumonia. The negativity of the other results (miliary tuberculosis, pneumocystis, immune restoration syndrome, pulmonary embolism) led us to the realization of the serology of Cytomegalovirus (CMV) which came back positive.

The diagnosis of cytomegalovirus pneumonia was made. Treatment with Valacyclovir 500 mg 4 tablets twice daily started in the absence of Gancyclovir, which is no longer indicated but not available in our local pharmacies.

The evolution was disappointingly marked by the death of the patient, 48 hours after the initiation of the anti-viral treatment (Valacyclovir).

#### 4. Discussion

CMV depresses the immune system, primarily T-cell function [1] [11] and immunocompromised patients are prone to manifestations of CMV infection. These can range from short disabling febrile periods to severe organ damage [2] [12]. This is the case of our two patients with long-term fever. In HIV-infected patients, the risk of symptomatic infection correlates with the degree of immunosuppression and is particularly high when the CD4 cell count falls below 100 cells/ $\mu$ L [13] [14]. However, cases of CMV infection with normal CD4 cell counts have been described. Indeed, in the first patient, the CD4 count was 134 cells/ $\mu$ L. This level is not normal, nor is it below 100 cells/ $\mu$ L.

And this is not the case in the second patient who is more immunocompromised than the first with a CD4 count of 46 cells/ $\mu$ L, which is also below 100 cells/. Cases have been reported in immunocompetent subjects [15]. As a result, our patient with a CD4 count of 143 cells/ $\mu$ L did not escape CMV infection. This implies that in order to prevent CMV infection, CD4 lymphocytes must be preserved both quantitatively and qualitatively. Retinitis is the most common manifestation of CMV worldwide [16]; it is usually bilateral and is thought to account for up to two thirds of the presentations in the Western literature [16], [17]. CMV is also a well-known cause of disease in the gastrointestinal tract [16] [18] and about 5% to 10% of CMV cases have manifestations in the colon [16]. In addition, cases of encephalitis, neuropathy, pneumonia, and hepatitis have been reported in the literature [13]. However, in our patient no visceral or ocular damage was found, as all investigations returned to normal.

Isolation of CMV for diagnosis often requires relatively advanced clinical procedures and laboratory equipment that may not be available in African countries. This is the case in our context where the technical facilities are not available and the specimen has been sent abroad. In addition, the interpretation of available laboratory results is complex [19] [20]. As a result, diagnosis is often made postmortem. The first patient died before the result was available. About the 2nd patient, the diagnosis was made when he was alive, with the possibility of starting a treatment. He died 48 hours after the start of the treatment. In both

cases, the evolution was unfavourable, followed by death. Martinson *et al.* [21] showed that 7 out of 7 cases of CMV pneumonia in HIV-infected adults from South Africa were undiagnosed before death. Similarly, Rennert *et al.* [22] found that 17 HIV-infected children treated for suspected tuberculosis were infected with other pathogens; 7 (41.2%) of these children had CMV infection diagnosed postmortem. This implies that treatment should be started as soon as possible after the CMV serology sample is taken without waiting for the result. In our context where the technical platform is not favourable for diagnosis and the treatment is not available in our pharmacies, management remains difficult. Perhaps we need to think about it early, so that the diagnosis can be made at an early stage, and to have the possibility of quickly resorting to treatment in order to improve the prognosis under our skies. Its clinical polymorphism can be a source of diagnostic wandering. In the first case, it was a context of long term fever, without point of call, while in the second case the diagnosis was made in the course of a long term fever, with pulmonary point of call (hypoxemic febrile pneumopathy).

## 5. Conclusion

CMV infection is a common opportunistic infection in immunocompromised individuals. It is not easy to diagnose and is often diagnosed postmortem in developing countries with limited technical facilities. Because of the increased mortality associated with this infection, it would be advisable to start presumptive treatment as soon as it is thought of, just after sampling. Its clinical polymorphism can lead to misdiagnosis. In some cases, the clinical status may be poor. Fever was present in all cases.

## Authors' Contributions

All authors contributed to the conduct of this work and to the writing of the manuscript.

## Conflicts of Interest

The authors declare no conflicts of interest regarding the publication of this paper.

## References

- [1] Griffiths, P., Baraniak, I. and Reeves, M. (2015) The Pathogenesis of Human Cytomegalovirus. *The Journal of Pathology*, **235**, 288-297. <https://doi.org/10.1002/path.4437>
- [2] Murray, P.R., Rosenthal, K.S. and Pfaller, M.A. (2009) Medical Microbiology. 6th Edition, Mosby/Elsevier, Philadelphia.
- [3] Andrew, D.Y. and William, E.M. (2014) Human Cytomegaloviruses, Methods and Protocols. Humana Press, New York.
- [4] Gianella, S., Strain, M.C., Rought, S.E., *et al.* (2012) Associations between Virologic

- and Immunologic Dynamics in Blood and in the Male Genital Tract. *Journal of Virology*, **86**, 1307-1315. <https://doi.org/10.1128/JVI.06077-11>
- [5] Brantsaeter, A.B., Johannessen, A., Holberg-Petersen, M., *et al.* (2012) Cytomegalovirus Viremia in Dried Blood Spots Is Associated with an Increased Risk of Death in HIV-Infected Patients: A Cohort Study from Rural Tanzania. *International Journal of Infectious Diseases*, **16**, e879-e885. <https://doi.org/10.1016/j.ijid.2012.08.003>
- [6] Gianella, S., Morris, S.R., Vargas, M.V., *et al.* (2013) Role of Seminal Shedding of Herpesviruses in HIV Type 1 Transmission. *The Journal of Infectious Diseases*, **207**, 257-261. <https://doi.org/10.1093/infdis/jis683>
- [7] Gianella, S., Morris, S.R., Anderson, C., *et al.* (2013) Herpes Viruses and HIV-1 Drug Resistance Mutations Influence the Virologic and Immunologic Milieu of the Male Genital Tract. *AIDS*, **27**, 39-47. <https://doi.org/10.1097/QAD.0b013e3283573305>
- [8] Gianella, S., Mehta, S.R., Strain, M.C., *et al.* (2012) Impact of Seminal Cytomegalovirus Replication on HIV-1 Dynamics between Blood and Semen. *Journal of Medical Virology*, **84**, 1703-1709. <https://doi.org/10.1002/jmv.23398>
- [9] Deayton, J.R., Sabin, C.A., Johnson, M.A., Emery, V.C., Wilson, P. and Griffiths, P.D. (2004) Importance of Cytomegalovirus Viraemia in Risk of Disease Progression and Death in HIV-Infected Patients Receiving Highly Active Antiretroviral Therapy. *The Lancet*, **363**, 2116-2121. [https://doi.org/10.1016/S0140-6736\(04\)16500-8](https://doi.org/10.1016/S0140-6736(04)16500-8)
- [10] Spector, S.A., Hsia, K., Crager, M., Pilcher, M., Cabral, S. and Stempien, M.J. (1999) Cytomegalovirus (CMV) DNA Load Is an Independent Predictor of CMV Disease and Survival in Advanced AIDS. *Journal of Virology*, **73**, 7027-7030. <https://doi.org/10.1128/JVI.73.8.7027-7030.1999>
- [11] Rouse, B.T. and Horohov, D.W. (1986) Immunosuppression in Viral Infections. *Reviews of Infectious Diseases*, **8**, 850-873. <https://doi.org/10.1093/clinids/8.6.850>
- [12] Griffiths, P.D. (2006) CMV as a Cofactor Enhancing Progression of AIDS. *Journal of Clinical Virology*, **35**, 489-492. <https://doi.org/10.1016/j.jcv.2005.10.016>
- [13] Steininger, C., Puchhammer-Stockl, E. and Popow-Kraupp, T. (2006) Cytomegalovirus Disease in the Era of Highly Active Antiretroviral Therapy (HAART). *Journal of Clinical Virology*, **37**, 1-9. <https://doi.org/10.1016/j.jcv.2006.03.005>
- [14] Slyker, J.A., Lohman-Payne, B.L., John-Stewart, G.C., *et al.* (2009) Acute Cytomegalovirus Infection in Kenyan HIV-Infected Infants. *AIDS*, **23**, 2173-2181. <https://doi.org/10.1097/QAD.0b013e32833016e8>
- [15] Giroud, O., Meier, P., San Millán, D. and Praz, G. (2010) Severe Cytomegalovirus (CMV) Infection: Not Only in Immunosuppressed Patients. *Revue Médicale Suisse*, **6**, 1918-1921.
- [16] Kaplan, J.E., Benson, C., Holmes, K.K., Brooks, J.T., Pau, A. and Masur, H. (2009) Guidelines for Prevention and Treatment of Opportunistic Infections in HIV-Infected Adults and Adolescents: Recommendations from CDC, the National Institutes of Health, and the HIV Medicine Association of the Infectious Diseases Society of America. *MMWR Recommendations and Reports*, **58**, 1-207. <https://doi.org/10.1037/e537722009-001>
- [17] Masur, H., Brooks, J.T., Benson, C.A., Holmes, K.K., Pau, A.K. and Kaplan, J.E. (2014) Prevention and Treatment of Opportunistic Infections in HIV-Infected Adults and Adolescents: Updated Guidelines from the Centers for Disease Control and Prevention, National Institutes of Health, and HIV Medicine Association of the



Infectious Diseases Society of America. *Clinical Infectious Diseases*, **58**, 1308-1311. <https://doi.org/10.1093/cid/ciu094>

- [18] Paparone, P.P. and Paparone, P.A. (2012) Cytomegalovirus Colitis in a Human Immunodeficiency Virus-Positive Patient with a Normal CD4 Count. *The American Journal of the Medical Sciences*, **344**, 508-510. <https://doi.org/10.1097/MAJ.0b013e31825d4d1d>
- [19] Kraft, C.S., Armstrong, W.S. and Caliendo, A.M. (2012) Interpreting Quantitative Cytomegalovirus DNA Testing: Understanding the Laboratory Perspective. *Clinical Infectious Diseases*, **54**, 1793-1797. <https://doi.org/10.1093/cid/cis212>
- [20] Hardie, D.R., Korsman, S.N. and Hsiao, N.Y. (2013) Cytomegalovirus Load in Whole Blood Is More Reliable for Predicting and Assessing CMV Disease than pp65 Antigenaemia. *Journal of Virology Methods*, **193**, 166-168. <https://doi.org/10.1016/j.jviromet.2013.06.019>
- [21] Martinson, N.A., Karstaedt, A., Venter, W.D., *et al.* (2007) Causes of Death in Hospitalized Adults with a Premortem Diagnosis of Tuberculosis: An Autopsy Study. *AIDS*, **21**, 2043-2050. <https://doi.org/10.1097/QAD.0b013e3282eea47f>
- [22] Rennert, W.P., Kilner, D., Hale, M., Stevens, G., Stevens, W. and Crewe-Brown, H. (2002) Tuberculosis in Children Dying with HIV-Related Lung Disease: Clinical Pathological Correlations. *The International Journal of Tuberculosis and Lung Disease*, **6**, 806-813.