



## Acute de Garengeot Hernia Masquerading as a Recurrent Inguinal Hernia – A Diagnostic Dilemma

K. Shah<sup>1\*</sup>, K. Planche<sup>2</sup>, R. D'Souza<sup>1</sup> and A. Khan<sup>1,3</sup>

<sup>1</sup>Department of Academic and Colorectal Surgery, Royal Free Hospital, Pond Street, London NW3 2QG, United Kingdom.

<sup>2</sup>Department of Radiology, Royal Free Hospital, Pond Street, London NW3 2QG, United Kingdom.

<sup>3</sup>The Cancer Institute, University College London, 72 Huntley Street, Camden Town, London WC1E 6DD, United Kingdom.

### Authors' contributions

This work was carried out in collaboration between all authors. All authors read and approved the final manuscript.

### Article Information

DOI: 10.9734/BJMRR/2016/19167

#### Editor(s):

(1) Ashish Anand, Department of Orthopaedic Surgery, GV Montgomery Veteran Affairs Medical Center, Jackson, MS, USA.

#### Reviewers:

(1) Jerraya Hichem, Charles Nicolle Hospital, Tunisia.

(2) Mohamed Salah, Beni-Suef University, Egypt.

Complete Peer review History: <http://sciencedomain.org/review-history/13447>

Case Study

Received 28<sup>th</sup> May 2015  
Accepted 28<sup>th</sup> August 2015  
Published 26<sup>th</sup> February 2016

### ABSTRACT

A de Garengeot hernia is a femoral hernia in which the sac contains the vermiform appendix. herein, we report an interesting case of a de Garengeot hernia with secondary appendicitis presenting acutely in a male patient with previous history of inguinal hernia repair. We discuss the diagnostic dilemmas involved and present a review of current literature.

*Keywords:* De Garangeot hernia; recurrent hernia; appendicitis.

### 1. INTRODUCTION

A recurrence rate of less than 1% has been reported after indirect inguinal hernia repair, with 80% of recurrences noted within the first

post-operative year [1]. Recurrence in the form of a direct hernia may result from injury to the floor of inguinal canal. Although rare, the evolution of a 'recurrent' femoral hernia after inguinal hernia repair has also been reported in a retrospective

\*Corresponding author: Email: [kanishk.shah@nhs.net](mailto:kanishk.shah@nhs.net);

series [2]. A rare form of femoral hernia involves the presence of the vermiform appendix within the hernial sac, initially described by Rene Jacques Croissant de Garengot [3]. To our knowledge, the presence of congestion induced secondary appendicitis within an incarcerated 'recurrent' femoral hernia after inguinal hernia repair, has not been reported in literature. Hence, herein we present an unusual case of a man who presented to hospital with a long-term of history of a recurrent lump at the site of a previous inguinal hernia repair, with acute transformation into a painful lump.

## 2. PRESENTATION OF CASE

A 78 year old gentleman presented to hospital with a 48 hour history of a tender lump in the right groin with associated nausea. The previous medical history included atrial fibrillation, a metallic heart valve and open right inguinal herniorrhaphy with mesh repair 15 years earlier. In the year preceding his presentation to hospital, the patient felt a recurrent lump at the hernia repair site. Clinical observations and examination showed presence of rate controlled atrial fibrillation, expected heart murmur and a transverse scar in the right inguinal region from previous surgery. There was a tender and irreducible swelling on the medial aspect of the scar without any extension into the scrotum. The groin examination was limited due to pain. Routine blood tests showed an elevated C – reactive protein at 49 g/L and an International Normalised Ratio (INR) of 2.9 as a result of his warfarin therapy. A plain abdominal radiograph was performed and was normal. The patient was clinically diagnosed as having a recurrent incarcerated inguinal hernia. He was investigated by means of a groin ultrasound which revealed the baffling possibility of a femoral hernia containing mainly fatty tissue with oedema of sac contents. Therefore a computed tomography (CT) scan was performed which initially reported a direct recurrent inguinal hernia containing the appendix (see Fig. 1). The patient was scheduled for groin exploration and examination of the right groin under general anaesthetic. This allowed the lump to be felt below the pubic tubercle; therefore an infra-inguinal incision was made below and medial to the previous scar. Careful dissection revealed a congested hernial sac arising from the femoral ring. Hernial sac dissection revealed a congested distal vermiform appendix as the main content. Only the distal portion of the appendix lying within the hernial sac was congested; the body of the appendix

and base were both normal. A retrograde appendicectomy and suture repair of the femoral hernia was performed. The patient made an uneventful recovery and was discharged home two days later.

## 3. DISCUSSION

The incidence of femoral hernias in males is around 5% initially presenting with strangulation in 40% of cases [1]. In a review of the Danish Hernia Database, Mikkelsen et al. reported an increased risk of developing a femoral hernia after previous inguinal herniorrhaphy [2]. The occurrence of de Garengot hernia is much rarer; approximately 1% of all femoral hernia that are repaired may contain the vermiform appendix [4]. It is rarer still for the appendix to be inflamed with rates quoted between 0.08 - 0.013% [5].

Typically, acute appendicitis occurs due to intraluminal obstruction from any cause [3] however, in the case of a de Garengot hernia, it is unclear whether external compression due to herniation or typical inflammation of the appendix is the primary event [6]. Given that obstruction can precipitate an inflammatory response, it is entirely possible that extra-luminal compression of the appendix in the femoral canal i.e. strangulation, may also lead to 'secondary' inflammation of the appendix [7]. Particularly, in our case, the latter would appear a more plausible explanation, since the peritoneal portion of the appendix was normal (see Fig. 2).

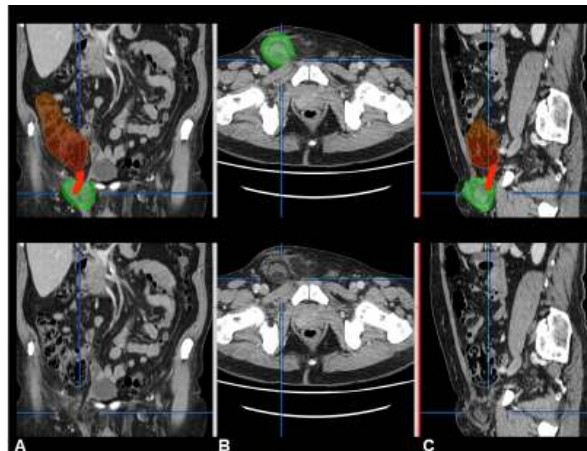
In addition, the secondary appendicular inflammation could have caused further congestion within the hernial sac, accounting for acute incarceration and emergency presentation. At present, it is not clear what causes a de Garengot hernia to develop, but it has been suggested that abnormal intestinal rotation during embryological development resulting in atypical appendicular attachment could result in a caecal appendix, with a higher probability of herniating through the femoral canal [8]. The presence of a large caecum may also increase the risk of the appendix herniating into the femoral canal [9]. In the case of our patient both of these factors may have had a role to play. In addition, the previous inguinal hernia repair significantly increased the likelihood of the patient developing a femoral hernia, since previous inguinal hernia repair is associated with a 15 fold increase in developing a femoral hernia, particularly in men above the age of 60 years. Inadvertent increase in the diameter of the

femoral canal as a direct result of the inguinal hernia repair is the most likely explanation for this observation [2].

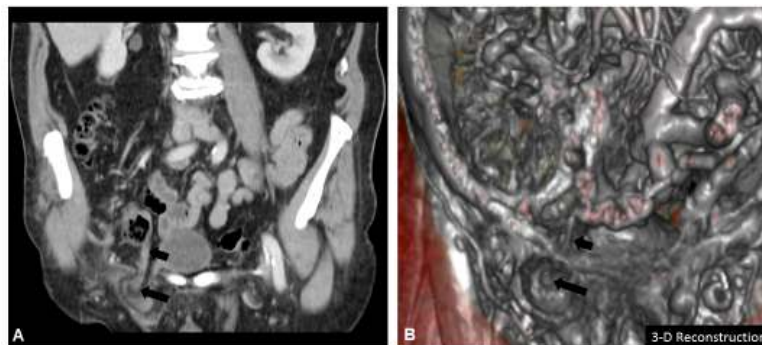
Most of the cases of a de Garengeot hernia present with symptoms of an incarcerated hernia and diagnosis tends to be at the time of the operation. However CT and MRI have been shown to be able to accurately identify the appendix within the femoral canal, allowing for earlier diagnosis [10,11]. In the current case report, operative exploration and meticulous layer-by-layer dissection confirmed the diagnosis of a de Garengeot hernia; ultrasound showed a femoral hernia without bowel contents, whilst, CT reported a direct inguinal hernia containing appendix. The distorted anatomy after previous inguinal surgery may have contributed to deceptive imaging findings, nevertheless, the imaging helped exclude other intra-abdominal pathologies (see Fig. 1).

This is of particular relevance when considering hernias in men; bowel contents within the sac is an obvious cause for concern, however on occasion the sac has been reported to contain a cryptorchid testicle which already has implications for fertility even before consideration is given to incarceration or strangulation within the hernia [12]. Prompt imaging therefore allows for earlier diagnosis and intervention.

In general, surgical repair is usually indicated for any femoral hernia due to the high rate of bowel strangulation with which it is associated. For de Garengeot hernias, suture methods and mesh repairs have both been used for fixation, and open and laparoscopic methods have been used for the appendicectomy in this setting [7]. Although there is no clear consensus regarding the optimal method of repair, most would agree that in the setting of infection the use of a mesh would be contraindicated.



**Fig. 1. Standard CT images in (a) Sagittal, (b) Axial (c) Coronal planes: The top sections are highlighted to show the caecum in brown, the appendix in red and the hernia in green**



**Fig. 2. Standard CT image in (a) Coronal plane with (b) 3-D image reconstruction: The short arrow shows the normal proximal appendix within peritoneal cavity; the long arrow shows secondary appendicitis of distal appendix within incarcerated hernia sac**

#### 4. CONCLUSION

In conclusion, to our knowledge, this is the only reported case of a de Garengeot hernia, in the context of a previous inguinal hernia repair. When this patient presented our most likely differential diagnosis was recurrence of the hernia with possible incarceration of bowel. Further investigation with trans-abdominal imaging only revealed the presence of the appendix within a groin-hernia and operative exploration led to definitive diagnosis. Hence, we would recommend that clinicians consider a femoral hernia as part of the differential diagnosis in all men above 60 years of age presenting with a tender lump after previous inguinal hernia repair, and emphasise early CT imaging and operative intervention.

##### 4.1 Learning Points

- Early Surgical intervention is indicated in any patients presenting with a recurrent painful hernia.
- Consider the possibility of a femoral hernia in any man with a previous inguinal hernia repair.
- To investigate these patients routinely with a CT scan to exclude the possibility of the hernial sac containing the appendix.

#### CONSENT

Consent was sought from the patient for the purposes of publication.

#### ETHICAL APPROVAL

It is not applicable.

#### COMPETING INTERESTS

Authors have declared that no competing interests exist.

#### REFERENCES

1. Paterson-Brown S. Core topics in general and emergency surgery. 4<sup>th</sup> ed. Edinburgh: Saunders Elsevier; 2009.
2. Mikkelsen T, Bay-Nielsen M, Kehlet H. Risk of femoral hernia after inguinal herniorrhaphy. British Journal of Surgery. 2002;89(4):486-8.
3. Akbulut S, Tas M, Sogutcu N, Arikanoglu Z, Basbug M, Ulku A, et al. Unusual histopathological findings in appendectomy specimens: A retrospective analysis and literature review. World Journal of Gastroenterology: WJG. 2011;17(15):1961-70.
4. Voitek AJ, MacFarlane JK, Estrada RL. Ruptured appendicitis in femoral hernias: Report of two cases and review of the literature. Annals of Surgery. 1974;179(1):24.
5. Rajan SS, Girn HR, Ainslie WG. Inflamed appendix in a femoral hernial sac: de Garengeot's hernia. Hernia. 2009;13(5):551-3.
6. Barbaros U, Asoglu O, Seven R, Kalayci M. Appendicitis in incarcerated femoral hernia. Hernia. 2004;8(3):281-2.
7. Ramsingh J, Ali A, Cameron C, Al-Ani A, Hodnett R, Chorushy C. De Garengeot's hernia: Diagnosis and surgical management of a rare type of femoral hernia. Journal of Surgical Case Reports. 2014;2:rju008.
8. Nguyen ET, Komenaka IK. Strangulated femoral hernia containing a perforated appendix. Can J Surg. 2004;47(1):68-9.
9. Zissin R, Brautbar O, Shapiro-Feinberg M. CT diagnosis of acute appendicitis in a femoral hernia. The British Journal of Radiology. 2000;73(873):1013-4.
10. Halpenny D, Barrett R, O'Callaghan K, Eltayeb O, Torreggiani WC. The MRI findings of a de Garengeot hernia; 2012.
11. Ebisawa K, Yamazaki S, Kimura Y, Kashio M, Kurito K, Yasumuro S, et al. Acute appendicitis in an incarcerated femoral hernia: A case of De Garengeot hernia. Case Reports in Gastroenterology. 2009;3(3):313-7.
12. Kassir R, Dubois J, Berremila SA, Baccot S, Boueil-Bourlier A, Tiffet O. A rare variant of inguinal hernia: Cryptorchid testis at the age of 50 years. Etiopathogenecity, prognosis and management. International Journal of Surgical Case Reports. 2014;5(7):416-8.

© 2016 Shah et al.; This is an Open Access article distributed under the terms of the Creative Commons Attribution License (<http://creativecommons.org/licenses/by/4.0>), which permits unrestricted use, distribution, and reproduction in any medium, provided the original work is properly cited.

Peer-review history:

The peer review history for this paper can be accessed here:  
<http://sciedomain.org/review-history/13447>