

Primary Angle Closure as a Presenting Feature of Retinitis Pigmentosa: A Rare Case Report

Lily Devi¹, Jyotiranjana Mallick^{2*}, Pradeep Malik³ and Sucheta Parija²

¹Department of General Medicine, MKCG Medical College, Odisha, India.

²Department of Ophthalmology, AIIMS, Bhubaneswar, India.

³Department of Pediatrics, MKCG Medical College, Odisha, India.

Authors' contributions

This work was carried out in collaboration between all authors. Author LD designed the study. Author JM (corresponding author) performed the statistical analysis, wrote the protocol and wrote the first draft of the manuscript. Author PM managed the analyses of the study. Author SP managed the literature searches. All authors read and approved the final manuscript.

Article Information

DOI: 10.9734/OR/2017/37497

Editor(s):

(1) Ahmad M Mansour, Professor, Department of Ophthalmology, American University of Beirut, Lebanon.

Reviewers:

(1) Gabor Nemeth, Borsod-Abaúj-Zemplén County Hospital and University Teaching Hospital, Hungary.

(2) Engy M. Mostafa, Sohag University, Egypt.

(3) Dominika Wróbel-Dudzińska, Medical University, Poland.

Complete Peer review History: <http://www.sciedomain.org/review-history/21872>

Case Report

Received 19th October 2017
Accepted 9th November 2017
Published 13th November 2017

ABSTRACT

Primary angle closure is an acute medical emergency. There are various predisposing factors in primary angle closure glaucoma such as age > 60 years, female gender, Eastern and Indian Asian race, positive family history, hypermetropia, eyes with short axial length and thicker lens. We report a case of 50 year old female presenting with sudden painful loss of vision in right eye. After control of increased intraocular pressure slit lamp examination was done which showed bilateral phacodonesis. Indirect gonioscopy revealed grade 1 narrow angle in all quadrants in right eye and open angle in left eye. Features suggestive of retinitis pigmentosa in both eyes were found on dilated fundus examination. Laser peripheral iridotomy and cataract extraction was performed in right eye and laser peripheral iridotomy alone was done in left eye. Zonular instability with thick anteriorly displaced lens due to retinitis pigmentosa has been found as the main causative factor resulting in angle closure in this case.

*Corresponding author: E-mail: jyotiran8519@gmail.com;

Keywords: Bony spicule; primary angle closure glaucoma; retinitis pigmentosa; zonular instability.

1. INTRODUCTION

Retinitis pigmentosa (RP) is a diffuse retinal degenerative disease affecting initially rod photoreceptors and subsequently cones [1]. It may be sporadic or XLR (most severe, least common), AD (best prognosis) or AR (most common). The classical triad of retinitis pigmentosa is bony spicule like retinal pigmentations, waxy disc pallor and arteriolar attenuation. The presenting symptoms are nyctalopia and dark adaptation difficulty. There is frequent association of RP and zonular instability, subluxation of lens, ectopia lentis. The zonular instability results in anterior shifting of iris lens diaphragm which may cause narrowing of angle and resultant decreased aqueous outflow. In our case the patient has RP with associated bilateral zonular instability as evident by presence of phacodonesis in both eyes. This may have contributed to anterior shifting of iris lens diaphragm with resultant precipitation of angle closure attack in right eye and also a high likelihood of similar attack in the left eye in the future.

2. CASE PRESENTATION

A 50 year old female presented with complains of pain, blurring of vision and redness in right eye for two days. It was associated with headache, vomiting, coloured halos and watery discharge. A meticulous history taking suggested she had decreased vision in both eyes during night since childhood. There was no history of trauma to any eye. On systemic evaluation no other associated diseases were found. None of the family members were affected by similar condition of decreased vision at night.

On examination the distant visual acuity was found to be 5/60 OD and 3/60 OS. The visual acuity did not improve with pinhole. No associated refractive error was found. The intraocular pressure (IOP) was recorded to be 36 mm Hg OD and 18 mm Hg OS by Goldmann applanation tonometry method with correction done for central corneal thickness. On slit lamp examination ciliary congestion with mild corneal edema was found in right eye. Shallow anterior chamber with Van Herick grade 1 was found in right eye (Primary anterior chamber depth <1/4 Corneal thickness) and grade 3 in the left eye (Primary anterior chamber depth = 1/4-1/2 corneal thickness). Detail evaluation of anterior chamber was not possible due to corneal edema in the affected eye. The pupillary diameter was 5mm OD which was fixed and middilated while a diameter of 2 mm with sluggish reaction to light was found in OS (Fig. 1).

Intravenous mannitol 20% (1 gm/kg) was given over 30 minutes to decrease the intraocular pressure. Topical IOP lowering agents like combination of timolol 0.5% and brimonidine 0.2% (Combigan, Allergan Inc, Irvine, CA, USA) was given in right eye. To control the associated inflammation and corneal edema topical steroid prednisolone 1% (Predfort, Allergan, New York) was given. After the control of IOP and resolution of corneal edema indirect gonioscopy was performed with help of Goldmann two mirror gonioscopes. Gonioscopy revealed very narrow angle of grade 1 in right eye (only Schwalbe line visible 360 degree in all the quadrants) and grade 3 in the left eye. Laser peripheral iridotomy was performed in both eyes.

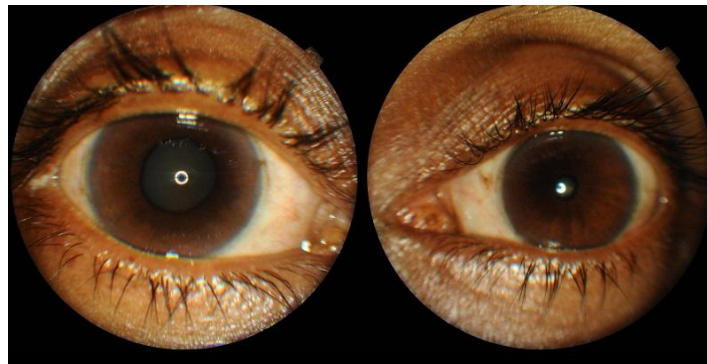


Fig. 1. Showing mid dilated pupil in OD with mild corneal edema

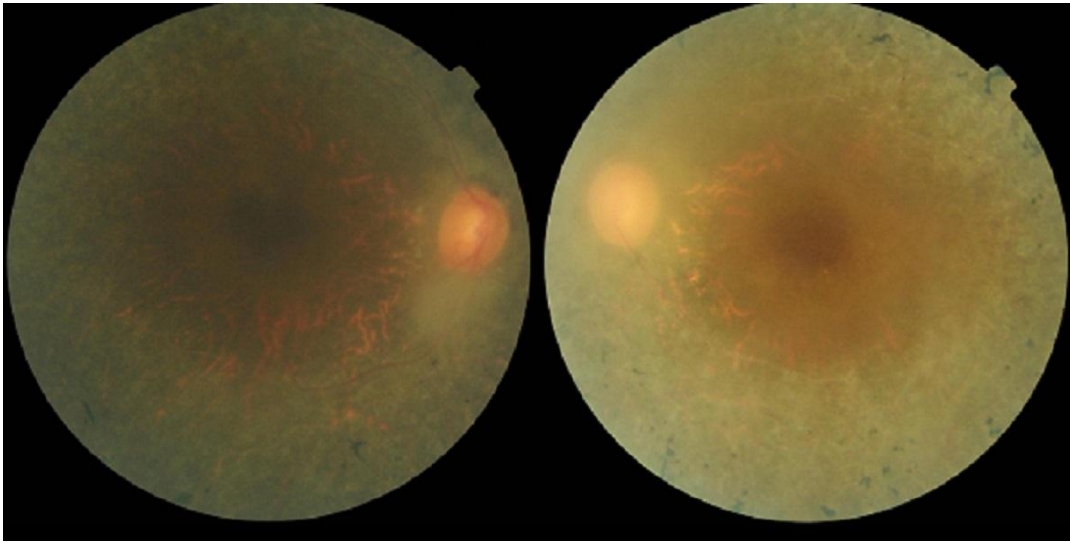


Fig. 2. Fundus showing bony spicule like retinal pigmentations and attenuated vessels OU

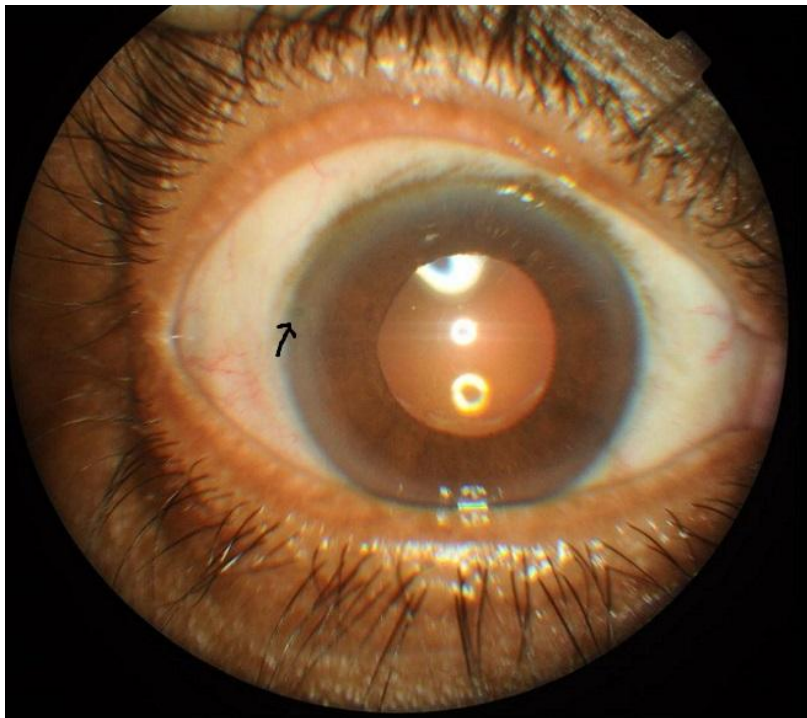


Fig. 3. Showing pseudophakia OD with laser Peripheral iridotomy OD (arrow mark)

On slit lamp examination phacodonesis was observed in both eyes with grade 2 nuclear cataract OD and no cataract OS. Dilated fundus examination revealed cup disc ratio of 0.5:1 OD and waxy optic disc pallor with cup to disc ratio 0.4:1 OS. This was associated with attenuated vessels and bony spicules like retinal pigmentations in the mid periphery in both eyes

(Fig. 2). A provisional diagnosis of primary angle closure with retinitis pigmentosa (RP) was made. Humphrey visual field testing could not be done due to gross diminution of vision. Topical cycloplegic eye drop (homatropine 2%) was prescribed to relieve the angle closure attack by pulling the lens posteriorly.

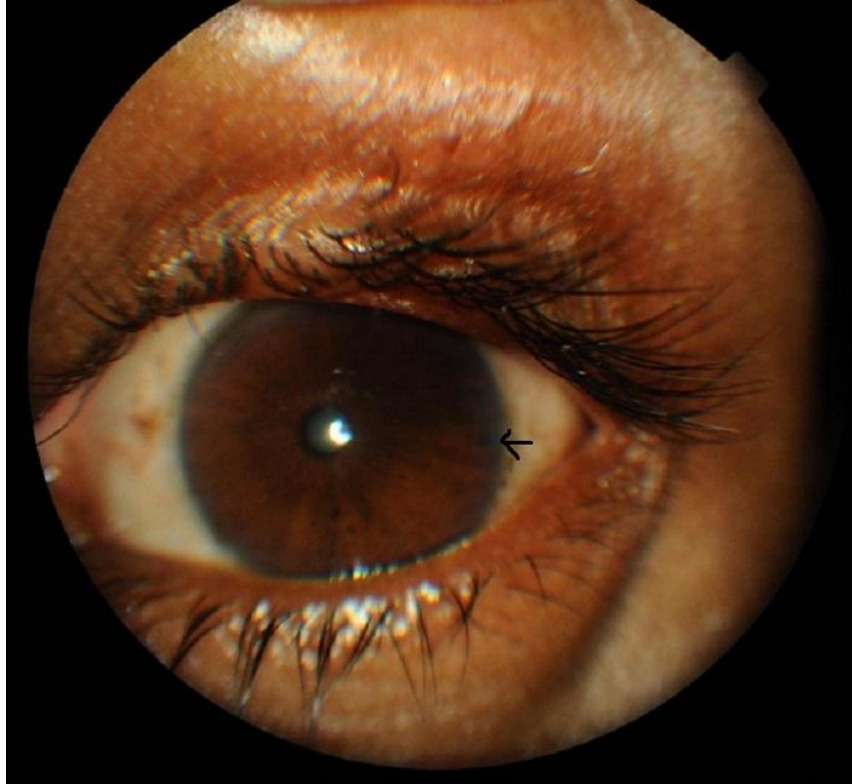


Fig. 4. Showing laser Peripheral iridotomy (arrow mark) OS

Electroretinogram (ERG) demonstrated decreased scotopic rod functions. Cataract extraction with intraocular lens implantation was done in right eye as the definitive treatment (Fig. 3, Fig. 4). During cataract extraction by phacoemulsification capsular tension ring was used and the surgery was without any complications. At one month follow up intraocular pressure was found to be 14 mm Hg in right eye and 18 mm Hg in the left eye. The patient was kept under regular follow up for any similar attack in the left eye.

3. DISCUSSION

The term angle closure refers to iridotrabecular contact and resultant obstruction of aqueous outflow [2]. Association of international glaucoma societies has classified this as primary angle closure suspect, primary angle closure and primary angle closure glaucoma (PACG).

A study showed that prevalence of glaucoma was found to be 2.3% among the retinitis pigmentosa patients. Out of which 93.75% had angle closure glaucoma and 6.25% had open angle glaucoma [1]. According to the study by

Badeeb et al. the prevalence of PACG among RP patients over 40 years of age was found to be 1.03%. But the prevalence of PACG in general population is 0.07%. This indicates a higher prevalence of PACG in RP patients than in general population [3]. This has been confirmed by another study which showed that 1.3% people were having acute angle closure episodes in retinitis pigmentosa patients in a 15 year period but in normal population its percentage is 0.4% [4].

Various studies have come forward with many theories explaining the mechanism of primary angle closure in retinitis pigmentosa. There is frequent association of RP and zonular instability, subluxation of lens, ectopia lentis [5]. Anterior displacement of lens and resultant angle narrowing due to zonular instability is prevalent in RP patients. Zonular insufficiency contributing to angle closure glaucoma in RP patients occurs in 18.8% of RP patients. So timely lens extraction may prevent the acute attack [5-7]. Badeeb et al. explained that RP patients suffering from angle closure glaucoma have thicker and more anteriorly placed lens but with normal axial length [3].

The present case was associated with phacodonesis in both eyes due to zonular instability as evident on slit lamp examination. The cause of primary angle closure in right eye was attributed to forward shifting of iris lens diaphragm because of zonular instability. Laser iridotomy along with cataract extraction was performed in the right eye and prophylactic laser iridotomy was done in the left eye as there was high likelihood of occurrence of similar attack in the left eye due to zonular instability. As there was absence of cataract in the left eye the patient was kept under regular observation and the plan of lens extraction surgery was reserved till the development of cataract in absence of any angle closure attack. There was no association of any other causes of lens instability like pseudoexfoliation syndrome, marfan's syndrome or prior trauma. The decreased vision is due to corneal edema and changes due to RP.

Carbonic anhydrase inhibitors, hyperosmotic agents, topical beta blockers, prostaglandins and alpha agonists are used to lower the intraocular pressure. Laser iridotomy followed by cataract extraction is the definitive treatment. However miotics should be avoided in such cases as they cause further relaxation of zonular support resulting in worsening of symptoms. Cycloplegics help in relieving the block by pulling the lens posteriorly [8].

Acute angle closure glaucoma in RP patients has a male preponderance with a tendency to occur in younger age where as PACG in normal population commonly occurs in elderly females due to biometric characteristics and age related changes [9,10]. In contrast our case is a middle aged female person.

4. CONCLUSION

In conclusion, PAC can be a presenting feature of RP. Zonular insufficiency and consequent anterior displacement of lens has been proposed to be the main factor for angle closure. We believe gonioscopy should be done routinely in every case of retinitis pigmentosa to rule out possible angle closure.

CONSENT

As per international standard or university standard, patient's written consent has been collected and preserved by the authors.

ETHICAL APPROVAL

All authors hereby declare that all experiments have been examined and approved by the appropriate ethics committee and have therefore been performed in accordance with the ethical standards laid down in the 1964 Declaration of Helsinki.

COMPETING INTERESTS

Authors have declared that no competing interests exist.

REFERENCES

1. Ferrari S, Di Iorio E, Barbaro V, Ponzin D, Sorrentino FS, Parmeggiani F. Retinitis pigmentosa: Genes and disease mechanisms. *Current Genomics*. 2011; 12(4):238-249.
2. Peng T, Wu I, Zhou W. Retinitis pigmentosa associated with glaucoma - clinical analysis. *Yan Ke Xu Bao*. 1990;6: 17-9
3. Badeeb O, Trope G, Musarella M. Primary angle closure glaucoma and retinitis pigmentosa. 1993;71(6):727-32.
4. Ko YC, Liu CJ, Hwang DK, Chen TJ, Liu CJ. Increased risk of acute angle closure glaucoma in retinitis pigmentosa: A population based case-control study. *PLoS One*. 2014;9(9):e107660.
5. Sato H, Wada Y, Abe T, Kawamura M, Wakasuka R, et al. Retinitis pigmentosa associated with ectopia lentis. *Arch Ophthalmol*. 2002;120:852-4.
6. Dikopf MS, Chow CC, Mieler WF, Tu EY. Cataract extraction outcomes and prevalence of zonular insufficiency in retinitis pigmentosa. *Am J Ophthalmol*. 2013;156:82-8.
7. Sira M, Ho T. Acute angle closure glaucoma secondary to a luxated lens associated with retinitis pigmentosa. *Eye*. 2005;19:472-3.
8. Madiill SA, Bain KE, Patton K, Bennett H, Singh J. Emergency use of pilocarpine and pupil block glaucoma in ectopia lentis. *Eye (Lond)*. 2005;19(1):105-7.
9. Cheng JW, Cheng SW, Ma XY, Cai JP, LiY, et al. The prevalence of primary glaucoma in Mainland China: A systematic review and meta analysis. *J Glaucoma*. 2013;22:301-6

10. Wang D, Huang G, He M, Wu L, Lin S. Comparison of anterior ocular segment biometry features and related factors among American caucasians, American Chinese and mainland Chinese. *Clin Experiment Ophthalmol.* 2013;40: 542-9.

© 2017 *Devi et al.*; This is an Open Access article distributed under the terms of the Creative Commons Attribution License (<http://creativecommons.org/licenses/by/4.0>), which permits unrestricted use, distribution, and reproduction in any medium, provided the original work is properly cited.

Peer-review history:
The peer review history for this paper can be accessed here:
<http://sciencedomain.org/review-history/21872>