

Role of High Resolution Ultrasound in Assessment of Abnormalities of Median Nerve in Carpal Tunnel Syndrome

Mohamed Farouk Agag¹, Moutaz M. Kamal Elsharkawy¹, Ahmed Khedewy Ahmed^{2*}

¹Diagnostic Radiology Department, Faculty of Medicine, Al Azhar University, Cairo, Egypt

²Faculty of Medicine, Assiut University, Cairo, Egypt

Email: *ahmedkhedewy@gmail.com

How to cite this paper: Agag, M.F., Elsharkawy, M.M.K. and Ahmed, A.K. (2020) Role of High Resolution Ultrasound in Assessment of Abnormalities of Median Nerve in Carpal Tunnel Syndrome. *Open Journal of Medical Imaging*, 10, 73-88.
<https://doi.org/10.4236/ojmi.2020.102007>

Received: March 12, 2020

Accepted: April 17, 2020

Published: April 20, 2020

Copyright © 2020 by author(s) and Scientific Research Publishing Inc.

This work is licensed under the Creative Commons Attribution International License (CC BY 4.0).

<http://creativecommons.org/licenses/by/4.0/>



Open Access

Abstract

Background: Carpal tunnel syndrome (CTS) is the most common entrapment neuropathy and consists of the compression of the median nerve as it courses through the carpal tunnel. Carpal tunnel syndrome was diagnosed by history and physical examination, electrodiagnostic studies (EDX) were used to confirm the diagnosis. However, these studies are painful for most of the patients with high incidence of false positive or false negative results. Ultrasound is a low cost, short time and non-invasiveness technique that could be used to assess a number of parameters of the median nerve (MN) in cases of CTS. **Objective:** To assess the utility of high resolution ultrasound (HRUS) in assessment of median nerve in carpal tunnel syndrome through different ultrasound diagnostic criteria in patients with clinical and electrodiagnostic evidence of CTS. **Patients and Methods:** This study included a total of 60 participants divided into 2 groups; group A, the patients group included 30 patients with a clinical diagnosis of carpal tunnel syndrome (CTS) and group B, the control group who included 30 sex and age-matched healthy individuals. All the included cases were subjected to full history taking, full general and general examination. Nerve conduction studies were performed using a Caldwell Sierra Wave and the NCS consisted of sensory median nerve conduction tests using standard techniques. High resolution US was performed by using an Aplio 400 Ultrasound System. The following measurement was recorded in each of the included subjects including cross sectional area (CSA) of the median nerve, flattening ratio (FR) of median nerve and palmar bowing (PB) of the flexor retinaculum. **Results:** There was high statistically significant difference in the mean CSA and mean PB between the cases with CTS and healthy control. No statistically significant difference in the mean FR between the cases with CTS and healthy control. Optimal CSA cut-off

value to differentiate between cases with CTS and control was (10.2 mm²) and the optimal PB cut-off value to differentiate between cases with CTS and control was (3.3 mm). Positive correlation was detected between the CSA and PB with increasing the severity of CTS. **Conclusion:** Electrophysiological studies are the most utilized diagnostic methods for diagnosing nerve entrapment including median nerve in CTS. High resolution ultrasound (HRUS) is non-invasive sensitive diagnostic tool in diagnosing CTS.

Keywords

Carpel Tunnel Syndrome, Median Nerve, Ultrasound, Electrodiagnostic Studies

1. Introduction

Carpal tunnel syndrome (CTS) is the most common entrapment neuropathy and consists of the compression of the median nerve as it courses through the carpal tunnel, it is estimated to occur in 2% of the adult population [1].

It is the most prevalent type of peripheral entrapment neuropathy that accounts for about 90% of all entrapment neuropathies [2].

It is defined by American Academy of Orthopedic Surgeons AAOS as a symptomatic compression neuropathy of the median nerve at the level of the wrist characterized physiologically by evidence of increased pressure in the carpal tunnel and decreased function of the nerve at that level (*American Academy of Orthopedic Surgeons*).

Carpal tunnel syndrome was diagnosed by history and physical examination, electrodiagnostic studies (EDX) were used to confirm the diagnosis [3].

Electrodiagnostic studies (EDX) are known to be painful or unpleasant, have false negative and false positive results [4].

The utility of ultrasound in the diagnosis has been reported in a number of studies showing that sensitivity and specificity are approaching that of EDX studies [5].

There are many advantages to ultrasound as low cost, short study time, non-invasiveness, immediacy, and dynamic imaging and can be used to assess a number of parameters of the median nerve (MN) such as size, vascularity (using power Doppler) and mobility (using dynamic imaging), anatomical variations of the median nerve and surrounding structures that may be a causative factor in CTS [6].

Multiple ultrasonography indicators have been applied to the detection of CTS, including cross-sectional area (CSA) of median nerve, retinacular thickness, and flattening ratio of median nerve [7].

Median nerve compression is revealed on high resolution ultrasound (HRUS) by the classic triad of nerve swelling, nerve flattening, and palmar bowing of the flexor retinaculum [8].

The measurement of cross-sectional area (CSA) of the median nerve at the wrist is the most widely used ultrasonography method in CTS diagnosis [9].

Grading the severity of CTS is important for treatment planning and follow-up. Many researchers have classified CTS severity based on the clinical features and electrophysiological findings [9].

The purpose of this study is to assess the utility of high resolution ultrasound (HRUS) in assessment of median nerve in carpal tunnel syndrome through different ultrasound diagnostic criteria in patients with clinical and electrodiagnostic evidence of CTS.

2. Patients and Methods

Study design

This study is a case control one.

Study settings and duration

This study was conducted in radiology department, Al Hussein Hospital, Al Azhar University during the period from November 2019 to December 2019.

Patients

This study included a total of 60 participants into 2 groups; patients group that included 30 patients who were referred to our department from orthopedic, neurology and neurosurgery clinics with a clinical diagnosis of carpal tunnel syndrome (CTS) and confirmed by the nerve conduction studies (NCS) and the control group included 30 individuals selected from volunteer hospital staff who were free of symptoms or clinical signs of neuropathy.

We included patients from both genders who had symptoms, clinical signs and nerve conduction study (NCS) consistent with CTS. The patients with the following conditions were excluded; History of previous wrist surgery, fracture or traumatic nerve injury, patients with history or clinical examination or investigations suggestive of proximal neurologic disorders that might result in numbness or paraesthesia “cervical radiculopathy, Thoracic outlet syndrome, brachial plexopathy, proximal median neuropathy, ulnar neuropathy, polyneuropathy, motor neuron disease spondylotic myelopathy, syringomyelia, stroke, multiple sclerosis” and participants with a variant of median nerve, such as bifid median nerve and persistent median artery were also excluded.

Methodology

All cases were subjected to complete history taking, thorough physical examination, and routine laboratory investigations to rule out systemic diseases causing this condition (e.g. random blood sugar for diabetes, and thyroid function tests for hypothyroidism).

The nerve conduction studies (NCS) were performed using a Caldwell Sierra Wave® (Caldwell Laboratories, Kennewick, WA, USA). The NCS consisted of sensory median nerve conduction tests using standard techniques. The latency, conduction velocity and amplitude of action potential of the median nerve were measured.

The cut-off point used in the NCS was the median nerve distal sensory latency of 3.5 milliseconds and NCS results were considered supportive of CTS when median nerve distal sensory latency was more than 3.5 milliseconds. Wrists with CTS were divided into three groups on the basis of the severity of CTS to mild, moderate, and severe.

High-resolution US was performed by using an Aplio 400 Ultrasound System (Toshiba Medical Systems Corporation, Tokyo, Japan) with a 10 - 12 MHz linear array transducer.

During the examination, the subjects were seated in a comfortable position facing the examiner, with the measured forearm resting on the table, the palm supine, and fingers semi-extended in the neutral position. The full course of the median nerve in the carpal tunnel is evaluated in both the transverse and longitudinal planes. The transducer was placed directly on the patient's skin with gel. The median nerve was first imaged in a longitudinal scan, placing the US probe at the midline between the radius and ulna with the centre of the probe at the distal wrist crease to obtain an initial general overview of the median nerve. The probe was then rotated 90 degrees to obtain optimal axial (cross-sectional) images. A transverse scan was then performed, keeping the probe directly perpendicular to the long axis of the median nerve.

The following measurements were conducted for each of the included subjects; the cross sectional area (CSA) of the median nerve, the elliptical diameters (transverse and antero-posterior) of the median nerve were measured and the flattening ratio (FR) of median nerve and the palmar bowing (PB) of the flexor retinaculum.

- The cross sectional area (CSA) of the median nerve (measured in mm²) at distal crease of the wrist was measured by continual tracing of the nerve circumference outlining the nerve contour using area measurement software (continuous boundary trace) of the ultrasound system.
- The elliptical diameters (transverse and antero-posterior) of the median nerve were measured and the flattening ratio (FR) of median nerve was calculated as the ratio of the nerve's transverse dimension to the anteroposterior dimension.
- The palmar bowing (PB) of the flexor retinaculum is displacement (measured in mm) of the retinaculum from its attachments to the carpal bones and was measured at the trapezium-hamate level. Once the trapezium and hamate bones are identified, a line was drawn tangential to them. Then, the distance between this line and the most anterior portion of the flexor retinaculum was measured.

3. Statistical Analysis

The collected data were coded, processed and analyzed using the SPSS (Statistical Package for Social Sciences) version 22 for Windows® (IBM SPSS Inc, Chicago, IL, USA).

Data were tested for normal distribution using the Shapiro Walk test. Qualitative data were represented as frequencies and relative percentages. Chi-square test (χ^2) was used to calculate difference between qualitative variables as indicated. Quantitative data were expressed as mean \pm SD (Standard deviation). Independent samples t-test was used to compare between two independent groups of normally distributed variables (parametric data) and one way analysis of the variance (ANOVA) was used to compare more than two groups with normally distributed variables (parametric data).

The receiver operating characteristic (ROC) curve was used to find out cut-off points, sensitivity, specificity, positive and negative predictive values. The shape of a ROC curve and the area under the curve (AUC) helps us estimate how high the discriminative power of a test is. For all tests, P values < 0.05 are considered significant.

4. Results

In the patient group, 30 patients (50 wrists) were included in the study. Out of the 30 patients, 20 patients had bilateral CTS and 10 patients had unilateral CTS (right 6, left 4). In the control group, 30 healthy subjects (50 wrists) (**Table 1**).

The mean age ($p = 0.121$) and BMI ($p = 0.523$) didn't reveal statistically significant difference between the two groups ($p = 0.523$). there were females (60%) females and 40% males in the cases group while there were 53.3% females and 46.7% males in the control, with no statistically significant difference between the two groups ($p = 0.822$). The mean BMI also didn't reveal statistically significant difference between the two groups ($p = 0.523$). These data are shown in **Table 2**.

According to the causes of CTS, there were 24 cases (80%) with idiopathic CTS, 4 cases (13.3%) with DM, 1 case (3.3%) with rheumatoid arthritis and 1 case (3.3%) with hypothyroidism. These data are shown in **Table 3**.

According to the severity of CTS, there were 28 wrists (56%) with mild CTS, 10 wrists (20%) with moderate CTS and 12 wrists (24%) with severe CTS. These data are shown in **Table 4**.

Ultrasonographic measurements:

Correlation of the ultrasonographic measurements in CTS patients and control group:

In this study, the mean CSA of the median nerve of the cases in the CTS group was $18.98 \pm 5.66 \text{ mm}^2$ and in the control group was $7.6 \pm 1.32 \text{ mm}^2$ with high statistically significant difference between the two groups ($p < 0.001$). The mean PB of the flexor retinaculum of the cases in the CTS group was $4.31 \pm 0.85 \text{ mm}$ and in the control group was $2.6 \pm 0.62 \text{ mm}$ with high statistically significant difference between the two groups ($p < 0.001$). The mean FR of the median nerve of the cases in the CTS group was 2.89 ± 0.68 and in the control group was 2.76 ± 0.55 with no statistically significant difference between the two groups ($p = 0.243$) (**Table 5**).

Table 1. Distribution of the subjects within the two groups.

Group	Number
Control group	30 (50 wrists)
CTS group (cases group)	30 (50 wrists)
Bilateral	20 (40 wrists)
Unilateral	10 (10 wrists)

Table 2. Analysis of demographic data of the cases in the two study groups.

		Cases group (N = 30)		Control group (N = 30)		P-value
Age		36.20 ± 10.88		31.99 ± 9.71		0.121
Sex	Males	12	40%	14	46.7%	0.822
	Females	18	60%	16	53.3%	
BMI		27.88 ± 2.47		27.38 ± 3.23		0.523

Table 3. Distribution of the cases group according to the causes of CTS.

Causes	Group cases (N = 30)
Idiopathic	24 (80%)
Diabetes mellitus	4 (13.3%)
Rheumatoid arthritis	1 (3.3%)
Hypothyroidism	1 (3.3%)

Table 4. Distribution of the cases group according to severity of CTS.

Severity of CTS	Total number of wrists (50%)
Mild	28 (56%)
Moderate	10 (20%)
Severe	12 (24%)

Table 5. Analysis of Ultrasonographic measurements of CTS patients and controls.

	Cases group (N = 50)	Control group (N = 50)	P-value
CSA (mm ²)	18.98 ± 5.66	7.6 ± 1.32	<0.001*
PB (mm)	4.31 ± 0.85	2.6 ± 0.62	<0.001*
FR	2.89 ± 0.68	2.76 ± 0.55	0.243

CTS: carpal tunnel syndrome; CSA: cross sectional area; FR: flattening ratio; PB: palmar bowing; SD: standard deviation.

The diagnostic accuracy of Ultrasonographic measurements in CTS:

CSA cut-off value of 8 mm² yielded a sensitivity of 96% and specificity of 66%, cut-off value of 9 mm² yielded a sensitivity of 96% and a specificity of 90%, cut-off value of 10 mm² yielded sensitivity of 92% and a specificity of 98% and

cut off value of 11 mm² yielded 97% sensitivity and 100% specificity (Table 6, Figure 1).

PB cut-off value of (3 mm) yielded a sensitivity of 94% and specificity of 80%, cut-off value of (3.2 mm) yielded a sensitivity of 88% and a specificity of 84% and cut-off value of (3.4 mm) yielded sensitivity of 82% and a specificity of 88%. (Table 7, Figure 2).

Optimal cut-off value of CSA and PB for diagnosis of CTS:

Optimal CSA cut-off value was (10.2 mm²) which yielded 98.3% sensitivity, 98.3% specificity, and 98.2% positive predictive value and 93.6% negative predictive value (Table 8).

Optimal PB cut-off value was (3.3 mm) which yielded 94% sensitivity and 89.4% specificity, 95.7% positive predictive value and 93.5% negative predictive value (Table 8).

According to NCS results, 28 wrists out of 50 (56%) were classified as mild CTS. Mean CSA in this group was (17.15 ± 3.58 mm²) and mean PB was (4.29 ± 0.79 mm), 10 out of 50 wrists (20%) were classified as moderate CTS with mean CSA of (20.16 ± 4.42 mm²) and mean PB of (4.32 ± 0.89 mm), Remaining 12 patients (24%) were classified as severe CTS with mean CSA of (27.26 ± 7.37 mm²) and mean PB of (4.35 ± 0.99 mm) (Table 9).

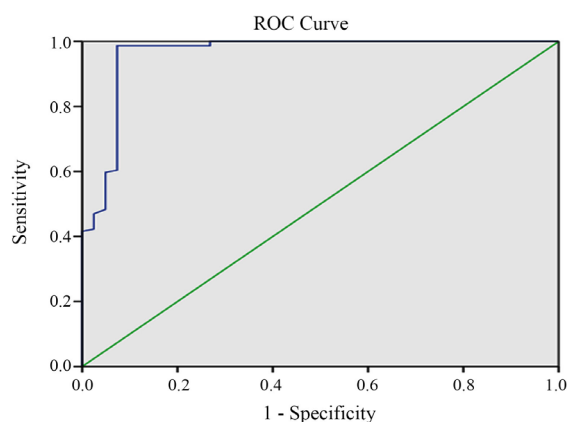


Figure 1. The receiver operating characteristic (ROC) curve for CSA.

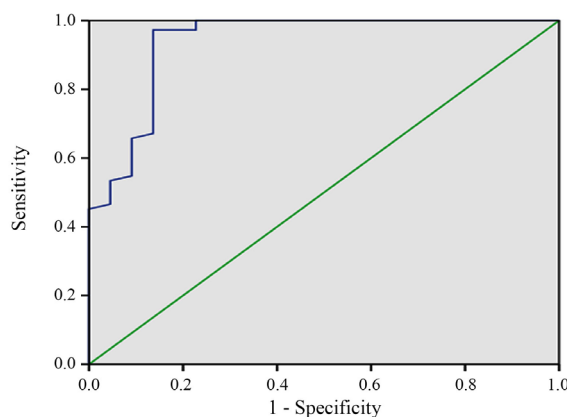


Figure 2. The receiver operating characteristic (ROC) curve for PB.

Table 6. Accuracy of CSA according to different CSA cutoff values.

	Cutoff point (mm ³)			
	8	9	10	11
FP	17	5	1	0
TN	33	45	49	60
TP	48	48	46	41
FN	2	2	4	1
Sensitivity	96%	96%	92%	97%
Specificity	66%	90%	98%	100%
PPV	73%	90%	97%	100%
NPV	94%	95%	92%	98%

FP: False positive; TN: True negative; TP: True positive; FN: False negative; PPV: positive predictive value; NPV: Negative predictive value.

Table 7. Accuracy of PB according to different PB cutoff values.

	Cutoff point (mm)		
	3 mm	3.2 mm	3.4 mm
FP	10	8	6
TN	40	42	44
TP	47	44	41
FN	3	6	9
Sensitivity	94%	88%	82%
Specificity	80%	84%	88%
PPV	82%	84%	87%
NPV	93%	87%	83%

Table 8. Optimal cut off value for CSA and PB.

Cutoff point	CSA	PB
	10.2 mm ²	3.3 mm
AUC	0.935	0.946
Sensitivity	98.3%	94%
Specificity	98.3%	89.4%
PPV	98.2%	95.7%
NPV	93.6%	93.5%
Accuracy	98.7%	95.4%

Table 9. Analysis of Ultrasonographic measurements of CTS according to severity.

	Mild CTS (N = 28)	Moderate CTS (N = 10)	Severe CTS (N = 12)	P-value
CSA (mm²)	17.15 ± 3.58	20.16 ± 4.42	27.26 ± 7.37	<0.001*
PB (mm)	4.29 ± 0.79	4.32 ± 0.89	4.35 ± 0.99	0.063

CTS: carpal tunnel syndrome; CSA: cross sectional area; PB: palmar bowing.

5. Discussion

Carpal tunnel syndrome (CTS) is the most frequent nerve entrapment neuropathy; it occurs secondary to compression of the median nerve under the flexor retinaculum of wrist joint and leads to an enlargement of its cross-sectional area (CSA) just proximal to the site of entrapment [10].

CTS is considered an idiopathic condition, however, characteristic anatomical variations may participate in development of CTS, such as persistent median artery, or a bifid median nerve [11]. It may also result from traumatic injury, inflammatory arthritis such as rheumatoid arthritis, or in association with hypothyroidism, diabetes mellitus, or pregnancy [12].

Early diagnosis is essential to alleviate permanent nerve damage and functional disability. The diagnosis of CTS is usually based on clinical and neurophysiological studies [9].

Electrodiagnostic testing is considered the reference standard for CTS diagnosis with sensitivities of 82% - 94% and specificities of 65% - 97% [13] [14] [15], even though paresthesia may occur before changes can be measured with nerve conduction tests [16].

US is a diagnostic imaging modality is being used more often in daily clinical practice not only to confirm the diagnosis of CTS but also it can detect anatomical variations, nerve shape and space-occupying lesions as tenosynovitis and ganglion cysts [17].

Modern US equipment allows freehand tracing of the circumference of the median nerve proximal to the site of entrapment and calculation of the cross-sectional area (CSA) [18] [19].

Unfortunately, there is no clear cut and generally accepted cutoff value of a single CSA measurement to diagnose CTS as different studies have produced widely variable results with various cutoff threshold for establishing the diagnosis of CTS which appear to be affected by group ethnicity [20] [21] [22] [23].

Klauser *et al.* assessed the CSA of median nerve distally at the region of maximal enlargement, usually just proximal to the carpal tunnel, and proximally at the level of pronator quadratus muscle, thereby using the same nerve as its own control, to improve the precision of CTS diagnosis [24].

The aim of this study was to assess the utility of high resolution ultrasound (HRUS) in assessment of median nerve in carpal tunnel syndrome through different ultrasound diagnostic criteria in patients with clinical and electro diagnostic evidence of CTS.

This study included a total of 60 participants divided into 2 groups; group A, the patients group included 30 patients with a clinical diagnosis of carpal tunnel syndrome (CTS) and confirmed by the nerve conduction studies (NCS) and group B, the control group who included 30 sex and age-matched healthy individuals who were free of symptoms or clinical signs of neuropathy.

There was no statistically significant difference in the basic demographic criteria between the cases with CTS and the control group.

In this study, there were 24 cases (80%) with idiopathic CTS, 4 cases (13.3%) with DM, 1 case (3.3%) with rheumatoid arthritis and 1 case (3.3%) with hypothyroidism.

Although studies had investigated median nerve CSA at the wrist in CTS patients exclusively with diabetes and hypothyroidism, a comparison of different US parameters, especially the CSA, in patients with idiopathic CTS versus those with CTS associated with diabetes and hypothyroidism has not been compared in the same study [25] [26] [27].

In this study, the mean CSA of the median nerve of the cases in the CTS group was $18.98 \pm 5.66 \text{ mm}^2$ and in the control group was $7.6 \pm 1.32 \text{ mm}^2$ with high statistically significant difference between the two groups ($p < 0.001$). The mean PB of the flexor retinaculum of the cases in the CTS group was $4.31 \pm 0.85 \text{ mm}$ and in the control group was $2.6 \pm 0.62 \text{ mm}$ with high statistically significant difference between the two groups ($p < 0.001$). The mean FR of the median nerve of the cases in the CTS group was 2.89 ± 0.68 and in the control group was 2.76 ± 0.55 with no statistically significant difference between the two groups ($p = 0.243$).

This is in accordance with Mohamed *et al.* (2018) who showed that in the healthy control group included in their study, median nerve CSA at the carpal tunnel inlet ranged from 5 to 9 mm^2 with a mean of $7.85 \pm 1.08 \text{ mm}^2$. They also reported that FR and PB were significantly increased in the CTS group than the control group [28].

This came in agreement with Elnady *et al.* (2019) who found a statistically significant difference in the US values of CSA_d, CSA_p, Δ CSA, and mean CSA_dp between CTS patients and healthy controls. Similar results were also reported by Klauser *et al.* (2009).

These data were found to be in concordance with previous data [15] [29] [30].

Regarding PB of flexor retinaculum, the present study revealed that PB of flexor retinaculum significantly increased in the CTS group compared to control group which went in concordance with studies performed by Rayegani *et al.* (2014) and Kandasamy *et al.* (2015).

PB of the flexor retinaculum was attributed to increase the pressure inside the carpal tunnel described in the pathogenesis of CTS [31].

Previous studies attempted to ascertain a universal cutoff value of CSA for the diagnosis of CTS, however until now there was no standard universal cutoff range, being mainly dependent on the ethnicity of the group studied [14] [15] [32] [33] [34] [35].

In previous literature, the suggested values of CSA_d median nerve abnormality varies between 9 to 14 mm^2 [36] [37].

Although discrepancies in the accuracy of sonographic criteria of median nerve entrapment have been reported, CSA with cutoff values of more than 9 or 10 mm^2 at the scapho-pisiform level indicating CTS [15] [38] [39] [40] is still agreed upon as the most reliable and reproducible sonographic criterion indi-

cating CTS [41], with sensitivity of 82% and specificity of 87% (which were almost equal to those of electrodiagnostic values) with a cutoff CSA of more than 12 mm² considered as excellent to diagnose CTS [14].

In this study, Optimal CSA cut-off value to differentiate between CTS cases and control was (10.2 mm²) which yielded 98.3% sensitivity, 98.3% specificity, and 98.2% positive predictive value and 93.6% negative predictive value.

This came in agreement with Elnady *et al.* (2019) who showed that the cutoff value of CSA at the level of carpal tunnel to diagnose CTS in Saudi population was 13 mm² with 90% sensitivity and 95% specificity [17].

Mohamed *et al.* (2018) showed 84% sensitivity and 100% specificity at a 9.5 mm² cut-off value for the mean CSA at the inlet [28].

The study of Kim *et al.* (2014) showed higher sensitivity (88.5%) probably due to the less number of their control (30 vs. 100 wrists in our study) and higher sample size (246 wrists) and showed a higher specificity (90%) probably due to a higher cut-off value (10 mm²) [29].

This also came in accordance with other studies cutoff threshold that ranged between 12 and 13 mm² in CTS as compared with the control [24] [42] [43].

Elnady and his colleagues showed that the mean CSA_{dp} of 9.5 showed sensitivity of 82% and 95% specificity to diagnose CTS, however Δ CSA of 2.5 mm² was associated with 97% sensitivity and 100% specificity, with much higher sensitivity and specificity than using CSA_d and mean CSA_{dp} [17].

In another study, the Δ CSA of 2 mm² or greater was considered diagnostic for CTS with sensitivity of 99% and a specificity of 100% [24].

In this study, PB cut-off value of (3 mm) yielded a sensitivity of 94% and specificity of 80%, cut-off value of (3.2 mm) yielded a sensitivity of 88% and a specificity of 84% and cut-off value of (3.4 mm) yielded sensitivity of 82% and a specificity of 88%.

Sonbol *et al.* (2017) showed that the recorded optimal cut-off value of PB for diagnosis of CTS in current study was 3.3 mm with a sensitivity and specificity of 90% and 85% respectively. Positive and negative predictive values were recorded as 85.7% and 89.5% respectively [31].

In previous studies, PB values have ranged between 2.5 and 4 mm [44].

In our study, there was a statistically significant increase in the CSA of the media nerve with the severity of CTS. There were 28 wrists out of 50 (56%) classified as mild CTS, mean CSA in this group was (17.15 ± 3.58 mm²), 10 out of 50 wrists (20%) were classified as moderate CTS with mean CSA of (20.16 ± 4.42 mm²), the remaining 12 patients (24%) were classified as severe CTS with mean CSA of (27.26 ± 7.37 mm²).

This came in agreement with Elnady *et al.* (2019) who showed that the CSA_d was statistically correlated to the severity of CTS with neurophysiologic assessment, the higher the value the more severe the CTS [17].

The results of this current study were also concordant with other studies [24] [45] [46].

However, Mhoon *et al.* did not find a significant correlation between CSA_d

and electrophysiologic severity assessment [47]. Mover, Elnady *et al.* (2019) and Klauser *et al.* (2009) also stated that Δ CSA is correlated with neurophysiologic CTS severity [17] [24].

US is advantageous in that it is noninvasive, less painful (and therefore more acceptable to patients), more readily available and less expensive. According to our results, US is highly sensitive and specific, so that it may be used as an early tool to assess CTS in patients that may have negative or borderline electrophysiologic studies since negative electrophysiologic studies may occur in up to 30% of CTS patients [48] [49].

Despite the results of this study, there were some limitations such as it is a single center study and the relatively small sample size of the cases included in the study. Also, the design of the study is a case control study which decreases the power of the results.

6. Conclusions

This study revealed that there was Carpel tunnel syndrome (CTS) which is the most prevalent form of nerve entrapment. CTS is common in middle age group with higher risk in females. Idiopathic form is the most common form of CTS followed by endocrinal and metabolic abnormalities mostly diabetes mellitus (DM).

Electrophysiological studies are the most utilized diagnostic methods for diagnosing nerve entrapment including median nerve in CTS. High resolution ultrasound (HRUS) is non-invasive sensitive diagnostic tool in diagnosing CTS. Different parameters measured by HRUS revealed high sensitivity and specificity in diagnosing CTS such as (cross sectional area, palmer bowing and flattening ratio).

Conflicts of Interest

The authors declare no conflicts of interest regarding the publication of this paper.

References

- [1] Klauser, A.S., Buzzegoli, T., Taljanovic, M.S., Strobl, S., Rauch, S., The, J., *et al.* (2018) Nerve Entrapment Syndromes at the Wrist and Elbow by Sonography. In: *Seminars in Musculoskeletal Radiology*, Thieme Medical Publishers, New York. <https://doi.org/10.1055/s-0038-1641577>
- [2] Raeissadat, S.A., Karimzadeh, A., Hashemi, M. and Bagherzadeh, L. (2018) Safety and Efficacy of Platelet-Rich Plasma in Treatment of Carpal Tunnel Syndrome; A Randomized Controlled Trial. *BMC Musculoskeletal Disorders*, **19**, 49. <https://doi.org/10.1186/s12891-018-1963-4>
- [3] Zuniga, L.A. and Ross, M. (2018) T34. Diagnosing Patients with Carpal Tunnel Syndrome: Do You Need Needle EMG? *Clinical Neurophysiology*, **129**, e14. <https://doi.org/10.1016/j.clinph.2018.04.035>
- [4] Roghani, R.S., Hashemi, S.E., Holisaz, M.T., Gohari, F., Delbari, A. and Lökk, J. (2018) The Diagnostic Accuracy of Median Nerve Ultrasonography in Elderly Pa-

- tients with Carpal Tunnel Syndrome: Sensitivity and Specificity Assessment. *Clinical Interventions in Aging*, **13**, 1953. <https://doi.org/10.2147/CIA.S177307>
- [5] McDonagh, C., Alexander, M. and Kane, D. (2015) The Role of Ultrasound in the Diagnosis and Management of Carpal Tunnel Syndrome: A New Paradigm. *Rheumatology*, **54**, 9-19. <https://doi.org/10.1093/rheumatology/keu275>
- [6] Yoshii, Y., Tung, W.L. and Ishii, T. (2017) Strain and Morphological Changes of Median Nerve after Carpal Tunnel Release. *Journal of Ultrasound in Medicine*, **36**, 1153-1159. <https://doi.org/10.7863/ultra.16.06070>
- [7] Yu, G., Chen, Q., Wang, D., Wang, X., Li, Z., Zhao, J., et al. (2016) Diagnosis of Carpal Tunnel Syndrome Assessed Using High-Frequency Ultrasonography: Cross-Section Areas of 8-Site Median Nerve. *Clinical Rheumatology*, **35**, 2557-2564. <https://doi.org/10.1007/s10067-016-3214-0>
- [8] El Miedany, Y. (2015) Musculoskeletal Ultrasonography in Rheumatic Diseases. Springer, Berlin. <https://doi.org/10.1007/978-3-319-15723-8>
- [9] Duncan, S.F., Bhate, O. and Mustaly, H. (2017) Pathophysiology of Carpal Tunnel Syndrome. In: *Carpal Tunnel Syndrome and Related Median Neuropathies*, Springer, Berlin, 13-29. https://doi.org/10.1007/978-3-319-57010-5_3
- [10] Kumari, A., Singh, S., Garg, A., Prakash, A. and Sural, S. (2019) Tingling Hand: Magnetic Resonance Imaging of Median Nerve Pathologies within the Carpal Tunnel. *Polish Journal of Radiology*, **84**, e484-e490. <https://doi.org/10.5114/pjr.2019.90354>
- [11] Georgiev, G.P., Karabinov, V., Matev, B., Iliev, A., Kotov, G. and Landzhov, B. (2017) Carpal Tunnel Syndrome Treatment with Open Surgical Release: A Study in 292 Patients. *Acta Morphologica et Anthropologica*, **24**, 76-81.
- [12] Blood, T.D., Fantry, A.J. and Morrell, N.T. (2019) Chronic Volar Lunate Dislocation Resulting in Carpal Tunnel Syndrome: A Case Report. *UNM Orthopaedic Research Journal*, **8**, 7.
- [13] Wong, S., Griffith, J., Hui, A., Tang, A. and Wong, K. (2002) Discriminatory Sonographic Criteria for the Diagnosis of Carpal Tunnel Syndrome. *Arthritis & Rheumatism: Official Journal of the American College of Rheumatology*, **46**, 1914-1921. <https://doi.org/10.1002/art.10385>
- [14] Ziswiler, H.R., Reichenbach, S., Vögelin, E., Bachmann, L.M., Villiger, P.M. and Jüni, P. (2005) Diagnostic Value of Sonography in Patients with Suspected Carpal Tunnel Syndrome: A Prospective Study. *Arthritis & Rheumatism: Official Journal of the American College of Rheumatology*, **52**, 304-311. <https://doi.org/10.1002/art.20723>
- [15] Yesildag, A., Kutluhan, S., Sengul, N., Koyuncuoglu, H., Oyar, O., Guler, K., et al. (2004) The Role of Ultrasonographic Measurements of the Median Nerve in the Diagnosis of Carpal Tunnel Syndrome. *Clinical Radiology*, **59**, 910-915. <https://doi.org/10.1016/j.crad.2004.03.020>
- [16] Molter, M.W., Mehnert, M.J. and Ilyas, A.M. (2019) Cubital Tunnel Syndrome: Evaluation and Diagnosis. In: *Cubital Tunnel Syndrome*, Springer, Berlin, 29-52. https://doi.org/10.1007/978-3-030-14171-4_3
- [17] Elnady, B., Rageh, E.M., Ekhoully, T., Fathy, S.M., Alshaar, M., Fouda, E.S., et al. (2019) Diagnostic Potential of Ultrasound in Carpal Tunnel Syndrome with Different Etiologies: Correlation of Sonographic Median Nerve Measures with Electrodiagnostic Severity. *BMC Musculoskeletal Disorders*, **20**, 634. <https://doi.org/10.1186/s12891-019-3010-5>
- [18] Donoghue, M.F. (2011) The Variation of Median Nerve Functionality with Wrist

Postures Typical of Computer Use and a Novel Ultrasound Technique for the Diagnosis of Carpal Tunnel Syndrome.

- [19] Langley, A. (2010) Evaluation of the Median Nerve within the Wrist during Functional Hand Activity Using Ultrasonography. University of Nottingham, Nottingham.
- [20] Roll, S.C., Case-Smith, J. and Evans, K.D. (2011) Diagnostic Accuracy of Ultrasonography vs. Electromyography in Carpal Tunnel Syndrome: A Systematic Review of Literature. *Ultrasound in Medicine & Biology*, **37**, 1539-1553. <https://doi.org/10.1016/j.ultrasmedbio.2011.06.011>
- [21] De Kleermaeker, F.G., Meulstee, J. and Verhagen, W.I. (2019) The Controversy of the Normal Values of Ultrasonography in Carpal Tunnel Syndrome: Diagnostic Accuracy of Wrist-Dependent CSA Revisited. *Neurological Sciences*, **40**, 1041-1047. <https://doi.org/10.1007/s10072-019-03756-z>
- [22] Hobson-Webb, L.D., Padua, L. and Martinoli, C. (2012) Ultrasonography in the Diagnosis of Peripheral Nerve Disease. *Expert Opinion on Medical Diagnostics*, **6**, 457-471. <https://doi.org/10.1517/17530059.2012.692904>
- [23] Roll, S.C. (2011) Relationship of Ultrasonographic Physiologic Changes to Personal Factors and Psychosocial Stressors in the Development and Diagnosis of Carpal Tunnel Syndrome. The Ohio State University, Columbus, OH.
- [24] Klauser, A.S., Halpern, E.J., De Zordo, T., Feuchtner, G.M., Arora, R., Gruber, J., *et al.* (2009) Carpal Tunnel Syndrome Assessment with US: Value of Additional Cross-Sectional Area Measurements of the Median Nerve in Patients versus Healthy Volunteers. *Radiology*, **250**, 171-177. <https://doi.org/10.1148/radiol.2501080397>
- [25] Chen, J., Chang, K.-V., Lou, Y.-M., Wu, W.-T. and Özçakar, L. (2019) Can Ultrasound Imaging Be Used for the Diagnosis of Carpal Tunnel Syndrome in Diabetic Patients? A Systemic Review and Network Meta-Analysis. *Journal of Neurology*, **2019**, 1-9. <https://doi.org/10.1007/s00415-019-09254-8>
- [26] Holováčová, D., Kužma, M., Killinger, Z. and Payer, J. (2016) Cross-Sectional Area of the Median Nerve Is Increased in Primary Autoimmune Hypothyroidism and Decreases upon Treatment with Thyroxine. *European Journal of Endocrinology*, **175**, 265-271. <https://doi.org/10.1530/EJE-16-0397>
- [27] Kim, L.-N., Kwon, H.-K., Moon, H.-I., Pyun, S.-B. and Lee, H.-J. (2014) Sonography of the Median Nerve in Carpal Tunnel Syndrome with Diabetic Neuropathy. *American Journal of Physical Medicine & Rehabilitation*, **93**, 897-907. <https://doi.org/10.1097/PHM.0000000000000084>
- [28] Mohamed, F.I., Kamel, S.R. and Hafez, A.E. (2018) Usefulness of Neuromuscular Ultrasound in the Diagnosis of Idiopathic Carpal Tunnel Syndrome. *Egyptian Rheumatology and Rehabilitation*, **45**, 65. https://doi.org/10.4103/err.err_22_17
- [29] Kim, M.-K., Jeon, H.-J., Park, S.-H., Park, D.-S. and Nam, H.-S. (2014) Value of Ultrasonography in the Diagnosis of Carpal Tunnel Syndrome: Correlation with Electrophysiological Abnormalities and Clinical Severity. *Journal of Korean Neurosurgical Society*, **55**, 78. <https://doi.org/10.3340/jkns.2014.55.2.78>
- [30] Keles, I., Kendi, A.T.K., Aydn, G., Zög, S.G. and Orkun, S. (2005) Diagnostic Precision of Ultrasonography in Patients with Carpal Tunnel Syndrome. *American Journal of Physical Medicine & Rehabilitation*, **84**, 443-450. <https://doi.org/10.1097/01.phm.0000163715.11645.96>
- [31] Sonbol, M., Ibrahim, W. and Ghunaimi, M. (2017) Role of Ultrasonography in the Diagnosis of Carpal Tunnel Syndrome. *Al-Azhar Medical Journal*, **46**, 765-780. <https://doi.org/10.12816/0045165>

- [32] Lee, D., van Holsbeeck, M.T., Janevski, P.K., Ganos, D.L., Ditmars, D.M. and Darian, V.B. (1999) Diagnosis of Carpal Tunnel Syndrome: Ultrasound versus Electromyography. *Radiologic Clinics of North America*, **37**, 859-872. [https://doi.org/10.1016/S0033-8389\(05\)70132-9](https://doi.org/10.1016/S0033-8389(05)70132-9)
- [33] Wiesler, E.R., Chloros, G.D., Cartwright, M.S., Smith, B.P., Rushing, J. and Walker, F.O. (2006) The Use of Diagnostic Ultrasound in Carpal Tunnel Syndrome. *The Journal of Hand Surgery*, **31**, 726-732. <https://doi.org/10.1016/j.jhsa.2006.01.020>
- [34] Koyuncuoglu, H.R., Kutluhan, S., Yesildag, A., Oyar, O., Guler, K. and Ozden, A. (2005) The Value of Ultrasonographic Measurement in Carpal Tunnel Syndrome in Patients with Negative Electrodiagnostic Tests. *European Journal of Radiology*, **56**, 365-369. <https://doi.org/10.1016/j.ejrad.2005.05.013>
- [35] Wong, S.M., Griffith, J.F., Hui, A.C., Lo, S.K., Fu, M. and Wong, K.S. (2004) Carpal Tunnel Syndrome: Diagnostic Usefulness of Sonography. *Radiology*, **232**, 93-99. <https://doi.org/10.1148/radiol.2321030071>
- [36] Seror, P. (2008) Sonography and Electrodiagnosis in Carpal Tunnel Syndrome Diagnosis, an Analysis of the Literature. *European Journal of Radiology*, **67**, 146-152. <https://doi.org/10.1016/j.ejrad.2007.06.017>
- [37] Möller, I., Miguel, M., Bong, D., Zaottini, F. and Martinoli, C. (2018) The Peripheral Nerves: Update on Ultrasound and Magnetic Resonance Imaging. *Clinical and Experimental Rheumatology*, **36**, 145-158.
- [38] Sernik, R.A., Abicalaf, C.A., Pimentel, B.F., Braga-Baiak, A., Braga, L. and Cerri, G.G. (2008) Ultrasound Features of Carpal Tunnel Syndrome: A Prospective Case-Control Study. *Skeletal Radiology*, **37**, 49-53. <https://doi.org/10.1007/s00256-007-0372-9>
- [39] Yucel, A., Yilmaz, O., Babaoglu, S., Acar, M. and Degirmenci, B. (2008) Sonographic Findings of the Median Nerve and Prevalence of Carpal Tunnel Syndrome in Patients with Parkinson's Disease. *European Journal of Radiology*, **67**, 546-550. <https://doi.org/10.1016/j.ejrad.2007.08.001>
- [40] Duncan, I., Sullivan, P. and Lomas, F. (1999) Sonography in the Diagnosis of Carpal Tunnel Syndrome. *American Journal of Roentgenology*, **173**, 681-684. <https://doi.org/10.2214/ajr.173.3.10470903>
- [41] Mohammadi, A., Afshar, A., Etemadi, A., Masoudi, S. and Baghizadeh, A. (2010) Diagnostic Value of Cross-Sectional Area of Median Nerve in Grading Severity of Carpal Tunnel Syndrome.
- [42] Tsai, N.-W., Lee, L.-H., Huang, C.-R., Chang, W.-N., Wang, H.-C., Lin, Y.-J., et al. (2013) The Diagnostic Value of Ultrasonography in Carpal Tunnel Syndrome: A Comparison between Diabetic and Non-Diabetic Patients. *BMC Neurology*, **13**, 65. <https://doi.org/10.1186/1471-2377-13-65>
- [43] Lee, C.H., Choi, H., Yoon, J.S. and Kang, S. (2018) Carpal Tunnel Syndrome Assessment with Ultrasonography: A Comparison between Non-Diabetic and Diabetic Patients. *Annals of Rehabilitation Medicine*, **42**, 85. <https://doi.org/10.5535/arm.2018.42.1.85>
- [44] Yurdakul, O.V., Mesci, N., Çetinkaya, Y. and Geler Külçü, D. (2016) Diagnostic Significance of Ultrasonographic Measurements and Median-Ulnar Ratio in Carpal Tunnel Syndrome: Correlation with Nerve Conduction Studies. *Journal of Clinical Neurology*, **12**, 289-294. <https://doi.org/10.3988/jcn.2016.12.3.289>
- [45] Baiee, R., AL-Mukhtar, N., Al-Rubiae, S., Hammoodi, Z. and Abass, F. (2015) Neurophysiological Findings in Patients with Carpal Tunnel Syndrome by Nerve Conduction Study in Comparing with Ultrasound Study. *Journal of Natural Sciences*

Research, **5**, 9.

- [46] Kataruka, M., Pramanik, R., Das, P., Haldar, R., Samanta, S. and Bhakat, D. (2014) The Role of Musculoskeletal US as Diagnostic Tool. *International Journal of Pharmaceutical and Medicinal Research*, **25**, 44-49.
<https://doi.org/10.5005/ijopmr-25-2-44>
- [47] Mhoon, J.T., Juel, V.C. and Hobson-Webb, L.D. (2012) Median Nerve Ultrasound as a Screening Tool in Carpal Tunnel Syndrome: Correlation of Cross-Sectional Area Measures with Electrodiagnostic Abnormality. *Muscle & Nerve*, **46**, 861-870.
<https://doi.org/10.1002/mus.23426>
- [48] Sonoo, M., Menkes, D.L., Bland, J.D. and Burke, D. (2018) Nerve Conduction Studies and EMG in Carpal Tunnel Syndrome: Do They Add Value? *Clinical Neurophysiology Practice*, **3**, 78-88. <https://doi.org/10.1016/j.cnp.2018.02.005>
- [49] Young, A.C. and Wainger, B.J. (2020) Neurological Exam and Neurophysiologic Evaluation for the Pain Patient. *Spine Pain Care*. Springer, Berlin, 115-131.
https://doi.org/10.1007/978-3-030-27447-4_9