

Upper Footprint Dependent Nipple Position to Avoid High-Riding Nipple after Reduction Mammoplasty

Wael H. Mahmoud^{1*}, Wesam I. Homouda², Mohamed H. Elghazaly¹, Mohamed M. Khedr¹

¹Department of Plastic and Reconstructive Surgery, Faculty of Medicine, Tanta University, Tanta, Egypt

²Plastic Surgery Department, Benha Teaching Hospital, Benha, Egypt

Email: *waelhussein558@gmail.com, wesamhomouda@yahoo.com, mohamed.elghazaly@med.tanta.edu.eg, mohamed.khedr@med.tanta.edu.eg

How to cite this paper: Mahmoud, W.H., Homouda, W.I., Elghazaly, M.H. and Khedr, M.M. (2022) Upper Footprint Dependent Nipple Position to Avoid High-Riding Nipple after Reduction Mammoplasty. *Modern Plastic Surgery*, 12, 42-49.
<https://doi.org/10.4236/mps.2022.123004>

Received: May 25, 2022

Accepted: July 3, 2022

Published: July 6, 2022

Copyright © 2022 by author(s) and Scientific Research Publishing Inc. This work is licensed under the Creative Commons Attribution International License (CC BY 4.0).
<http://creativecommons.org/licenses/by/4.0/>



Open Access

Abstract

Introduction: High-riding nipple following reduction mammoplasty is a challenging problem for the plastic surgeons. To avoid such problem, many methods have been described for marking the correct nipple position but still controversial. We aimed in this study to present our experience in preventing excessive nipple elevation after reduction mammoplasty by using the upper footprint to set the new nipple position. **Material and Methods:** From March 2019 to March 2022, 25 female patients at a mean age of 38.3 years were included in this prospective study. They underwent reduction mammoplasty with inverted T scar and a combination of inferior pedicle and Würinger's septum techniques. Resection weights, pre- and postoperative anthropometric measures were recorded. All patients were photographed at the follow-up visits and evaluated for complications if any, the nipple-areola complex (NAC) sensation, and subjective patient satisfaction using "The Breast Evaluation Questionnaire". **Results:** The mean preoperative midclavicular point to nipple distance was 37.40 and 37.18 cm for the right and left breasts, respectively. The mean resection weight was 1270 and 1242 g from the right and left sides, respectively. None of our patients experienced NAC necrosis, while 2 breasts had minor wound dehiscence treated conservatively. After a mean follow-up period of 12 months, the NAC descended by an average of 1.40 cm, the distance from the IMF to nipple had an average increase of 2.24 cm, and all of patients were satisfied with the esthetic outcomes and convinced with their breast shape. **Conclusion:** The upper footprint dependent nipple position seems to have a real role in preventing high-riding nipple after breast reduction in hypertrophic and gigantomastic breasts. Moreover, it can be applied easily and allow for more satisfying outcomes than other methods for setting the new nipple position.

Keywords

High-Riding Nipple, Breast Footprint, Reduction Mammoplasty

1. Introduction

The high-riding nipple (HRN) following mastopexy or breast reduction could be a real problem for the plastic surgeons [1]. In its milder presentations; it causes upturned nipples located above the equator of the breast and above the most projected point. This mild form is often overlooked. Nevertheless, in its more severe forms, it is very embarrassing and disfiguring [2]. The foremost important lesson for its treatment is that prevention is the way easier than the correction. Achieving this goal, the site for new nipple position, requires careful planning during breast reduction surgery to ensure that the nipple-areola complex (NAC) is eventually situated at or near the most projected region of the breast, regardless of the chosen pedicle or skin pattern [3].

However, fixed ideal measurements have inherent limitations as they can vary with factors such as torso width, height and proportions, and the breast footprint [4]. The breast footprint is the outline made by the breast on the chest wall. Importantly, the breast footprint will never change in the same woman either in dimensions or in position after puberty. When the breast enlarges because of weight gain or hormonal influences, the breast will never grow over the midline, the midaxillary line, the inframammary crease, or up to the clavicle [5].

Due to the true potential of NAC displacement, the inframammary fold (IMF) transposition continues to prove to be the most widely used method for selecting new nipple positions [6]; however, this method can be problematic in the setting of gigantomastia or severely ptotic breasts [7]. Instead, Spear and Albino [8] said that the determining factor for the position of the new nipple, should be the upper breast border “upper footprint”, not some arbitrary number from the mid-clavicular point or the suprasternal notch. They found that there was sufficient skin in sufficiently large breasts of at least 8 cm (usually 10 cm) from the upper edge of the breast to the upper edge of the planned new areola window. We aimed in this study to present our experience in preventing excessive nipple elevation after reduction mammoplasty by using the upper footprint to set the new nipple position.

2. Materials and Methods

This prospective study included 25 female patients (50 breasts) who underwent reduction mammoplasty, for breast hypertrophy, by a senior author between March 2019 and March 2022 at Plastic Surgery Department, Tanta University Hospitals. The study was approved by the University Ethical Committee. All patients signed an informed written consent before surgery and medical photography. The inclusion criteria were no previous breast surgeries or diseases and

patients with constant body weights (not more than ± 1000 g) during the course of the study. Those with uncontrolled hypertension, coagulopathies and those with NAC complexes < 30 cm from the midclavicular point were excluded from the study. All cases were operated on with inverted T scar and a combination of inferior pedicle and Würinger's horizontal septum techniques as adopted in our institute. Breast anthropometric measures; midclavicular point to nipple distance and IMF to nipple distance were recorded. The data gathered for statistical analysis were presented as means and standard deviations. The mean age of the patients was 38.32 ± 5.07 (range 33 - 50) years. The mean body mass index BMI was 32.51 ± 2.15 (range 28 - 35) kg/m^2 . Patient data are summarized in (**Table 1**).

2.1. Preoperative Marking

Markings were made preoperatively with the patients in a standing upright position. Breast meridian, midline, IMF, and upper breast border were marked. The neo-NAC position was located on the midclavicular line where the distance between the highest point of the new areola window and the upper breast border was 8 cm (**Figure 1**). The original areola was marked 4 - 5 cm in diameter. The inferior pedicle was marked on the IMF at 8 cm, and all patients were marked according to the inverted T scar pattern.

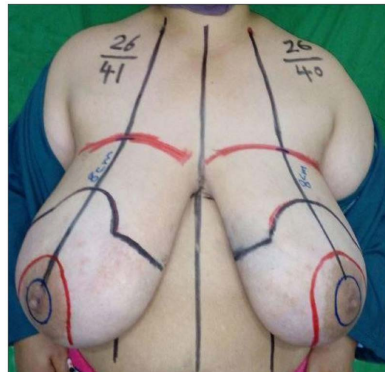


Figure 1. Preoperative marking.

Table 1. Patient data.

No of patients	25 (50 breasts)
Age (years)	38.32 ± 5.07
BMI (kg/m^2)	32.51 ± 2.15
Resection weight (grams) (right-left)	1270 ± 396 1242 ± 430
Complications NAC complications	0% (0 breasts)
Hematoma	0% (0 breasts)
Minor wound dehiscence	4% (2 breasts)
Follow-up (months)	12 ± 3.46

2.2. Surgical Technique

Under general anesthesia, incision lines were infiltrated with 1:1.000.000 adrenaline infiltration. De-epithelialization of the pedicle was done at 1st, and then tissue resection was executed from the medial side down to the muscular fascia to superior direction. After completing medial resection of the breast tissue, the Würinger's horizontal septum could be identified easily at the level of the 5th rib. The breast tissue could be separated easily at this level into its cranial and caudal parts, as it is an avascular plane. The resection was continued in the lateral to superior direction. After that the pedicle was folded and fixed to the pectoral fascia at the 2nd intercostal space with 2/0 non-absorbable sutures superiorly, medially, and laterally. The neo-NAC was placed in the planned area and the arms of the T pattern were approximated with guide sutures. The other side was done in the same manner. Suction drains were placed, and the skin was closed appropriately. Light dressings were used and the standard bra without wire was fitted for 2 months. The drains were removed on the 4th postoperative day and the patients were discharged. The sutures were removed after 10 - 14 days. Follow-up visits were arranged monthly for three months, then every three months for two years. All patients were photographed at the follow-up visits and evaluated for the healing process, complications if any, NAC sensation, the new set of anthropometric measures, and the general appearance of the breast using "The Breast Evaluation Questionnaire" to assess subjective patient satisfaction.

3. Results

Over a 3-year period, fifty hypertrophic breasts were treated by reduction mammoplasty. The mean preoperative midclavicular point to nipple distance was 37.40 ± 3.55 and 37.18 ± 3.36 cm for the right and left breasts, respectively. The mean preoperative IMF to nipple distance was 19.36 ± 2.85 and 19.05 ± 2.60 cm for the right and left sides, respectively. The mean resection weight was 1270 ± 396 and 1242 ± 430 g from the right and left breasts, respectively, with 16 cases having more than 1000 g resection weight per side. None of our patients experienced NAC necrosis, while 2 cases (2 breasts) had minor wound dehiscence at the T junction and they were treated conservatively with good healing.

The mean immediate postoperative midclavicular point to nipple distance was 24.12 ± 2.16 cm and the mean immediate postoperative IMF to nipple distance was 8.58 ± 0.56 cm. After a mean follow-up period of 12 ± 3.46 (range 9 - 18) months, the mean midclavicular point to nipple distance was 25.65 ± 2.05 and 25.38 ± 2.19 cm for the right and left breasts, respectively, and the mean IMF to nipple distance was 10.91 ± 0.52 and 10.73 ± 0.54 cm for the right and left sides, respectively (**Table 2**). According to these measurements, the distance from the IMF to nipple had an average increase of 2.24 cm, and the NAC descended by an average of 1.40 cm. NAC sensation was maintained in all of our patients. None of our cases complained about their breast final shape and all of them were satisfied with the esthetic outcomes (**Figure 2** and **Figure 3**).

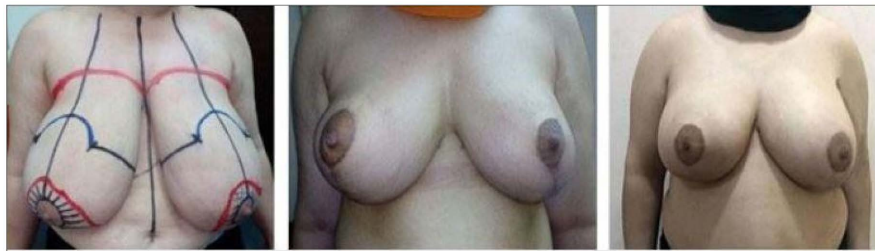

Figure 2. Preoperative, 1 month postoperative and 1 year postoperative pictures showing good esthetic outcomes with the nipples at the point of highest projection.

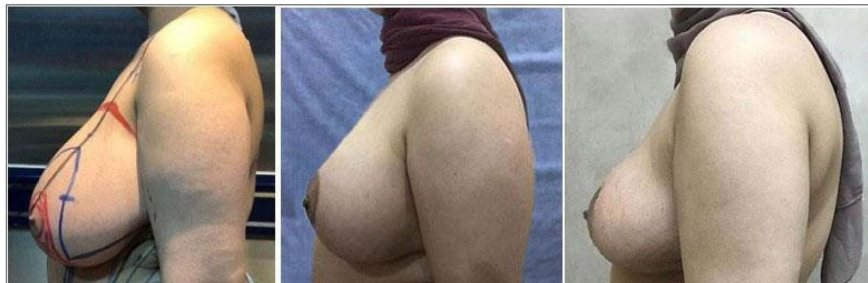

Figure 3. Preoperative, 1 month postoperative and 1 year postoperative pictures (lateral view) showing good esthetic outcomes with the nipples at the point of highest projection.

Table 2. Preoperative and postoperative measurements.

	Right	Left
Preoperative midclavicular - nipple distance (cm)	37.40 ± 3.55	37.18 ± 3.36
Preoperative IMF - nipple distance (cm)	19.36 ± 2.85	19.05 ± 2.60
Postoperative midclavicular - nipple distance (cm)		
Immediate	24.12 ± 2.16	24.12 ± 2.16
Late	25.65 ± 2.05	25.38 ± 2.19
Postoperative IMF - nipple distance (cm)		
Immediate	8.58 ± 0.56	8.58 ± 0.56
Late	10.91 ± 0.52	10.73 ± 0.54

4. Discussion

The power of femininity is reflected in the beauty of the breasts. The nipple-areola complex is the most functional and esthetic part of the breast [5]. Breast reduction is routinely designed to reduce excess glandular tissue, reposition the NAC, remodel the mammary complex and resect excess skin with different incisions and scars [9] but often may result in too high nipple position that, appears elevated more than the anticipated in the preoperative design, gives the breasts a grotesque appearance and can only be treated through complicated surgical techniques [8]. To avoid such problem, it is critical to properly mark the nipple position taking into consideration the cranialization of the NAC post-operatively [4].

Due to personal differences in physical features, nipple position based on ideal suprasternal notch-to-nipple distance (18 - 23 cm) is only meaningful for orientation, but the predictable site of nipples must in any case be determined by individual measurements [10]. There are several ways for marking the new nipple position. The finger test is commonly used in which the 4 fingers are placed behind the breast in the IMF, and the middle finger opposite to the thumb, shows the expected position of the nipple. Lassus [6] placed the upper edge of the areola 2 cm below the midway between the acromion and olecranon in the standing position. Hall-Findlay [11] put a measuring tape under the breast and marked the level of the IMF on the midline of the chest. 2 cm below this point marks the new nipple position. Akyurek marked the new nipple position at a point below the IMF by the amount of upper pole descent [12]. In this study, we aimed to present our experience in preventing high-riding nipple after reduction mammoplasty by using the upper footprint to set the new nipple position. We marked the upper edge of the neo-NAC on the breast meridian at 8 cm below the upper breast border, with the new nipple position 2 - 2.5 cm below the superior border of the areola.

In the present study, we preferred to use a combination of inferior pedicle and Würinger's horizontal septum technique with the inverted T scar pattern as adopted in our institute for large-volume reduction mammoplasty patients. The inferior pedicle method is still the most popular reduction mammoplasty technique used today that is safe, can be applied easily, has a short learning curve, and preserves sensitivity and vascularity of the NAC. Although the inferior pedicle is safe, poor circulation of the NAC may occur due to long pedicle in large-volume breast reductions. Accordingly, preserving Würinger's horizontal septum with the pedicle provides two vascular systems, increase the chance of NAC viability and warrant resection of large amount of tissue to relieve the patients' symptoms. In our study, the mean resection weight was 1270 ± 396 and 1242 ± 430 g from the right and left breasts, respectively, and none of our cases had NAC necrosis, while 2 breasts (4%) had minor wound dehiscence. In a similar study, Kelahmetoglu *et al.* [13] used Würinger's septum and inferior pedicle techniques for 120 breast reductions. The mean resection weight was 1406 ± 566 and 1340 ± 563 g from the right and left sides, respectively. They encountered no cases of total NAC necrosis, 1 case of partial NAC necrosis and 5 cases (8.3%) of venous insufficiency. They concluded that the combined method promote more satisfying and safer results than the inferior pedicle method alone. In another study, Portincasa *et al.* [14] compared the inferocentral pedicle including Würinger's septum with the inferior pedicle technique and reported significant decrease in the incidence of the NAC complications in the inferocentral pedicle technique.

In our study, the pedicle was suspended to the pectoral fascia with non-absorbable sutures in order to prevent the bottoming out which is a common drawback of the inferior pedicle technique. We noticed that after a mean follow up of 12 months, none of our patients complained of this deformity and

all of them were pleased about their breast shape. Pennington [15] performed pedicle suspension and plication to prevent bottoming out in 500 cases and reported that all patients were satisfied with their breasts and none of them complained from pseudoptosis or bottoming out. Nevertheless, it is not always possible to prevent bottoming out over long periods of time due to breast parenchyma natural descent by the effect of gravity.

In the current study, we used the upper footprint to set the new nipple position. We found that after an a mean of 1 year follow up, the NAC descended by an average of 1.40 cm, the distance from the IMF to nipple had an average increase of 2.24 cm, and all of patients were satisfied with the esthetic outcomes and convinced with their breast shape. In another study, Altuntas *et al.* [3] used the finger test to mark the nipple position on the IMF. They observed that the NAC descended by an average of 1.7 cm and the IMF to nipple had an average increase of 3.45 cm, leading to apparent superior nipple displacement of $(3.45 - 1.7 = 1.75 \text{ cm})$. They recommended that the new nipple position ought to be marked at 1.5 to 1.75 cm below the point of maximal projection of the breast intraoperatively. Gulyás [10] used the method of breast parenchyma dynamic imbrication to reveal the most projected area on the breast meridian, indicating the new nipple position. They reported this method is only applicable for small to medium reductions, while for large-volume reductions should be controlled with the methods using fixed anatomical reference points such as the IMF or the upper breast border. Finally, this study was limited by the relatively few number of cases and the short term follow up. Considerably, further studies on a larger number of cases with longer follow-up periods are therefore recommended for better assessment of this technique.

5. Conclusion

In conclusion, upper footprint dependent nipple position seems to have a real role in preventing high-riding nipple after breast reduction in hypertrophic and gigantomastic breasts. Moreover, it can be applied easily and allow for more satisfying outcomes than other methods for setting the new nipple position.

Conflicts of Interest

This article is original not submitted or accepted for publication elsewhere; there is no conflict of interests.

References

- [1] Colwell, A.S., May Jr., J.W. and Slavin, S.A. (2007) Lowering the Postoperative High-Riding Nipple. *Plastic and Reconstructive Surgery*, **120**, 596-599. <https://doi.org/10.1097/01.prs.0000270283.64971.dd>
- [2] Frenkiel, B.A., Pacifico, M.D., Ritz, M. and Southwick, G. (2010) A Solution to the High-Riding Nipple-Areola Complex. *Aesthetic Plastic Surgery*, **34**, 525-527. <https://doi.org/10.1007/s00266-009-9421-1>
- [3] Altuntaş, Z.K., Kamburoğlu, H.O., Yavuz, N., Dadacı, M. and İnce, B. (2015)

- Long-Term Changes in Nipple-Areolar Complex Position and Inferior Pole Length in Superomedial Pedicle Inverted “t” Scar Reduction Mammoplasty. *Aesthetic Plastic Surgery*, **39**, 325-330. <https://doi.org/10.1007/s00266-015-0470-3>
- [4] Lewin, R., Widmark-Jensen, E., Plate, N. and Hansson, E. (2018) Objective Evaluation of Nipple Position after 336 Breast Reductions. *Journal of Plastic Surgery and Hand Surgery*, **52**, 198-203. <https://doi.org/10.1080/2000656X.2017.1419142>
- [5] Blondeel, P.N., Hijjawi, J., Depypere, H., Roche, N. and Van Landuyt, K. (2009) Shaping the Breast in Aesthetic and Reconstructive Breast Surgery: An Easy Three-Step Principle. *Plastic and Reconstructive Surgery*, **123**, 455-462. <https://doi.org/10.1097/PRS.0b013e3181954cc1>
- [6] Lassus, C. and Hidalgo, D.A. (1999) Update on Vertical Mammoplasty. *Plastic and Reconstructive Surgery*, **104**, 2303-2304. <https://doi.org/10.1097/00006534-199912000-00062>
- [7] Ahmad, J. and Lista, F. (2008) Vertical Scar Reduction Mammoplasty: The Fate of Nipple-Areola Complex Position and Inferior Pole Length. *Plastic and Reconstructive Surgery*, **121**, 1084-1091. <https://doi.org/10.1097/01.prs.0000302453.26842.5d>
- [8] Spear, S.L. and Albino, F.P. (2016) Management of the High-Riding Nipple after Breast Reduction. *Clinics in Plastic Surgery*, **43**, 395-401. <https://doi.org/10.1016/j.cps.2015.12.008>
- [9] Souza, A.A., Faiwichow, L., Ferreira, Á.D.A., Simão, T.S., Pitol, D.N. and Máximo, F.R. (2011) Comparative Analysis of Mammoplasty Techniques Based on the Long-Term Effect on the Nipple-Areolar-Complex to Inframammary Crease Distance. *Revista Brasileira de Cirurgia Plástica*, **26**, 664-669. <https://doi.org/10.1590/S1983-51752011000400022>
- [10] Gulyás, G. (2004) Marking the Position of the Nipple-Areola Complex for Mastopexy and Breast Reduction Surgery. *Plastic and Reconstructive Surgery*, **113**, 2085-2090. <https://doi.org/10.1097/01.PRS.0000122404.10073.55>
- [11] Hall-Findlay, E.J. (2004) Vertical Breast Reduction. *Seminars in Plastic Surgery*, **18**, 211-224. <https://doi.org/10.1055/s-2004-831908>
- [12] Akyurek, M. (2011) Contouring the Inferior Pole of the Breast in Vertical Mammoplasty: Suction-Assisted Lipectomy versus Direct Defatting. *Plastic and Reconstructive Surgery*, **127**, 1314-1322. <https://doi.org/10.1097/PRS.0b013e318205f441>
- [13] Kelahmetoglu, O., Firinciogullari, R., Yagmur, C., Yildiz, K. and Guneren, E. (2017) Combination of Würinger’s Horizontal Septum and Inferior Pedicle Techniques to Increase Nipple-Areolar Complex Viability during Breast Reduction Surgery. *Aesthetic Plastic Surgery*, **41**, 1311-1317. <https://doi.org/10.1007/s00266-017-0933-9>
- [14] Portincasa, A., Ciancio, F., Cagiano, L., Innocenti, A. and Parisi, D. (2017) Septum-Enhanced Mammoplasty in Inferocentral Pedicled Breast Reduction for Macromastia and Gigantomastia Patients. *Aesthetic Plastic Surgery*, **41**, 1037-1044. <https://doi.org/10.1007/s00266-017-0868-1>
- [15] Pennington, D.G. (2006) Improving the Results of Inferior Pedicle Breast Reduction Using Pedicle Suspension and Plication. *Aesthetic Plastic Surgery*, **30**, 390-394. <https://doi.org/10.1007/s00266-006-0040-9>